



# WSAVA guidelines for the control of reproduction in dogs and cats

## AUTHORS:

S. ROMAGNOLI<sup>\*,1</sup>, N. KREKELER<sup>†</sup>, K. DE CRAMER<sup>‡</sup>, M. KUTZLER<sup>§</sup>, R. MCCARTHY<sup>¶</sup> AND S. SCHAEFER-SOMI<sup>\*\*</sup>

<sup>\*</sup>Department of Animal Medicine, Production and Health, Viale dell'Università 16, University of Padova, Legnaro, 35020, Italy

<sup>†</sup>Department of Biomedical Sciences, Melbourne Veterinary School, Faculty of Science, Melbourne, VIC, Australia

<sup>‡</sup>Department of Production Animals, Faculty of Veterinary Science, University of Pretoria, Onderstepoort, Pretoria, South Africa

<sup>§</sup>Dept of Animal and Rangeland Sciences, Oregon State University, 112 Withycombe Hall, Corvallis, OR 97331, USA

<sup>¶</sup>Department of Veterinary Clinical Sciences, Cummings School of Veterinary Medicine, Tufts University, North Grafton, MA 01536, United States

<sup>\*\*</sup>Center for Reproduction, Vetmeduni Vienna, Veterinärplatz 1, Vienna, 1210, Austria

<sup>1</sup>Corresponding author email: [stefano.romagnoli@unipd.it](mailto:stefano.romagnoli@unipd.it)

## Table of contents

1. Introduction	5
1.1. Use of this document	6
2. Surgical sterilisation in dogs and cats	7
2.1. Surgical methods of sterilisation in dogs and cats associated with loss of gonadal hormones	7
2.1.1. Female dogs	7
2.1.1.1. Ovariectomy, subtotal ovariectomy and ovariectomy	7
2.1.1.1.1. Ventral midline laparotomy for ovariectomy in dogs	9
2.1.1.1.2. Ventral midline laparotomy for subtotal ovariectomy in dogs	14
2.1.1.1.3. Ventral midline laparotomy for ovariectomy in dogs	14
2.1.1.1.4. Flank laparotomy for ovariectomy and subtotal ovariectomy in dogs	17
2.1.1.1.5. Laparoscopic ovariectomy, subtotal ovariectomy and ovariectomy in dogs	17
2.1.1.1.6. Ventral midline laparotomy for surgical sterilization of the periparturient female dog	21
2.1.1.1.6.1. Hysterotomy and concurrent subtotal ovariectomy	22
2.1.1.1.6.2. En-bloc subtotal ovariectomy	25
2.1.1.1.7. Prevention and treatment of complications associated with ovariectomy, subtotal ovariectomy and ovariectomy.	26
2.1.2. Female cats	30
2.1.2.1. Ovariectomy, subtotal ovariectomy and ovariectomy	30
2.1.2.1.1. Ventral midline laparotomy for ovariectomy in cats	31
2.1.2.1.2. Ventral midline laparotomy for subtotal ovariectomy and ovariectomy in cats	33
2.1.2.1.3. Flank laparotomy for ovariectomy and subtotal ovariectomy in cats	33
2.1.2.1.4. Laparoscopic ovariectomy, subtotal ovariectomy and ovariectomy in cats	33
2.1.3. Male dogs	33
2.1.3.1. Orchiectomy in dogs with descended testes	33
2.1.3.1.1. Prescrotal orchiectomy in dogs	33

2.1.3.1.2.	Prevention and treatment of complications associated with prescrotal orchiectomy in dogs	37
2.1.3.1.3.	Scrotal orchiectomy in dogs	37
2.1.3.1.4.	Orchiectomy in dogs with scrotal ablation	37
2.1.3.2.	Orchiectomy in dogs with cryptorchid testes	37
2.1.3.2.1.	Cryptorchidectomy of an extra-inguinal testis	40
2.1.3.2.2.	Cryptorchidectomy of an inguinal testis	40
2.1.3.2.3.	Ventral midline laparotomy for cryptorchidectomy of an intra-abdominal testis	40
2.1.3.2.4.	Laparoscopic cryptorchidectomy in dogs	41
2.1.4.	Male cats	41
2.1.4.1.	Orchiectomy in cats with descended testes	41
2.1.4.1.1.	Scrotal orchiectomy in cats	41
2.1.4.2.	Orchiectomy in cats with cryptorchid testes	43
2.1.4.2.1.	Cryptorchidectomy of an extra-inguinal testis	43
2.1.4.2.2.	Cryptorchidectomy of an inguinal testis	43
2.1.4.2.3.	Ventral midline laparotomy for cryptorchidectomy of an intra-abdominal testis	45
2.2.	Surgical sterilisation of dogs and cats with preservation of gonadal hormones	45
2.2.1.	Female dogs	45
2.2.1.1.	Hysterectomy	45
2.2.1.1.1.	Ventral midline laparotomy for hysterectomy in dogs	46
2.2.1.1.2.	Flank laparotomy for hysterectomy in dogs	48
2.2.1.1.3.	Laparoscopic hysterectomy in dogs	48
2.2.1.2.	Salpingectomy	48
2.2.1.3.	Ovarian tissue implant	50
2.2.2.	Female cats	51
2.2.2.1.	Hysterectomy	51
2.2.2.1.1.	Ventral midline laparotomy for hysterectomy in cats	51
2.2.3.	Male dogs	51
2.2.3.1.	Vasectomy	51
2.2.3.1.1.	Prescrotal vasectomy in dogs	52
2.2.3.1.2.	Laparoscopic vasectomy in dogs	52
2.2.4.	Male cats	54
2.2.4.1.	Vasectomy	54
2.2.4.1.1.	Bilateral inguinal vasectomy in cats	54
2.2.4.1.2.	Prescrotal vasectomy in cats	54
2.2.4.1.3.	Ventral midline laparotomy for vasectomy in cats	55
2.2.4.1.4.	Laparoscopic vasectomy in male cats	55
2.2.4.2.	Epididymectomy in male cats	55
2.3.	Antimicrobial use for surgical sterilisation	55
2.4.	Surgical sterilisation and pain control	59
3.	Non-surgical sterilisation in dogs and cats	59
3.1.	Hormonal downregulation	59
3.1.1.	GnRH agonists and antagonists	59
3.1.1.1.	GnRH agonist: Deslorelin	60
3.1.1.1.1.	Male dogs	60
3.1.1.1.2.	Female dogs	60
3.1.1.1.3.	Male cats	61
3.1.1.1.4.	Female cats	61
3.1.1.2.	GnRH antagonists: acyline and antide	61
3.1.1.2.1.	Female dogs	61
3.1.1.2.2.	Cats	61
3.1.2.	Progestogens	62
3.1.2.1.	Megestrol acetate	62
3.1.2.1.1.	Female dogs	62
3.1.2.1.2.	Female cats	62
3.1.2.1.3.	Male dogs	62



3.1.2.2.	Medroxyprogesterone acetate	63
3.1.2.2.1.	Female dogs	63
3.1.2.2.2.	Female cats	63
3.1.2.2.3.	Male dogs	63
3.1.3.	Androgens	63
3.1.3.1.	Mibolerone	63
3.1.3.1.1.	Female dogs	63
3.1.3.1.2.	Female cats	64
3.1.3.2.	Other androgens	64
3.1.4.	Melatonin	64
3.1.4.1.	Female cats	64
3.1.4.2.	Male cats	64
3.2.	Immunocontraceptives	64
3.2.1.	Immunisation against gonadotropin-releasing hormone	64
3.2.1.1.	GnRH-conjugated to keyhole limpet haemocyanin	65
3.2.1.1.1.	Male dogs	65
3.2.1.1.2.	Female dogs	65
3.2.1.1.3.	Male cats	65
3.2.1.1.4.	Female cats	65
3.2.1.2.	GnRH-conjugated to diphtheria toxin	65
3.2.2.	Immunisation against zona pellucida	65
3.2.2.1.	Female dogs	66
3.2.2.2.	Female cats	66
3.2.3.	Immunisation against GnRH and ZP	66
3.3.	Chemical castration	66
3.3.1.	Intratesticular injection	66
3.3.1.1.	Calcium chloride	66
3.3.1.1.1.	Male dogs	66
3.3.1.1.2.	Male cats	67
3.3.1.2.	Zinc gluconate	67
3.3.1.2.1.	Male dogs	68
3.3.1.2.2.	Male cats	68
3.3.1.3.	Glycerol	68
3.3.1.3.1.	Male dogs	68
3.3.1.3.2.	Male cats	68
3.3.2.	Intra-epididymal injections	68
3.3.2.1.	Male dogs	68
3.3.2.2.	Male cats	69
3.4.	Mechanical methods	69
3.4.1.	Intrauterine devices	69
3.4.2.	Therapeutic ultrasonography	69
3.5.	Gene therapy	69
3.5.1.	Gene silencing	69
3.5.2.	Gene overexpression	70
4.	Health benefits of sterilisation with loss of gonadal steroid hormones	70
4.1.	Female dogs	70
4.1.1.	Reproductive tract diseases	70
4.1.1.1.	Ovarian diseases	70
4.1.1.2.	Uterine diseases and unwanted pregnancies	72
4.1.1.3.	Reproductive tubular tract neoplasia	72
4.1.1.4.	Mammary tumours	73
4.1.1.5.	Transmissible venereal tumour	75
4.1.1.6.	Vaginal hyperplasia and vaginal prolapse	76
4.1.1.7.	Disorders of sexual development	77
4.1.2.	Progestogen dependent diabetes mellitus	77
4.1.3.	Behavioural issues	78

4.1.4.	Life expectancy	78
4.2.	Male dogs	81
4.2.1.	Reproductive tract diseases	81
4.2.1.1.	Testicular diseases	81
4.2.1.2.	Prostate gland diseases	82
4.2.1.2.1.	Benign prostatic hyperplasia	82
4.2.1.2.2.	Prostatitis	83
4.2.1.2.3.	Prostatic neoplasia	84
4.2.2.	Perianal gland tumours	84
4.2.3.	Transmissible venereal tumour.	84
4.2.4.	Urethral prolapse	85
4.2.5.	Perineal hernia	86
4.2.6.	Behavioural concerns	86
4.2.7.	Life expectancy	88
4.3.	Cats	88
4.3.1.	Reproductive tract diseases	88
4.3.1.1.	Inflammatory mammary diseases in female cats	90
4.3.1.2.	Proliferative diseases of the mammary gland in cats	90
4.3.1.2.1.	Mammary fibroadenomatosis in cats	90
4.3.1.2.2.	Mammary tumours	91
4.3.2.	Infections and diseases of the immune system	92
4.3.3.	Behavioural issues	92
4.3.4.	Life expectancy	92
5.	Health detriments of sterilisation with loss of reproductive hormones	92
5.1.	Female dogs	93
5.1.1.	Tumours	93
5.1.1.1.	Mast cell tumours	93
5.1.1.2.	Transitional cell carcinomas	94
5.1.1.3.	Osteosarcoma	94
5.1.1.4.	Lymphomas	95
5.1.1.5.	Haemangiosarcomas	96
5.1.2.	Urethral sphincter mechanism incompetence	96
5.1.3.	Orthopaedic diseases	98
5.1.4.	Metabolic and endocrine disorders	99
5.1.5.	Immune disorders	100
5.1.6.	Behavioural concerns	101
5.1.7.	Paediatric gonadectomy	102
5.2.	Male dogs	102
5.2.1.	Tumours	102
5.2.1.1.	Prostate gland tumours	102
5.2.1.2.	Mast cell tumours	105
5.2.1.3.	Transitional cell carcinomas	105
5.2.1.4.	Osteosarcomas	105
5.2.1.5.	Lymphomas	105
5.2.1.6.	Haemangiosarcomas	105
5.2.2.	Urethral sphincter mechanism incompetence (USMI)	106
5.2.3.	Orthopaedic diseases	106
5.2.4.	Metabolic and endocrine disorders	107
5.2.5.	Immune disorders	107
5.2.6.	Behavioural concerns	108
5.2.7.	Paediatric gonadectomy	109
5.3.	Cats	109
5.3.1.	Effects on metabolism	109
5.3.2.	Orthopaedic diseases	110
5.3.3.	Tumours	110
5.3.4.	Lower urinary tract diseases	110

5.3.5. Paediatric gonadectomy	110
6. Ethics of Reproduction Control in dogs and cats	111
6.1. Introduction	111
6.2. Overpopulation and shelter intake	111
6.3. Trap, neuter, return programmes	111
6.4. Responsible pet ownership	112
6.5. Variation of spaying and neutering rates	113
6.6. Early age spaying and neutering	113
6.7. Ethical implications of sterilisation of dogs and cats	113
6.8. Mandatory spay and neuter laws	114
6.9. Recommendations on reproduction control of dogs and cats in different settings	114
6.10. Position of Reproduction Control Committee on prosthetic testicular implants	117
7. References	118

## 1 | INTRODUCTION

During the second half of the last century, dogs and cats have gained an important place in many households and their numbers have increased remarkably in many countries. While there are anecdotal estimates of pet ownership by country provided on websites and in the lay literature, there is a lack of peer-reviewed data on the actual world population of dogs and cats, both owned and unowned. These animals may easily reproduce once they achieve puberty if not constantly under control. Therefore, veterinarians are continuously presented with requests to contain or eliminate reproductive behaviour or fertility as a whole in owned dogs and cats.

The increased presence of small animals in our homes has been paralleled by an increase in dog and cat populations in suburban areas where free-roaming stray or unsupervised animals reproduce uncontrolled, causing public health concerns. Animal shelters in many areas are overcrowded by dogs and cats. Proactive rehoming, adoption and sterilisation policies are being promoted in many parts of the world. However, shelter populations seem to have remained stable and have, despite all these efforts, increased in some countries/areas/municipalities (Crawford et al., 2019). Therefore, controlling dog and cat reproduction has always been a key issue for veterinarians working in animal welfare organisations and for small animal practitioners alike.

The historical approach to controlling dog and cat reproduction has been through surgical gonadectomy. For males, multiple surgical methods, approaches and means of haemostasis have been utilised with success and precise technique is generally based on surgeon experience and preference. For females, removal of all (ovariohysterectomy, OHE) or part (subtotal ovariohysterectomy; SOHE) of the uterus may be performed concomitantly with removal of the gonads. While many veterinary textbooks describe the OHE procedure with ligatures placed and subsequent transection made at the level of the uterine body, it is important to recognise that this is both anatomically and physiologically incorrect. Some portion of the uterus will inevitably remain in the patient and therefore what is being performed, is a SOHE (Mejia et al., 2020). SOHE should be avoided as it exposes the female to the risk of developing a uterine stump condition should an ovarian remnant be present, or a progestogen treatment administered at a later date. Ovariectomy (OE) alone is quicker, uses a smaller incision and is associated with less potential complications (Okkens et al., 1997). Consequently, in the absence of uterine pathology, and if lack of gonadal hormones is both predicted and desired, these guidelines recommend OE as the preferred surgical procedure for sterilisation of female dogs and cats.

Laparoscopic sterilisation is less painful and provides better visualisation of all pertinent structures, especially in small breed dogs. Owner familiarity with minimally invasive surgery in humans is producing a large demand for its use in pets (Buote, 2022). Surgical sterilisation techniques that maintain gonadal hormones such as vasectomy and hysterectomy have also been proposed as effective and safe means of inhibiting reproduction in pets (Kutzler, 2020b; McCarthy, 2019; Zink et al., 2023).

Alternatives to the surgical removal of gonads for dogs and cats have existed since the second half of last century. The first drugs commercially available for the control of reproduction in small animals were synthetic analogues of progesterone (progestogens) that block the action of the hypothalamic–pituitary–gonadal (HPG) axis. Unfortunately, improper use in dogs and cats has led to several case reports of side effects from overdosing (Romagnoli & Ferre-Dolcet, 2022; Romagnoli & Lopate, 2017). After careful patient selection, progestogen use at the appropriate dose and duration can be a safe and effective method for reproduction control.

Earlier this century a new category of active principles, long-acting preparations of gonadotropin-releasing hormone (GnRH) agonists became available as veterinary drugs in some countries allowing for prolonged duration of reproduction control (Fontaine & Fontbonne, 2011; Goericke-Pesch et al., 2013; Romagnoli et al., 2009; Trigg et al., 2006). The effect of a single administration of a long-acting GnRH agonist implant varies from 6 to 12 months (depending on dosage) in dogs and is much longer in cats. Repeated administration is effective and appears to be safe based on the limited data available (Brändli et al., 2021; Romagnoli et al., 2023).

Therefore, its use in bitches for which surgery is not an option may be considered. Long-acting GnRH agonists are approved in some countries for use in male dogs and cats and in prepubertal bitches; their off-label use is proving effective and safe in queens while more data is needed to warrant its use in postpubertal bitches. Male dogs and cats may also be rendered sterile by local administration of chemical agents (Oliveira et al., 2013). Approaches such as vaccination against GnRH or, more recently, gene therapy causing overexpression of Mullerian inhibiting substance are promising, particularly for females (Levy et al., 2005, 2011; Ochoa et al., 2023; Vansandt et al., 2023; Vargas-Pino et al., 2013). The remarkable extent of current knowledge on this topic makes it increasingly challenging for veterinarians to advise clients and stakeholders on the best approach to reproduction control for small animals. This is particularly true for small animal practitioners given the emotional value clients usually place on pets. Reproduction control as a presenting request has gone from the very simple “*I would like my pet to be spayed/neutered*” to a very elaborate set of questions the most intriguing of which are “*how and at what age should it be done*” and more recently and importantly “*should we do it or not*”? As a consequence of the more important role dogs and cats are playing in our lives, shelter conditions have also been receiving increased attention from the public and social media. Once in a shelter, rescued or captured animals are invariably gonadectomised, a practice which continues around the world using a standard surgical approach. Reproduction of shelter animals needs to be blocked permanently as this prevents further reproduction and increases their chances of being adopted. Therefore, surgical sterilization remains a valid solution in certain situations because of its ease and cost-effectiveness. However, evidence is accumulating in favour of the efficacy of newer surgical techniques which, in spite of maintaining reproductive behaviour, may offer the option of adopting healthier animals.

Small animal practitioners need to acquaint themselves with current knowledge regarding reproductive control offering a host of novel approaches replacing the potentially harmful practice of routine gonadectomy of young dogs and cats. The best options for reproduction control in dogs and cats are the ones that have the least long-term health concerns which may be more pronounced particularly in large and giant breed dogs (Benka et al., 2023). For owned pets, such a decision should be made on a case-by-case basis in consultation with the owner with due consideration of species, sex, breed, purpose and lifestyle of the pet as well as financial constraints. Albeit less ideal for the individual pet, methods for reproduction control in the shelter environment may differ to that of owned animals. Effective strategies to curb reproduction of stray dogs and cats are lacking, may be cost- and labour-intensive and are often regarded as controversial (Read et al., 2020; Wolf et al., 2019). Shelter policy makers will only agree to the selection of permanent sterilisation options that are affordable and they oppose alternative options which maintain sexual behaviour in pets as that may lessen the probability of adoption and increase pet abandonment. Veterinarians are in a key position to educate policy makers and the pet-adopting public about alternative approaches with less long-term health concerns. Their action may in time lead to acceptance of reproduction control options that better align with the health concerns of individual pets.

## 1.1 | Use of this document

These guidelines provide evidence-based scientific information on:

1. Achieving control of reproduction in dogs and cats with (spay-neuter, vasectomy, ovary-sparing techniques) or without surgery (through the use of hormones, vaccines, locally sclerotizing agents).
2. The benefits and the detriments of both approaches for the long-term health of dogs and cats.
3. The most cost-effective and ethical reproduction control strategies in shelter animal populations and non-owned dog and cat populations.

The purpose of this document is to assist veterinarians best apply current knowledge on surgical and medical reproduction control methods in dogs and cats with animal welfare as the first and foremost priority. Animal welfare is an elaborate concept, which requires sound scientific knowledge as well as applying common sense amidst the diverse settings of small animal practice. The risk of long-term health concerns associated with routine gonadectomy may no longer be acceptable for all owned pets. The concerns of shelter policy makers should be acknowledged. Cats and smaller breed dogs may be continued to be gonadectomised by traditional gonadectomy at traditional ages. Conversely, vasectomy and ovary-sparing surgery should be offered as an alternative option to gonadectomy following proper consultation with the prospective owners of large and giant breed dogs at risk.

There is not a single technique which is ideal in all situations or one which should never be used. Every approach to reproduction control has advantages and disadvantages depending on the practical/financial situation of the owner, genetics of the animal, age, health, lifestyle and purpose for which the animal is kept. Over the last few decades evidence of long-term health concerns associated with surgical gonadectomy such as orthopaedic, behavioural, endocrine and neoplastic conditions is continuing to emerge. As a consequence, the development of alternative reproduction control methods for animals at risk ensued. As more data becomes available on age of gonadectomy and individual breed risk, the choice of best reproduction control option based on individual case by case in consultation with pet owners will improve. Although surgical gonadectomy may remain a valid option for cats of both sexes and small and medium-sized female dogs, in large male and female dogs potential health concerns associated

with gonadectomy may make alternative options more appropriate and should be considered both in client- as well as shelter-owned animals.

The body of evidence regarding detriments and benefits of gonadectomy is complex, sometimes conflicting and differs depending on sex, species, age of gonadectomy and breed. Arriving at the best possible decision for the individual pet requires wide and intensive consultation with the pet owner. Considering the complex nature of this decision-making process and the multitude of factors to consider, the reproduction control guidelines are intended to provide a tool for small animal practitioners and policy makers to reach informed, consensual decisions while meeting the welfare interest of the animals, expectations of the pet owners and avoiding possible litigation.

Whilst there is a general expectation that guidelines should be concise and consistent, this is not achievable with the reproduction control guidelines. This is because there is a complex network of variables and circumstances that impact on the decisions of, should I or should I not neuter and if so, at what age and what method should I use. Therefore, standard routine recommendations suited as “best practice” for all animals cannot be made. What has become clear, however, is that the decision to routinely neuter all animals not intended for breeding can no longer be supported for all categories of animals. Harmonising risk/benefit assessment with client preferences, shelter requirements and most importantly, ultimate long-term welfare of the individual animal requires a thorough understanding of the confounding elements involved. These include age at gonadectomy, species, sex, breed, animal lifestyle, purpose of animal and whether the animal is owned and whether there is responsible pet ownership. In cases where there is responsible pet ownership, best practice may be to leave the animals unaltered unless there is a medical necessity to intervene. This had been advocated for decades in some parts of the world. In cases where permanent sterility is non-negotiable, hysterectomy may be suggested as an option. Routine OE and OHE should be reserved for those animals at lower risk or for those animals where the elimination of both reproduction and reproductive behaviour is necessitated.

## 2 | SURGICAL STERILISATION IN DOGS AND CATS

Sterilisation of dogs and cats is the most common surgical procedure performed by small animal practitioners worldwide (Greenfield et al., 2004). Numerous methods are employed successfully and can be divided into those that remove the source of gonadal hormones and those that preserve them. The role of gonadal hormones on long term health is debated, and this issue is discussed in detail later in this document.

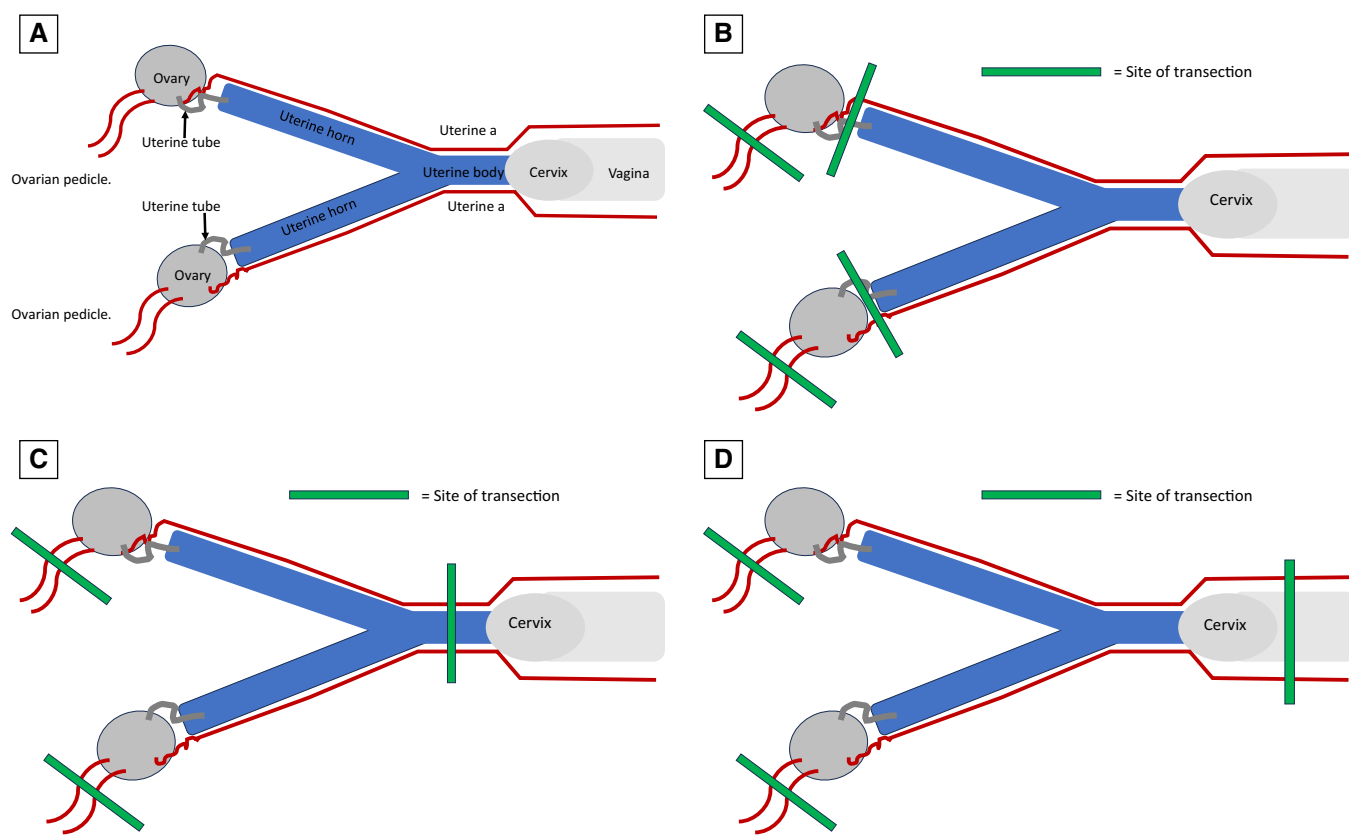
### 2.1 | Surgical methods of sterilisation in dogs and cats associated with loss of gonadal hormones

#### 2.1.1 | Female dogs

**2.1.1.1 | Ovariectomy, subtotal ovariectomy and ovariectomy:** Gonadectomy by removal of the ovaries alone (OE), or with concomitant partial (SOHE) or complete (OHE) removal of the uterus are the most common methods of surgical sterilisation of female dogs (Fig 1). Preventing cystic-endometrial-hyperplasia-pyometra complex has been touted as a reason for performing OHE but this condition will not occur without the presence of remnant ovarian tissue or an exogenous source of progesterone (DeTora & McCarthy, 2011; Noakes et al., 2001). Uterine tumours can be prevented by removal of the entire uterus, but the incidence of these is quite low and many are benign (Brodey, 1970; Saba & Lawrence, 2020). In addition, to our knowledge uterine neoplasia has not been reported in a dog or cat that has had OE alone before 2 years of age (DeTora & McCarthy, 2011). The incidence of uterine neoplasia if OE or SOHE is performed after 2 years of age is unknown and warrants investigation. Advantages of OE over the alternate procedures include a smaller incision and therefore possibly less pain, shorter surgical times, fewer sites for potential haemorrhage, less likely inadvertent ureter ligation and easier access to the ovarian pedicles (DeTora & McCarthy, 2011; Okkens et al., 1997; Van Goethem et al., 2006). For these reasons, in the absence of uterine pathology or pregnancy, OE is the preferred procedure for routine surgical sterilisation of female dogs if loss of gonadal hormones is desired.

OE, SOHE and OHE can each be performed by either laparotomy or laparoscopy. With the exception of OHE, the incision can be either on ventral midline or flank. Potential advantages of midline laparotomy include increased familiarity of regional anatomy for most surgeons and ability to simultaneously explore the abdomen for other reasons if necessary. Potential advantages of the flank laparotomy include less damage to mammary gland tissue if these glands are enlarged and easier visualisation of the incision after surgery in shelter or feral population situations (McGrath et al., 2004). No significant difference in ease of surgical procedure, rate of complications or pain has been consistently demonstrated between the laparotomy approaches, so choice is one of personal preference and training (Griffin et al., 2016; Looney et al., 2008). Laparoscopic surgery is less painful than laparotomy and provides improved visualisation and safety, especially in large breed dogs (Culp et al., 2009; Devitt et al., 2005; Fransson & Mayhew, 2015; Hancock et al., 2005). Wound complications are less frequent after laparoscopic procedures (Charlesworth & Sanchez, 2019). Owner familiar-





**FIG 1.** Sites of transection for surgical sterilisation of a female dog. (A) Basic anatomy of the female reproductive tract. (B) Ovariectomy. (C) Subtotal ovariectomy. Note that by placing forceps and transecting through the uterine body a short section of the distal uterine body remains. (D) Ovariectomy. Note that forceps are placed through or distal to the cervix, ensuring that the entire uterus including the uterine body have been removed

ity with minimally invasive surgery in humans has produced a large demand for performing sterilisation procedures with this method (Buote, 2022; Hsueh et al., 2018).

Each of the laparotomy procedures can be performed in paediatric (6- to 16-week-old) patients, provided several precautions are taken (Faggella & Aronsohn, 1994; Kustritz, 2002; Looney et al., 2008; Oliveira-Martins et al., 2023; Olson et al., 2001; Porters et al., 2015; Kustritz, 2002). Patients should be healthy, properly immunised for their age and have normal hydration status. A complete pre-anaesthetic physical exam should be performed, and a warm preoperative and postoperative environment provided. While traditional recommendation has been to avoid fasting greater than 4 hours to avoid hypoglycaemia, recent data suggests that hypoglycaemia does not occur in paediatric puppies  $\geq 0.9$  kg fasted for longer durations (Fudge et al., 2022). Puppies should be provided food after surgery as soon as the patient is able to stand (Griffin et al., 2016). Tissue dissection must be meticulous to avoid damage to delicate vital structures.

All animals surgically sterilised should be identified by tattoo, or other easily identified external means to avoid inadvertent reoperation at a later date (Looney et al., 2008; Mielo et al., 2022). Microchips are gaining popularity for pet identification, but inaccuracy of owner data, added expense and required access to an appropriate microchip reader limit their usefulness for identification of sterilisation status (Brent, 2019). A green linear tattoo applied to the ventral aspect of the abdomen either on or immediately lateral to the ventral midline is recommended for both female and male dogs (Griffin et al., 2016). If a flank approach is used for sterilisation of a female patient, the tattoo should be placed where a ventral midline incision would have been. Tattoo ink or paste can be applied directly to the surgical incision after intradermal closure, placed in a separate cutaneous incision or injected intradermally (Bushby, 2013; Griffin et al., 2016; Welborn et al., 2011).

A recent survey-based study including all USA and Canadian veterinary schools indicated that curricula included discussion of sterilisation identifiers in only 31% of lecture-based training, 75% of spay/neuter laboratory training and 38% of clinical practice-based training. The same study found that while 80% of shelters and 72% of spay/neuter clinics tattooed all owned animals, and 84% of shelters and 70% of spay/neuter clinics tattooed all unowned animals, private practices identified sterilisation status after surgery in only 5% of patients (Mielo et al., 2022). Enhanced training and implementation of sterilisation identifiers are needed throughout the veterinary industry (Mielo et al., 2022).



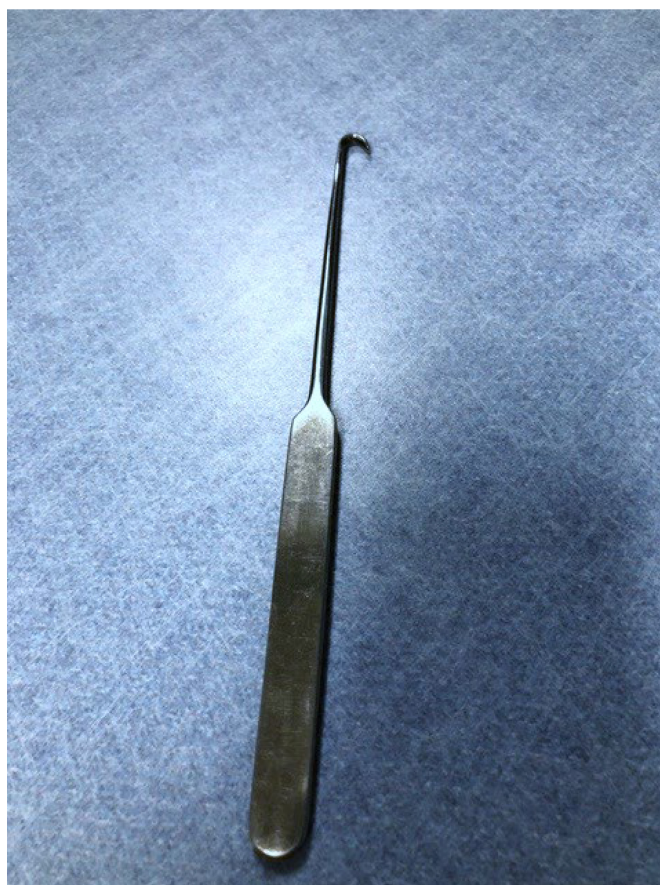**2.1.1.1.1 | Ventral midline laparotomy for ovariectomy in dogs:** Location of the initial skin incision is often calculated by dividing the distance between the umbilicus and pubis into thirds and making the incision the length of the cranial third. The length of the incision depends on the dog's size, amount of abdominal fat and surgical experience of the operator. The incision should not be longer than needed but should always allow adequate exposure to safely perform the procedure. Inadequate exposure increases the risk of haemorrhage from both the ovarian and uterine arteries, as well as incomplete removal of all ovarian tissue [ovarian remnant syndrome (ORS)]. While cold instrument incision with a scalpel blade is most frequently used, electroincision with an electrosurgery device reduces complications such as blood loss, incision redness and wound discharge without affecting clinical wound healing (Meakin et al., 2017).

A sharp or blunt dissection of the subcutaneous tissue along the midline is made with a scalpel blade or Metzenbaum scissors, respectively. Once the linea alba is clearly identified it is elevated with a thumb forceps and punctured with a scalpel blade sharp side facing up. The incision is extended towards both ends by cutting with a scissor or by using a blade with a tissue forceps or grooved director as a guide (Fig 2).

The uterus is located dorsal to the bladder and ventral to the descending colon by advancing the hand into the abdomen between the internal aspect of the abdominal wall (towards the palm of the hand) and the viscera (towards the dorsal aspect of the hand). Spay hooks (Fig 3) are commonly used and may be helpful in locating the first uterine horn; however, they must be used with great care, especially



**FIG 2. Grooved director.** An instrument placed between the linea alba and abdominal viscera to guide a scalpel incision while protecting abdominal viscera. It features a blunted point at one end and a butterfly-shaped handle at the other



**FIG 3. Spay hook.** An instrument used to retrieve and exteriorize the uterine horn. It has a curved tip working end with an ergonomic handle

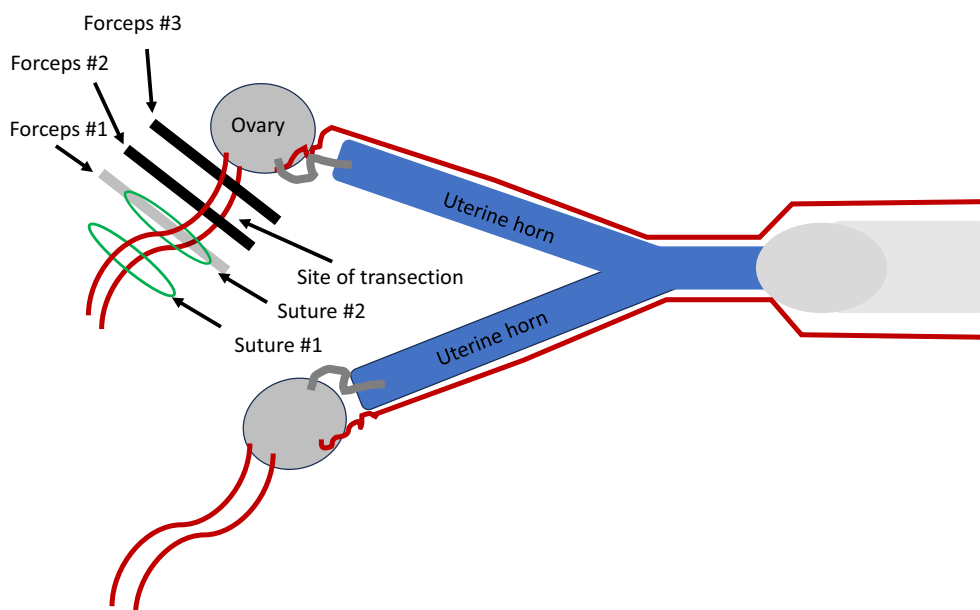
in very young animals, where potential risk of inadvertently damaging delicate intra-abdominal structures is increased. Either the left or right uterine horn can be identified first based on personal preference. The spay hook is positioned so that the hook points towards the body wall and is swept down the body wall to the inside fold of the ipsilateral rear leg. The point of the hook is then rotated 180° and swept slightly towards the midline incision. If the uterine horn is engaged, tension will be felt on the hook. Too much tension indicates that a ureter has likely been engaged. If so, the hook is disengaged, and another attempt made to engage the uterine horn (Valdez, 2022). If repeated attempts fail to isolate the uterine horn the abdominal incision should be enlarged, or an alternate method, such as direct palpation caudal to the kidney should be utilised. After the uterine horn is identified it is gently retracted and followed cranially until the ovary is located. Application of local anaesthetic to the ovary at this point improves intraoperative analgesia (Cicirelli et al., 2022).

Forceps are placed on the proper ligament to use for retraction and the suspensory ligament is broken or stretched with digital pressure. Performing this manoeuvre as close as possible to the diaphragm avoids inadvertent damage to the ovarian vessels. Sharp transection is faster and may cause less pain (Shivley et al., 2019). Releasing the suspensory ligament may not be required in all dogs, especially dogs who have previously given birth as there is increased laxity of the reproductive structures in these animals.

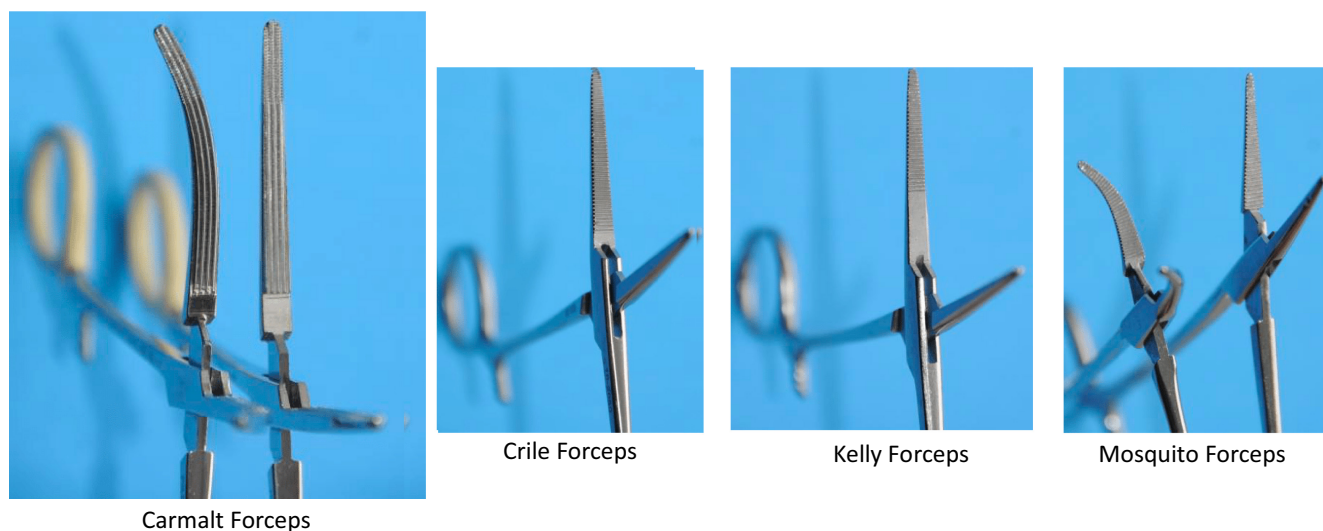
A window is made in the mesovarium immediately caudal to the ovarian vessels. Many methods for ligation of the ovarian pedicle have been described and used with success. In one common technique three forceps are placed on the ovarian pedicle. A first ligature is placed at least 2 to 3 mm distal to the most distal forceps and tightened. The most distal forceps is then “flushed” or released, and a second ligature placed in the crush (Fig 4). The pedicle (not either of the sutures) is grasped with thumb forceps and cut between the remaining two forceps. The middle forceps is removed and, after confirming lack of bleeding, the pedicle is released into the abdomen. Forceps placed on the ovarian pedicle should never be lifted directly as tearing of the delicate tissue may ensue. Forceps can be rolled 90° as needed for exposure, but any lifting should be done with the forceps on the proper ligament. Carmalt forceps are designed to create haemostasis along a large vascular pedicle and are preferred for very large dogs. Crile, Kelly or mosquito forceps are generally used for smaller patients (Fig 5). Each of these forceps are available in both straight and curved configurations and choice is based on surgeon preference. In smaller dogs ( $\leq 15$  kg) some surgeons prefer to avoid pedicle forceps altogether. In very large dogs or dogs with excessive fat, the pedicle can be very carefully divided into smaller pedicles for better ligature security.

After the ovarian pedicle is released into the abdomen single or double ligatures can be used to isolate and subsequently remove the ovary. In the single ligature method, a circumferential ligature is first placed through the previously created window in the mesovarium at the junction of the uterine tube and horn. Two forceps are then placed between the ligature and ovary. Cutting between the two forceps will free the ovary. In the double ligature method, three forceps are placed at the junction of the uterine tube and horn, and two ligatures are tied. The first ligature lies between the uterine horn and most caudal forceps and the second in the crush of the most caudal forceps. Sharp transection between the two remaining forceps frees the ovary which is removed from the surgical field (Fig 6) (Kutzler, 2020b). After confirming haemostasis, the second ovary is located by following the remnant uterine horn caudally to the uterine body and then up the contralateral uterine horn. The procedure is then repeated on the opposite side.

Many different types of knot designs have been used successfully for ligation of both the ovarian pedicle and mesovarium in dogs. Two-pass friction knots (miller's, modified miller's, constrictor and strangle knot) may be preferable to standard surgeon's or square knots, especially for inexperienced surgeons (Belluzzi et al., 2022; Erickson et al., 2020; Hazenfield & Smeak, 2014; Leitch et al., 2012)



**FIG 4.** Sites of forceps and suture placement for transection of the ovarian pedicle. Note that forceps #1 is generally “flushed” and the suture placed in the resulting crush



**FIG 5. Common forceps used for occlusion of a vascular pedicle. Note that the Carmalt forceps are larger and have wide parallel serrations, whereas the other types have finer perpendicular serrations. Serrations extend for the entire length of the jaw in mosquito and Crile forceps but only for part of the length in Kelly forceps**

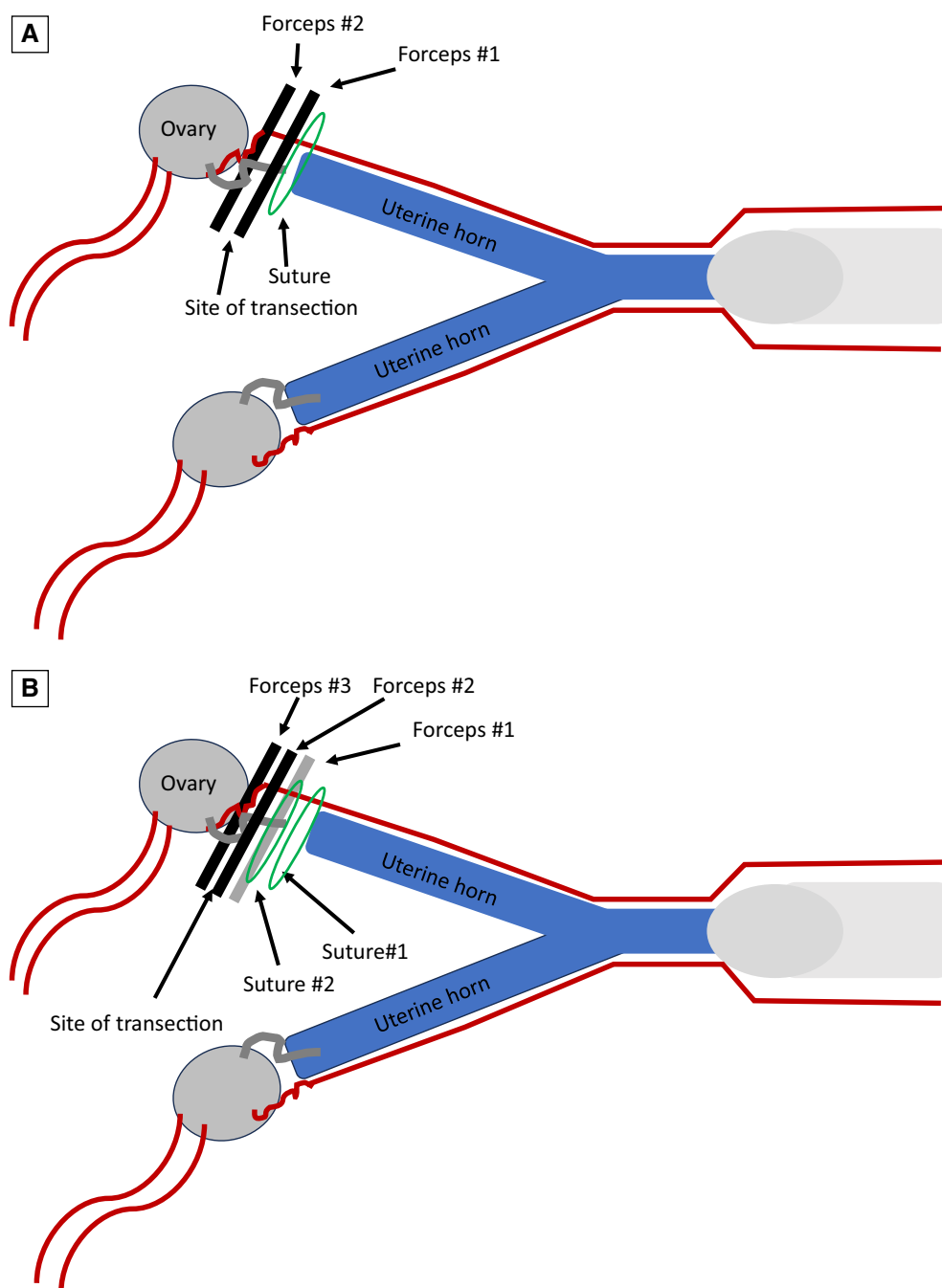
(Figs 7 and 8). Square knots may slip on the first throw if the tissue is excessively thick, and surgeons' knots can bind or "lock-up" prematurely, creating a dangerous situation in which the surgeon falsely thinks the knot has been tightly applied when it is not (Smeak, 2019). When forming a two-pass knot it is helpful to initially form the knot loosely on the jaws of a haemostatic forceps, then push it down over the jaws into the appropriate position. This enables the construction of the knot in a site with ample room (Smeak, 2019).

Suture selection is generally based on surgeon preference. High-volume high-quality (HVHQ) sterilisation clinics sometimes prefer ligation with chromic gut as it has relatively little memory and is less expensive than other materials (Valdez, 2022). Multifilament non-absorbable suture material and non-medical grade cable ties should be avoided due to increased risk of infection and fistula formation (Pearson, 1973; Werner et al., 1992) (Fig 9). Suture material must not be shared among patients owing to risk of disease transmission and cannot be re-sterilised (Druce et al., 1997; Vasseur et al., 1988). Triclosan-coated suture decreases adherence of methicillin-resistant *Staphylococcus pseudintermedius* but there is no evidence that the use of this material decreases postoperative infection rates in veterinary surgery (Morrison et al., 2016). Suture size is chosen based on the size of the pedicle, which is not always proportional to the size of the dog. The most common sizes are 2-0 and 0, although smaller sizes are sometimes appropriate.

Recent advances in methods of surgical haemostasis have provided several additional options to improve the safety, efficacy and speed of vessel attenuation during surgical procedures in dogs. Vascular clips (Fig 10) are available in multiple sizes and configurations, and these provide a quick and secure method of vessel attenuation (Costa et al., 2016; Watts, 2018). Self-locking ties are particularly useful for pedicle ligation in areas difficult to access (Fig 11). Electrosurgical devices apply high-frequency (radiofrequency) alternating polarity electrical current to biologic tissue as a means to cut, coagulate, desiccate or fulgurate tissue (Fig 12). Bipolar electrosurgery forceps are likely quicker and safer than monopolar when used on the ovarian pedicle (Van Goethem et al., 2003). Vessel-sealing devices are available that use electrothermal bipolar electrosurgery energy and pressure to induce denaturing and fusion of collagen and elastin within vessel walls, resulting in vascular occlusion (Peycke, 2015; Sackman, 2012). These devices come with a variety of handheld instruments with jaws designed to deliver bipolar energy into the grasped tissues. A system generator measures the electrical impedance of the tissues through a feedback mechanism and a precise amount of bipolar radiofrequency energy is generated. Vessel-sealing devices create minimal thermal spread and may be approved for vessels measuring up to 7 mm in diameter (Fig 13). Data suggest that they are equally effective at preventing haemorrhage during surgical sterilisation, while decreasing surgical time compared to standard suture methods (Cicirelli et al., 2023). Ultrasonic waves may also be used to effectively seal vessels up to 7 mm in diameter (Fig 14). High-frequency vibrations (55.5 kHz) produce lower temperatures than vessel-sealing devices and produce an "oscillating saw" effect to cut tissues and denature proteins to seal vessels.

After assuring that all surgical sponges are accounted for, closure of the abdominal cavity is done routinely, remembering that the external rectus sheath is the "holding layer" and must be included in suture bites. Most suture materials perform well for closing the linea alba except for chromic gut whose tensile strength may not be maintained for a sufficient duration of time. A quilting subcutaneous suture pattern has been described to reduce seroma formation and pain and is recommended (Travis et al., 2018) (Fig 15). Skin sutures are generally avoided in shelter situations or in patients where suture removal would be challenging. A carefully placed intradermal pattern and/or skin glue are useful in these situations. While intradermal patterns have traditionally been ended with a four-throw square knot, a two plus one Aberdeen termination knot is smaller, equally secure and easier to bury (Regier et al., 2015) (Fig 16). While assuring adequate strength, suture size should be as small as possible, as for every increase in size, volume increases four to six times and tissue reactivity two to three times (van Rijssel et al., 1989). Glue should be placed on top of rather than in the surgical wound itself (Fig 17).

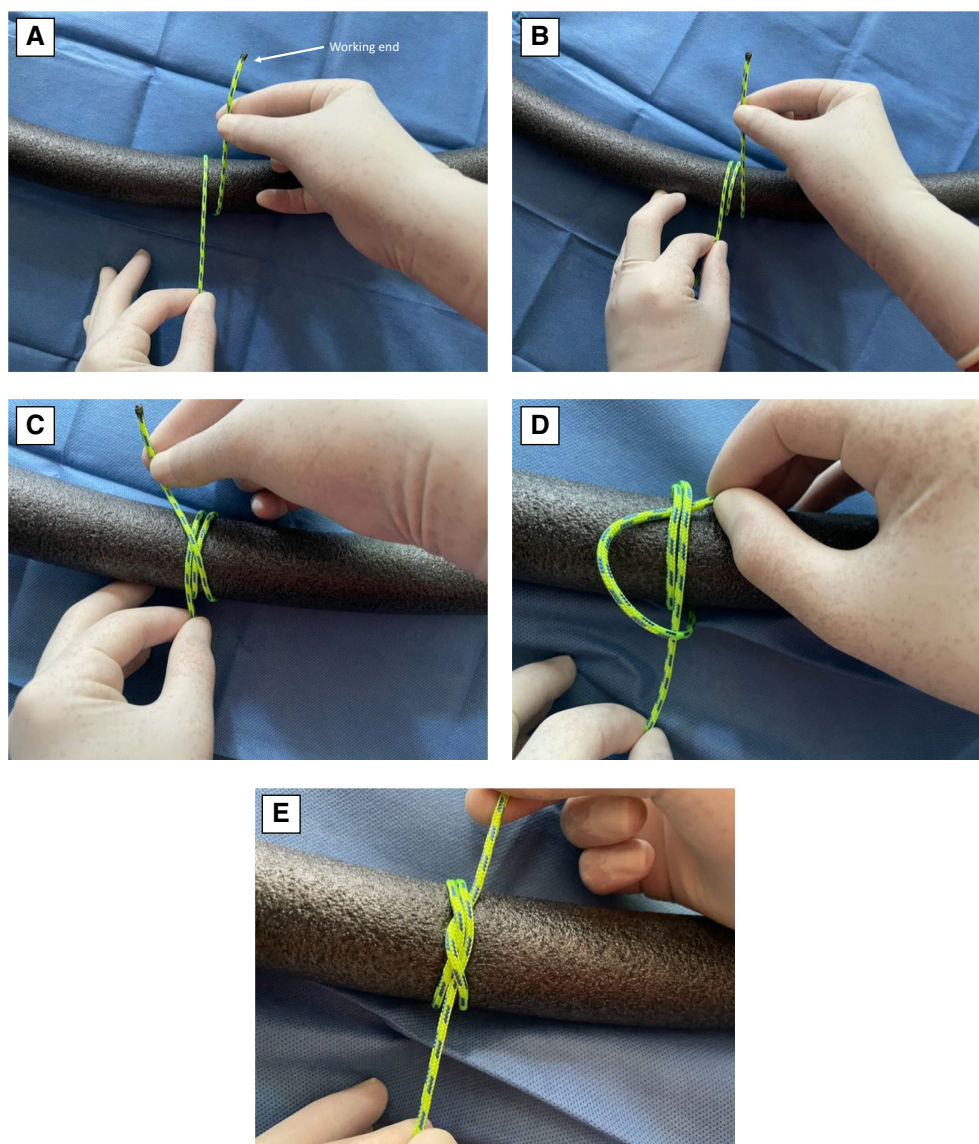




**FIG 6.** Sites of forceps and suture placement for transection of the mesovarium in an ovariectomy procedure. (A) Single ligature procedure. (B) Double ligature procedure. See Fig 4 for placement of forceps and suture on the ovarian pedicle.

**2.1.1.1.2 | Ventral midline laparotomy for subtotal ovariohysterectomy in dogs:** Subtotal OHE involves the removal of both ovaries with incomplete removal of all uterine tissue (Fig 1). This procedure is frequently performed by practitioners because isolation and removal of the entire uterus distally (true OHE) is technically more difficult. Distal ligations with SOHE are generally at the level of the uterine body. It should be noted that the preservation of uterine tissue inevitable with this procedure allows for the potential development of subsequent uterine stump granuloma. Cystic endometrial hyperplasia (CEH) complex/pyometra can also occur if there is an ovarian remnant or exogenous source of progesterone.

Surgical manipulations to perform SOHE are required more caudally in the abdomen than OE alone, so it is particularly important that the urinary bladder be emptied by manual expression soon after anaesthetic induction. If this is not possible, the bladder should be emptied by cystocentesis once the abdomen is open. The skin incision for SOHE must also be extended further caudally than for OE, generally including the middle as well as cranial third of the distance between the umbilicus and pubis.



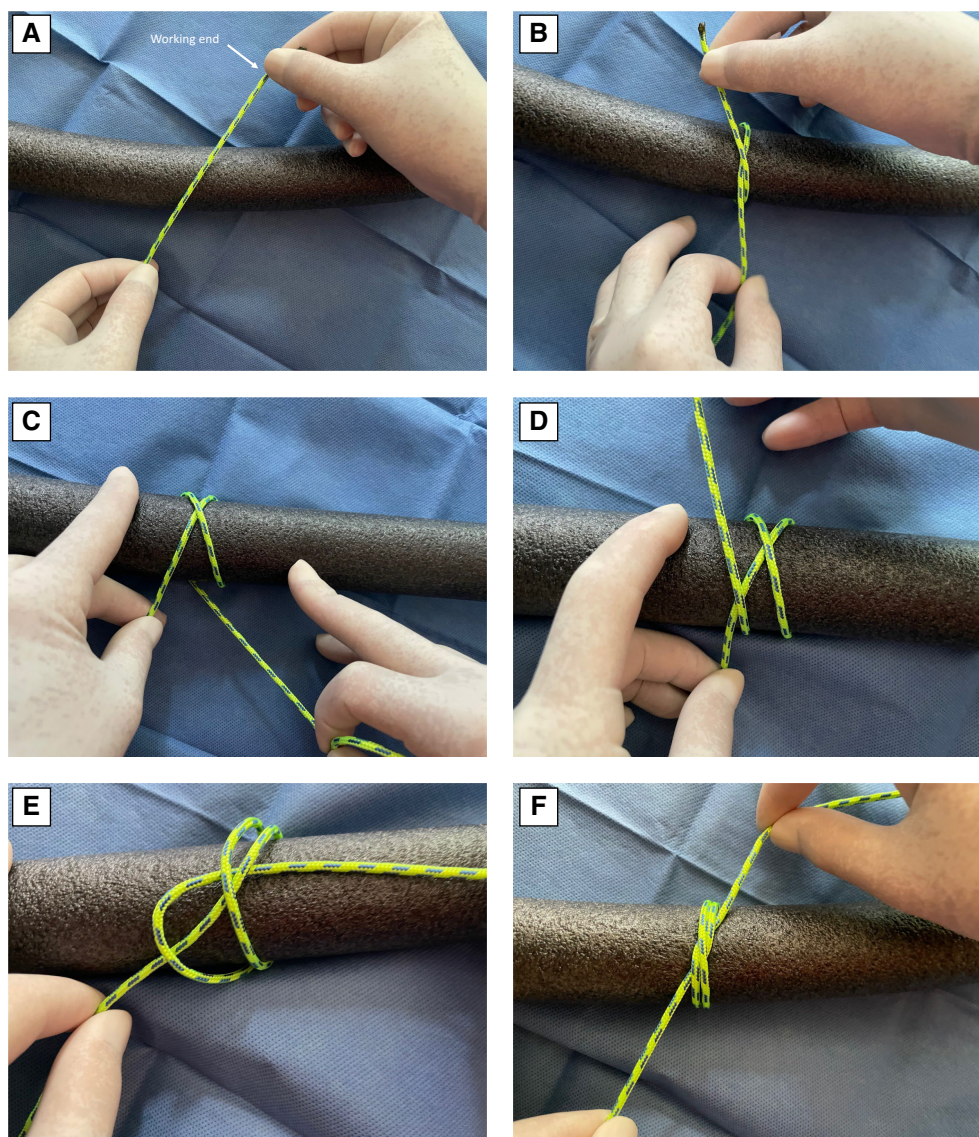
**FIG 7.** Formation of a modified miller's knot. (A) Working end passed over the top of the pedicle and around the pedicle. (B) Second pass around the pedicle. (C) Working end over the top. (D) Working end tucked under both loops. (E) Cinched tight

Identification, isolation, ligation and transection of both ovarian pedicles are the same as previously described for OE. The mesometrium is then cut or bluntly dissected lateral to the uterine artery to the level of the uterine body. This tissue should be ligated or electrocoagulated if highly vascularized.

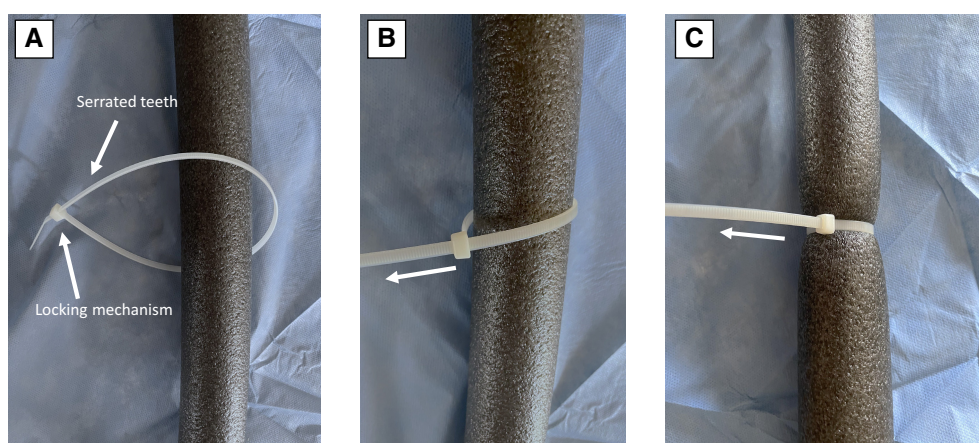
Many techniques have been described and used successfully for uterine artery ligations and transection of the distal reproductive tract. In one common technique, two forceps are first placed across the uterine body. Both uterine arteries are individually transfixed caudal to the forceps, and then a third circumferential ligature placed caudal to these. Either traditional or modified transfixing sutures can be used for this purpose. In the traditional method, the first throw of a square knot is placed incorporating about one-third of the uterine body and uterine artery on the same side. The suture ends are then passed 360° around the tissue and a four-throw square knot tied on the opposite side (Fig 18). The modified transfixation method is similar, except that a complete square knot is placed on the first side (Fig 19). It is important to note that the transfixation sutures should be placed cranial (closest to the subsequent transection site) to the subsequent circumferential ligation (Fig 20). This provides some protection to haemorrhage if one of the transfixation sutures inadvertently penetrates a uterine artery. Similar to ligation of the ovarian pedicle, using a two-pass friction knot such as a miller's knot is advantageous for the circumferential ligature. The uterine body is then transected between the two forceps and the reproductive tract removed from the surgical field.

Use of a vessel-sealing device has been reported for closure of uterine horns in dogs, but unacceptably low bursting strength was measured when applied to uterine bodies  $\geq 9$  mm in diameter (Barrera & Monnet, 2012). Vessel-sealing devices are designed to seal






**FIG 8.** Formation of a constrictor knot. (A) Working end passed over the top of the pedicle. (B) After a single loop is formed working end crossed over the top of the standing end. (C) A second loop formed with the working end. (D) Working end crossed over the standing end a second time. (E) Working end tucked beneath both loops. (F) Cinched tight




**FIG 9.** A commercially available cable tie. (A) Teeth on one end of the tie engage a locking mechanism on the opposite side. (B) Tie is tightened by pulling on the free end. (C) Final tightening





**FIG 10. Vascular clips. (A) Vascular clips are available in several sizes and configurations. (B) Cassette with vascular clips. (C) Clip is loaded onto applicator handle and ready for use**



**FIG 11. Self-locking suture tie: (A) Self-locking ties provide a loop of suture with a preformed slip knot on the end of an application rod. (B) The preformed knot is passed over the structure to be ligated. (C) Once in position the loop is tightened by pulling on the free end. (D) The rod is used to push the knot securely against the pedicle. (E) Once secure the rod is released and the suture cut to appropriate length**


vessel walls, not other soft tissue structures. If a vessel-sealing device is used in this situation, care should be taken to assure appropriate size of the uterine body. Alternatively, the device can be used on the uterine vessels, and the body ligated with traditional methods.

Before closure, the cut surface of the remaining uterus is evaluated carefully for bleeding. Abdominal wall, subcutaneous and skin closure is the same as described for OE.

**2.1.1.1.3 | Ventral midline laparotomy for ovariectomy in dogs:** By definition, OHE involves the removal of both ovaries and all uterine tissue, including the uterine body. OHE is not recommended when dogs are in heat as in addition to the added risk of haemorrhage, damage may occur to the vaginal transection site if mating occurs soon after surgery. Because surgical manipulations will be performed very caudal in the abdomen it is particularly important that the urinary bladder be emptied by manual expression soon after anaesthetic induction. If this is not possible, the bladder should be emptied by cystocentesis once the abdomen is open. To gain access to the entire reproductive tract, the skin incision must be extended further caudally than for OE or SOHE. In nulliparous animals and very young animals where the uterus is less pliable, it is often necessary for the incision to extend from just caudal to the umbilicus to just cranial to the pubic brim.

Identification, isolation, ligation and transection of both ovarian pedicles are the same as previously described for OE. The mesometrium is then cut or bluntly dissected lateral to the uterine artery to the level of the cervix and cranial vagina. This tissue should be ligated or electrocoagulated if highly vascularized.





**FIG 12. Electrosurgery device. Note the ability to provide coagulation, cutting and fulguration of tissue as well as offer unipolar and bipolar application of energy**

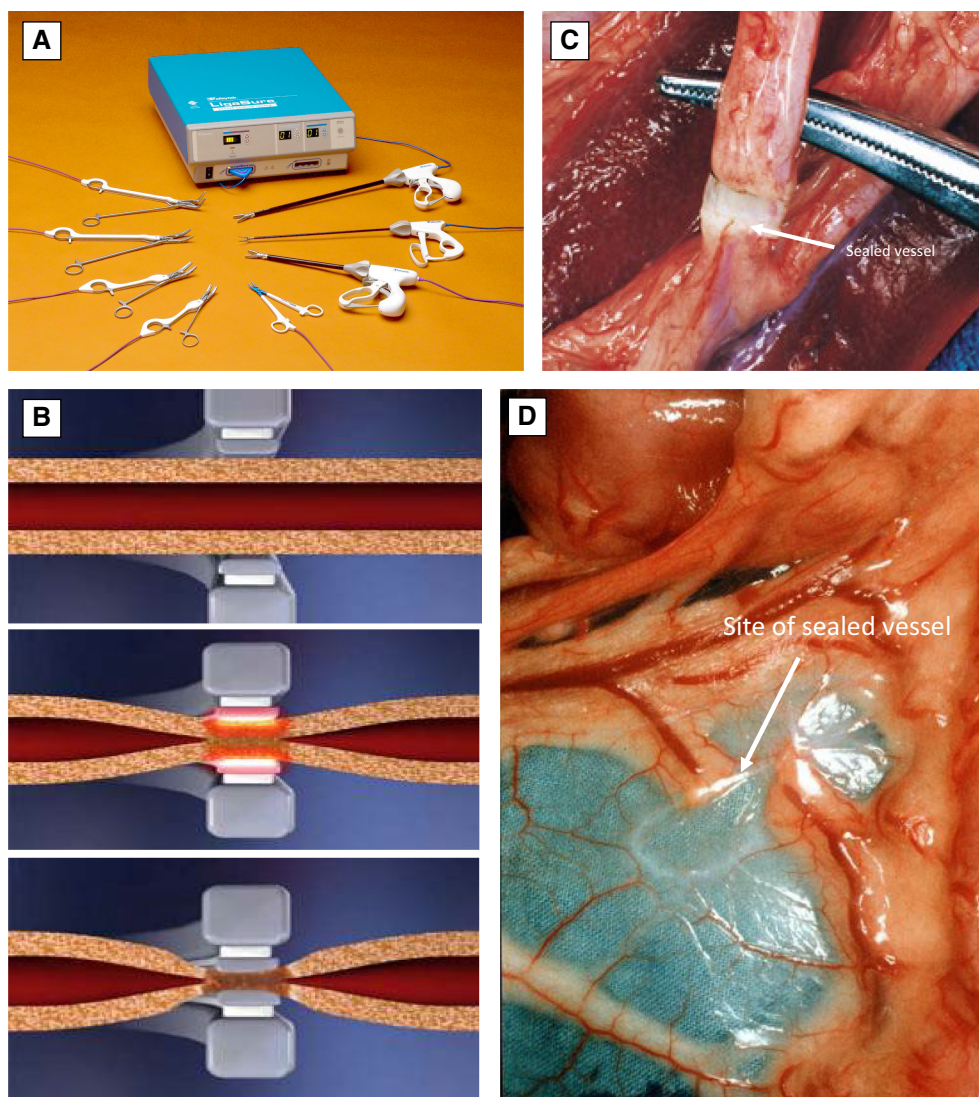
To perform OHE correctly, all forceps and ligatures must be placed at the level of the cervix or cranial vagina. Sutures hold poorly in the highly fibrocartilaginous canine cervix, so placement in the cranial vagina is preferred, especially in post-pubertal dogs. This location is very caudal in the abdomen and exposure can be difficult. A surgical assistant is helpful for retraction when performing this part of the procedure.

In one common technique, two forceps are placed across the cranial vagina at the junction with the cervix. Both uterine arteries are individually transfixated caudal to the forceps, and then a third circumferential ligature placed caudal to these. Either traditional or modified transfixing sutures can be used for transfixation of the uterine arteries. In the traditional method, the first throw of a square knot is placed incorporating about one-third of the tissue and the uterine artery on the same side. The suture ends are then passed 360° around the tissue and a four-throw square knot tied on the opposite side. The modified transfixation method is similar, except that a complete square knot is placed on the first side. It is important to note that the transfixation sutures should be placed cranial (closest to the subsequent transection site) to the subsequent circumferential ligation. This provides some protection against possible haemorrhage if one of the transfixation sutures inadvertently penetrates a uterine artery (Fig 21).

Similar to ligation of the ovarian pedicle, using a two-pass friction knot such as a miller's knot is advantageous for this circumferential ligature. The vagina/cervix is then transected between the two forceps, allowing removal of the entire uterus and both ovaries. The remaining tissue should be checked to ensure that no uterus remains, and the cut surface evaluated carefully for bleeding before replacing back into the abdomen.

While successful use of a vessel-sealing device has been reported for closure of the uterine horn in dogs, uterine bodies  $\geq 9$  mm in diameter failed at unacceptably low bursting strengths (Barrera & Monnet, 2012). OHE requires distal closure at the level of the cervix or cranial vagina and bursting strength after application of a vessel-sealing device has not been investigated in this location. Until such studies are available, the use of a vessel-sealing device for closure of the cervix or cranial vagina is not recommended.

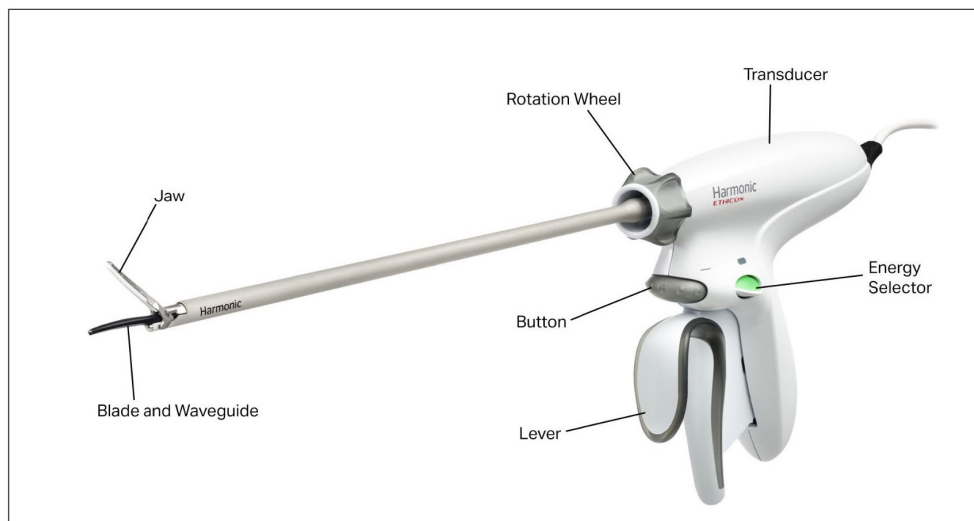
**2.1.1.1.4 | Flank laparotomy for ovariectomy and subtotal ovariohysterectomy in dogs:** Flank laparotomy can be used for the removal of both ovaries and most of the uterus, but exposure is inadequate for true OHE. Dogs are usually positioned in left lateral recumbency with the right hind limb extended caudally and secured to the table (Reece et al., 2012). A cranial-caudal incision is made in the right flank ventral to the iliac crest at the level of the fold of skin connecting the stifle to the abdominal wall. Similar to ventral midline surgery, in young dogs it may be preferable to make this incision slightly more caudal. The external abdominal oblique muscle or its aponeurosis, internal abdominal oblique muscle and rectus femoris muscles are sequentially exposed and separated parallel to their muscle fibres by blunt dissection. After entering the abdominal cavity, a spay hook is used to retrieve the right uterine horn which is followed to the right ovary. All subsequent intra-abdominal procedures are the same as for the ventral midline laparotomy. If difficulty is encountered retrieving the second (contralateral) ovary bilateral flank incisions can be made (Janssens & Janssens, 1991). Some surgeons feel that retrieval of the contralateral ovary is easier if the uterine body is ligated and released first (Dorn, 1975). Closure must incorporate the transversus abdominis and internal and external abdominal oblique muscles.



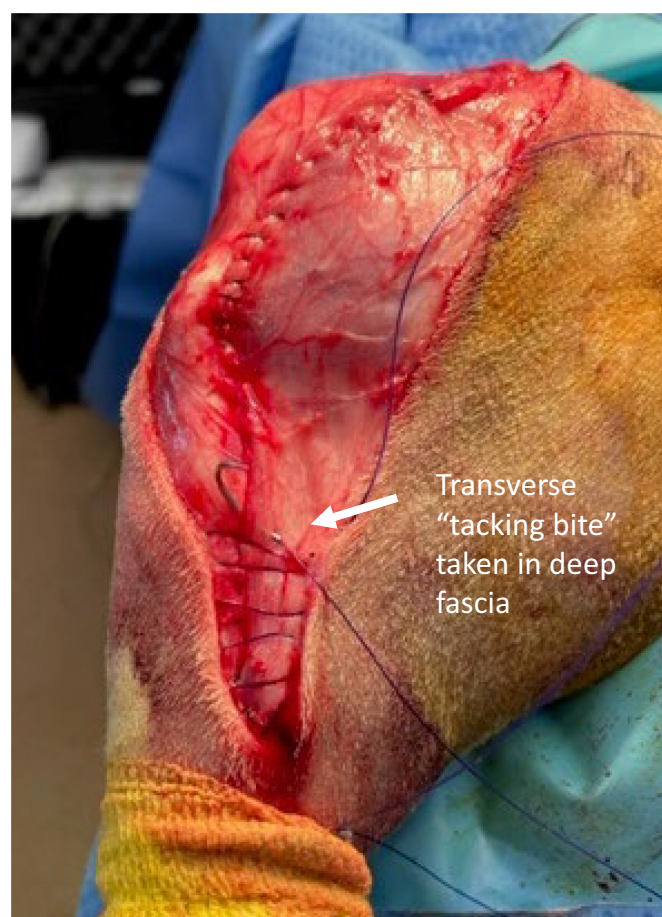
**FIG 13. Vessel-sealing device.** (A) Vessel-sealing devices offer a wide variety of handpieces for different applications. (B) Once the jaw is closed, the system measures impedance of the tissue and chooses the appropriate energy setting. A feedback mechanism senses when tissue response is complete and stops the cycle. (C) Vessels up to 7 mm in diameter can be safely occluded. (D) Appearance of vessel-sealing 28 days after surgery. Note the lack of inflammation

**2.1.1.1.5 | Laparoscopic ovariectomy, subtotal ovariectomy and ovariectomy in dogs:** While laparoscopic sterilisation of all sized dogs is possible (Matsunami, 2022), the procedure is most beneficial in larger patients. Many different techniques have been described and utilised with success. Removal of the uterus is not necessary for sterilisation, so most laparoscopic sterilisations with loss of gonadal hormones are done by OE alone. Traditional laparoscopy can be performed using one or two port methods, and a natural orifice transluminal endoscopic surgery has also been described (Arntz, 2019; Bakhtiari et al., 2012). Laparoscopic OE using only a single port is likely quicker but requires either an operating laparoscope or a laparoscopic port that allows the introduction of multiple instruments simultaneously (Gonzalez-Gasch & Monnet, 2015; Khalaj et al., 2012) (Fig 22). The two-port method utilises one port for the telescope and camera (optical port), while the second port is the instrument port.

To perform laparoscopic OE using the two-port method dogs are positioned in dorsal recumbency and secured to an operating table that allows for medial to lateral rotation. Port locations will vary based on the size of the patient. In a 40-kg dog, the first port placed is for the telescope and generally located about 2 to 4 cm caudal to the umbilicus. This port can be placed using either a Veress needle for initial insufflation or a Hasson technique. Abdominal insufflation with carbon dioxide to a pressure of 12 to 14 mmHg is used to provide optimum visualisation while minimising adverse physiologic effects (Kolata & Freeman, 1999). Portal pressure increases exponentially with intra-abdominal pressure, so the minimum pressure that allows adequate visualisation is preferred (Parlier et al., 2024). Assisted ventilation is generally not required, but clinicians are advised to monitor for hypercapnia during the procedure (Merlin et al., 2022). Initial introduction of the telescope is directed to the right to avoid inadvertent laceration of the spleen. An instrument port is then placed 2 to 4 cm cranial to the umbilicus under visual guidance (Fig 23). The patient is rotated 45° lateral



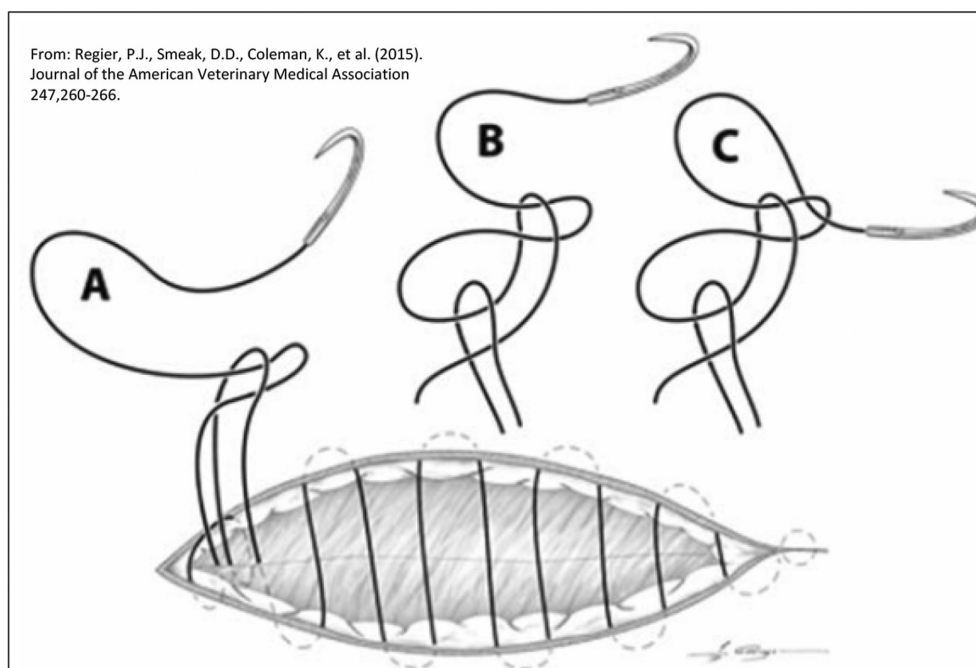
**FIG 14. Typical components of an ultrasonic dissector and sealer**



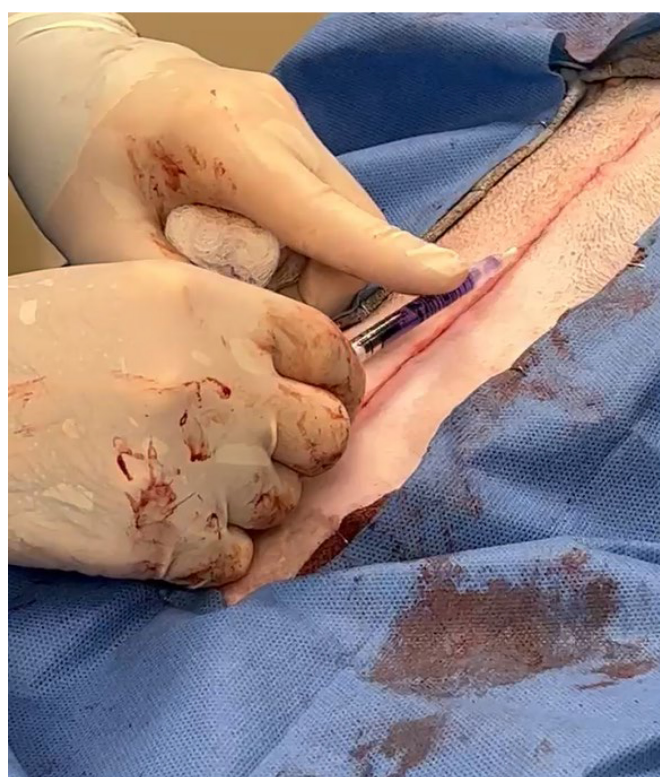**FIG 15. Quilting subcutaneous suture pattern used on closure of a stifle incision. A transverse bite is taken in the deep fascia to eliminate dead space and decrease likelihood of seroma formation. In the figure, one deep bite is taken after 4 horizontal passes for illustration. Generally, a deep bite would be taken every two to three horizontal passes**

and the ovary on the upside located. This often requires gentle manipulation of abdominal viscera with a grasper or “shaking” the abdomen to improve visualisation of the relevant gutter. Once the ovary is identified the proper ligament is grasped through the instrument port, held against the body wall and a large swaged-on needle with #2 suture material or a commercial OE hook (Fig 24)





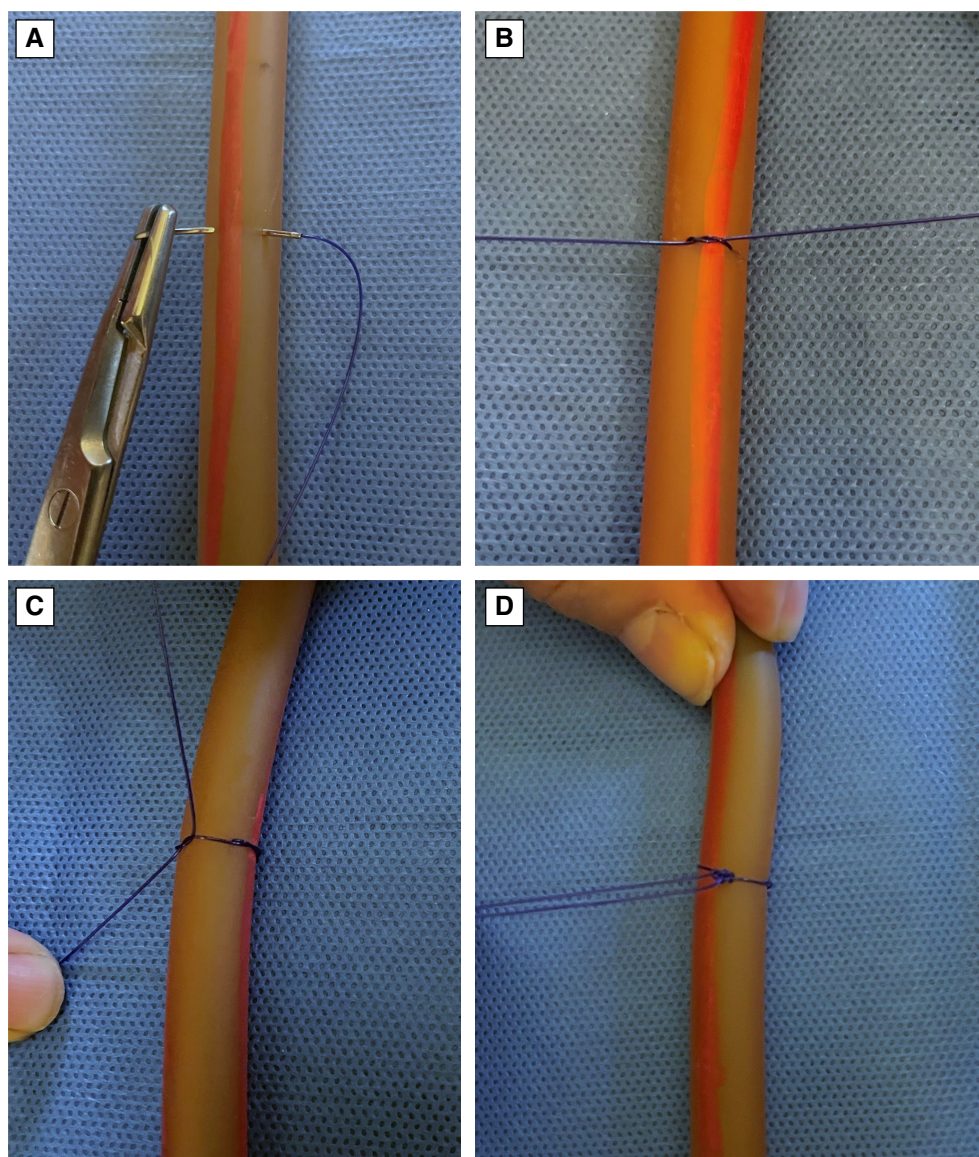
**FIG 16. Aberdeen termination knot.** The Aberdeen knot is an alternative to the square knot for ending a continuous line when the surgeon is left with a loop and a free end. The 2+1 configuration is demonstrated. (A) An initial throw is taken through the end loop. (B) A second throw is taken through the newly formed loop. (C) The end of the suture is passed through the final loop and cinched tight



**FIG 17. Application of skin glue to close a dermal wound.** Only small amounts are necessary, and the glue should be placed on top of rather than deeply within the wound. In the picture, glue has been transferred from the commercially supplied tube to a 1.0 cc syringe and 25 g needle for more precise application

is passed through the abdominal wall, ovarian pedicle and then back through the abdominal wall to “skewer” and stabilise the ovary. A specially designed transabdominal organ retraction device may be useful in dogs with very thick abdominal walls where needle passage is difficult or impossible (Delaune et al., 2021). In this position, both the ovarian pedicle and soft tissue attachments between the





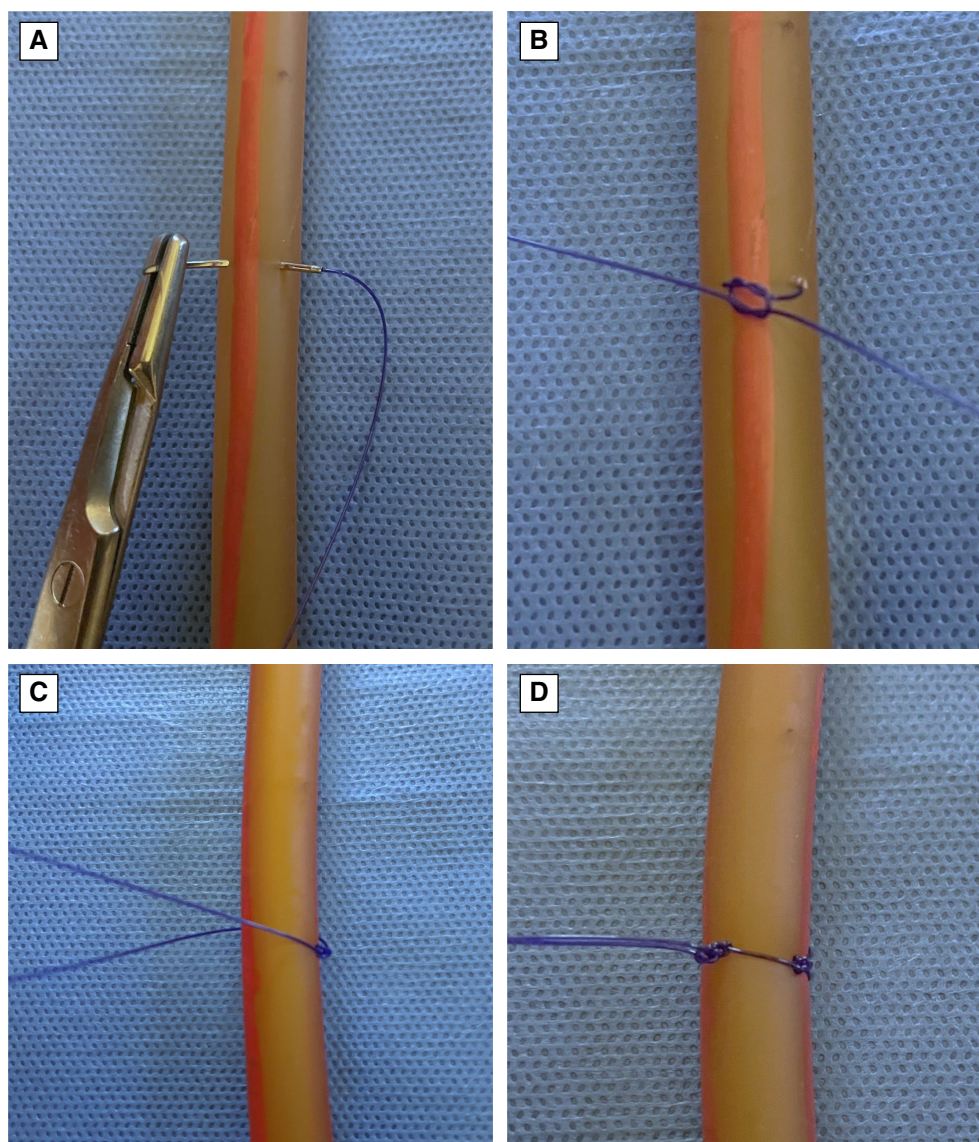
**FIG 18. Traditional method for transfixation of uterine arteries. (A) Suture is passed through about one-third of the uterine body and around the uterine artery on the same side. (B) The first throw of a square knot is placed. (C) Suture ends are passed 360° around the uterine body and opposite uterine artery. Square knot started. (D) A four-throw square knot is completed on the opposite side**

uterine horn and ovary can be electrocoagulated, clipped or fused with a vessel-sealing device (Mayhew & Brown, 2007). Once free, the ovary is retrieved through the instrument port. In large dogs with fatty pedicles, it is often necessary to enlarge the instrument port somewhat for retrieval. The patient is then repositioned into the opposite lateral recumbency, and the procedure is repeated on the opposite side.

Laparoscopic SOHE and OHE are often performed as a “laparoscopic-assisted” procedure with three ports (Fig 25). Positioning, placement of the camera and first instrument port, identification of the reproductive structures, transabdominal fixation of the ovary to the abdominal wall and pedicle transection are the same as for two port OE. While maintaining the transabdominal fixation suture a short section of proximal mesometrium is electrocoagulated or sealed with a vessel-sealing device to aid in future retrieval of the uterus. The patient is then positioned into the opposite lateral recumbency, and the procedure is repeated on the opposite side.

Once both ovarian pedicles have been transected the patient is repositioned into dorsal recumbency, the telescope rotated 180° to view caudally, and a third port is placed in a pre-pubic location under direct camera visualisation. The telescope is then rotated back to view in a cranial direction and one of the transfixed ovaries is identified. The ovary or proximal uterus is grasped with an instrument placed through the pre-pubic port and retracted to the level of, but not through the port. By maintaining the fixation suture during this manoeuvre, the ovary can be retrieved easily if it is inadvertently dropped. Once in this location, the third port site is enlarged



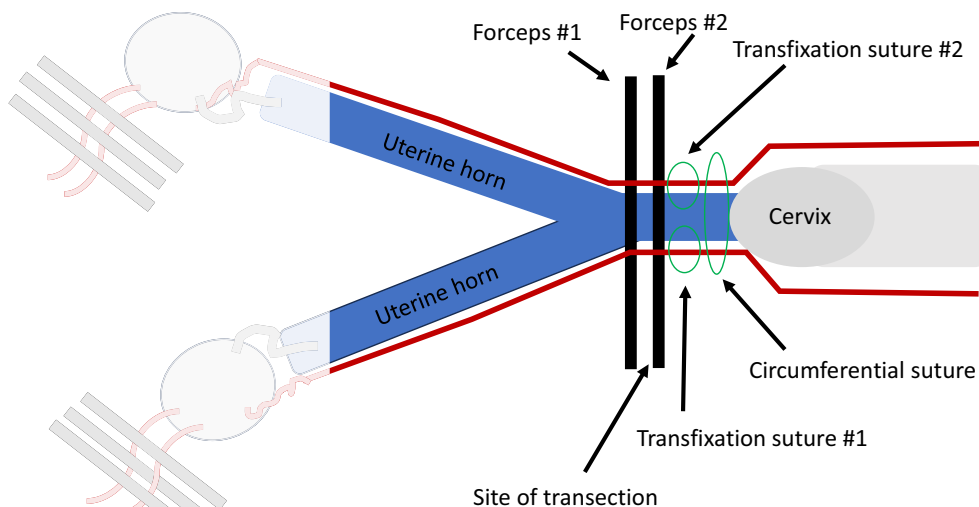


**FIG 19. Modified method for transfixation of uterine arteries. (A) Suture is passed through about one-third of the uterine body and around the uterine artery on the same side. (B) The first two throws of a square knot are placed. (C) Suture ends are passed 360° around the uterine body and opposite uterine artery. (D) A four-throw square knot is tied on the opposite side**

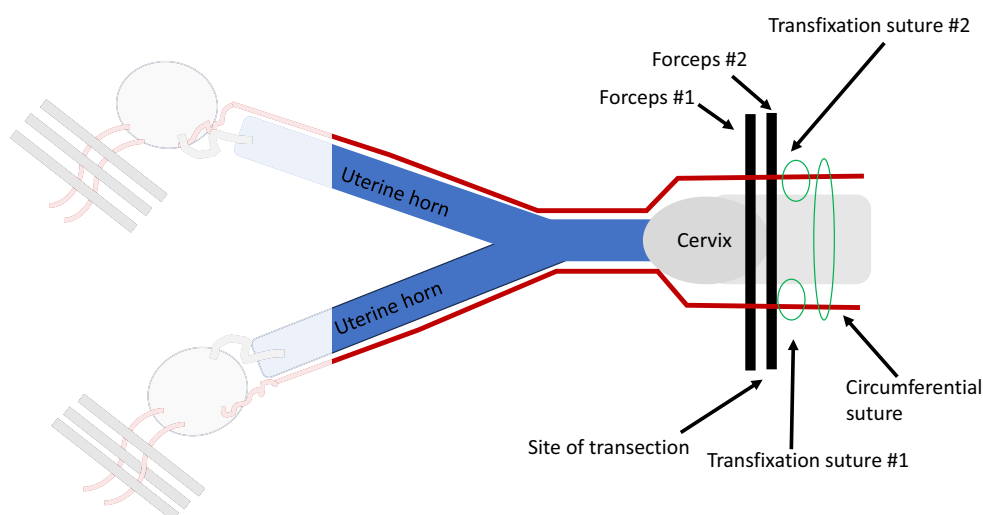
sufficiently to allow the grasped ovary, uterine horn and uterine body to be delivered through the incision. Gentle manual retraction is then used to retrieve the opposite side of the reproductive tract. The remainder of the procedure is performed extracorporeally with ligature placement and transection the same as for the procedures performed by laparotomy.

Complete evacuation of the carbon dioxide gas used for insufflation is important before closure as any remaining gas distension is painful. Port sites are closed in two layers with simple interrupted or continuous absorbable sutures in the external rectus sheath and subcutaneous tissue. Skin glue can be utilised as needed. Each port site should be blocked with local anaesthetic to aid in postoperative analgesia.

**2.1.1.1.6 | Ventral midline laparotomy for surgical sterilisation of the periparturient female dog:** Surgical sterilisation of the periparturient female dog with loss of gonadal hormones can be accomplished either by performing SOHE after delivery of the puppies by hysterotomy or using an en-bloc SOHE technique. While sometimes suggested, there is no evidence that simultaneously performing either of these sterilisation procedures increases maternal risk provided adequate fluid therapy support is delivered (Guest et al., 2023). Lactation is unaltered as it is dependent on oxytocin and prolactin, both derived from the pituitary, rather than ovarian hormones. Special care should be taken to assess and stabilise the patient before surgery as many are haemodiluted and haemodynamically unstable (De Cramer et al., 2016; Evci et al., 2023; Proctor-Brown et al., 2019).



**FIG 20.** Location of forceps and ligatures for ligation and transection of the uterine body for subtotal ovariectomy. Note that the transfixation sutures are cranial to the circumferential suture. This provides some protection against possible haemorrhage if one of the transfixation sutures inadvertently penetrates a uterine artery

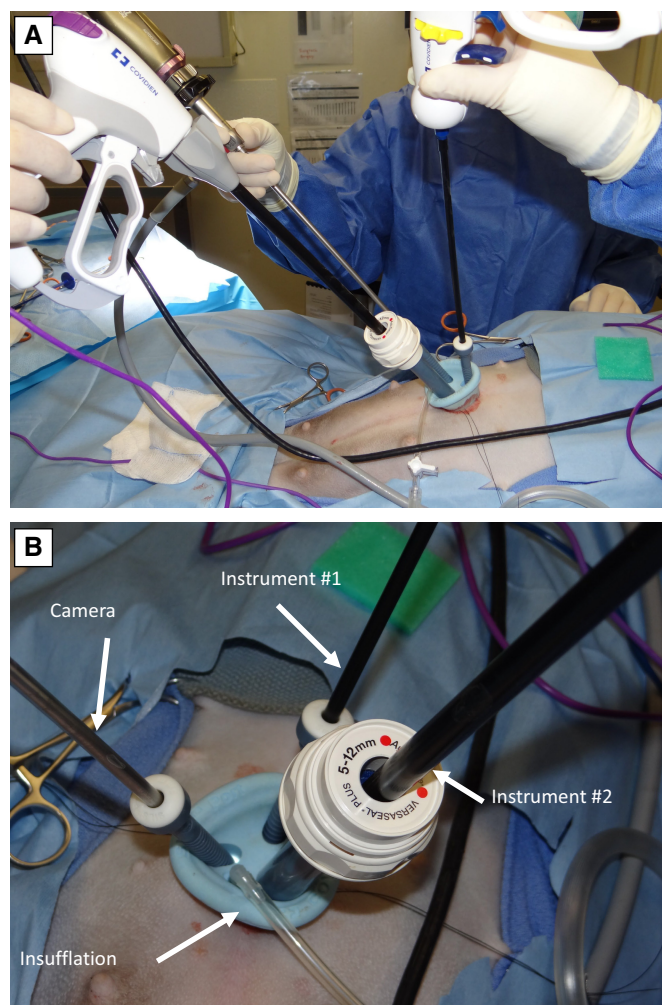


**FIG 21.** Location of forceps, ligatures and transection site of the cranial vagina for ovariohysterectomy. Note that all surgical manipulations are at the level of the cranial vagina and that the transfixation sutures are cranial to the circumferential suture. Placing the circumferential suture in this location provides some protection against possible haemorrhage if one of the transfixation sutures inadvertently penetrates a uterine artery

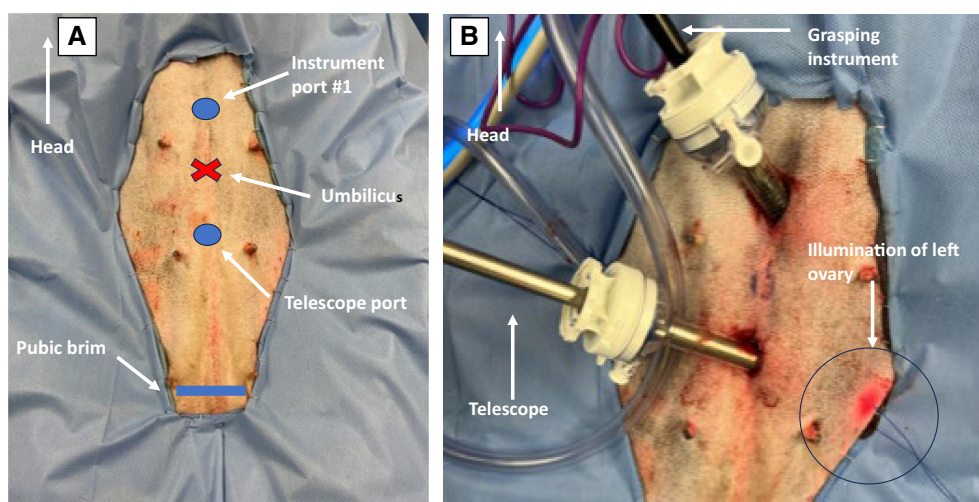
**2.1.1.1.6.1 | Hysterotomy and concurrent subtotal ovariohysterectomy:** The patient is placed in dorsal recumbency with the head positioned 15° to 30° above the tail (Reverse Trendelenburg Position) to decrease pressure on the diaphragm, improve respiration and decrease regurgitation. Rotation 10° to 15° to the side has been suggested to prevent supine hypotension syndrome (Biddle & Macintire, 2000; Gilson, 2016) but several studies have failed to document this condition in dogs (Probst et al., 1987; Probst & Webb, 1983). It is likely that compared to humans the pregnant female dog has adequate collateral circulation when the caudal vena cava is compressed. Alternatively, the bicornuate canine uterus may actually not compress the centrally located caudal vena cava. Regardless of cause, lateral rotation into an oblique position is unnecessary.

The skin incision is made on ventral midline from just cranial to umbilicus to the pubis, being cautious to avoid the mammary glands and remembering that the linea alba is thinner and wider than usual due to abdominal stretching. The uterus is exteriorized and packed off with moistened laparotomy sponges. A longitudinal incision is made in the body of the uterus of adequate length to assure fetal removal without tearing. If a fetus is stuck in the pelvic canal, it should be removed first so it can be first for resuscitation. Each fetus is then gently massaged towards the incision by “milking” towards the hysterotomy incision. Once visible in the hysterotomy, the fetus is grasped, and gentle but steady traction is applied until the placenta releases from its zonary attachment. Removal of the placenta is optional provided the cervix is open, so if the placenta is firmly attached it is best to allow it to pass on its





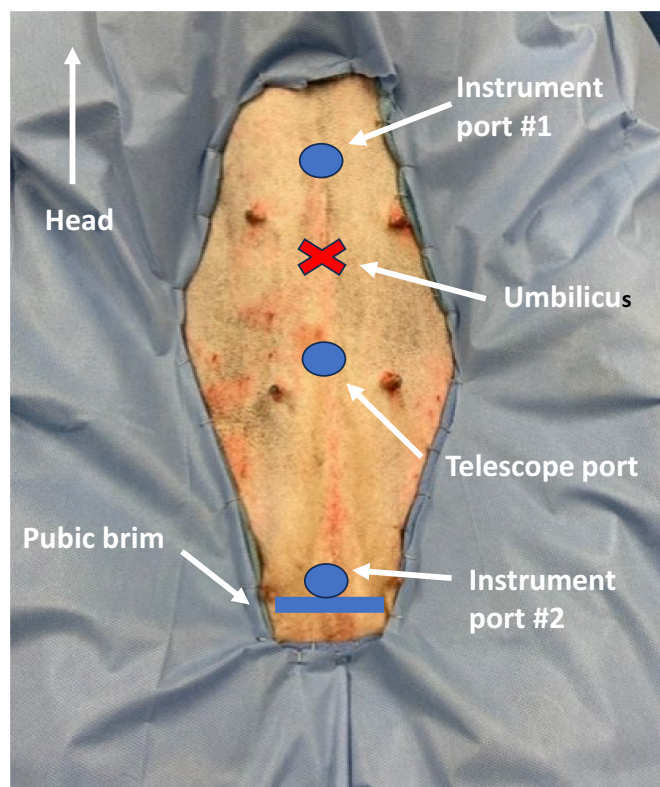
**FIG 22. Multiple access laparoscopic port. (A) A multiple access laparoscopic port allows insertion of multiple instruments through a single incision. (B) Close up view. In this case, the camera, two working instruments and insufflation are all provided through a single incision**



**FIG 23. Port placement for laparoscopic ovariectomy. (A) The telescope port will be placed about 2 to 4 cm caudal to the umbilicus for a 40-kg dog. The instrument port is placed a similar distance cranial to the umbilicus. (B) Both telescope and grasping instrument in place. Note the illumination of the body wall at the site of the ovary**



**FIG 24.** Ovariectomy hook is large curved blunt ended metal hook used to pass through the abdominal wall and secure the ovary



**FIG 25.** Port placement for laparoscopic subtotal ovariectomy or ovariectomy. Note the additional port just cranial to the pubic brim needed for exteriorization of the caudal reproductive tract

own. Increased uterine haemorrhage may occur with forceful removal. The neonate is freed from the amniotic sac and using a sterile towel handed off to an assistant with the placenta attached for further care. Once all neonates have been delivered, the hysterotomy incision is closed in a single layer simple continuous pattern to prevent abdominal contamination. Routine SOHE is then performed as described previously. Special care should be taken to assess for excessive bleeding as vessels will be prominent in this situation.

Closure of the abdominal wall is routine, remembering that the linea is thinned and stretched under the influence of increased abdominal pressure and relaxin. An intradermal pattern is recommended for skin closure to avoid damage by suckling puppies and all antiseptics used for skin preparation should be carefully cleansed. Appropriate postoperative pain management should be emphasised in these cases (Guest et al., 2023).



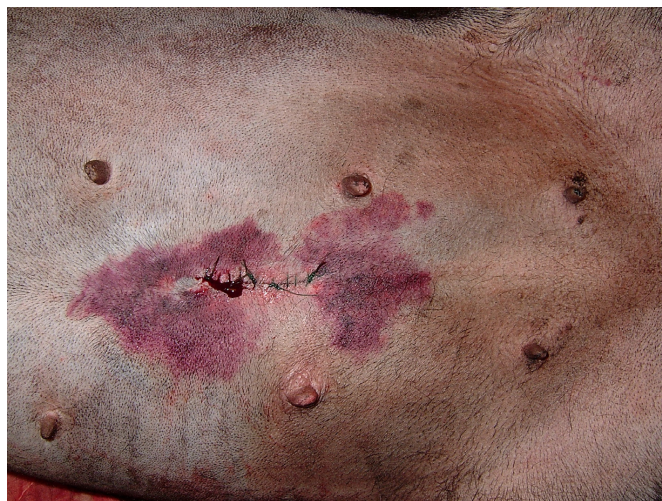**2.1.1.1.6.2 | En-bloc subtotal ovariohysterectomy:** En-bloc SOHE involves the removal of the ovaries and the majority of the uterus *before* hysterotomy and delivery of the fetuses in a pregnant female dog. Surgical approach to the abdomen and uterine exposure are the same as for sterilisation with hysterotomy and concurrent SOHE as described above. The vascular pedicle containing the ovarian artery and vein is exposed on both sides, but no forceps are placed. Likewise, the broad ligaments are broken down to the level of the cervix. Any fetus in the pelvic canal is gently manipulated back into the uterine body. Once all relevant structures are exposed, double forceps are placed across each ovarian pedicle and the body of the uterus just cranial to the cervix. The ovaries and uterus are immediately removed by dividing between the forceps and given to a team of assistants. The assistants then quickly open the uterus and remove and resuscitate the neonates. Ligation of the ovarian pedicle and uterine remnant is then completed.

En bloc SOHE has been reported to provide equal safety to both the bitch and fetuses if done correctly (Robbins & Mullen, 1994). The key to success is speed. In a single reported study, the mean time from forceps placement to delivery was 40 seconds (range 30 to 60 seconds), so a maximum time of 60 seconds is recommended (Robbins & Mullen, 1994). This method is likely most appropriate in situations where the uterus is severely diseased, infectious material is suspected to be present or when the litter is known to be dead. En bloc SOHE is not recommended if the fetuses are already bradycardic, and hypoxia is a major concern.

**2.1.1.1.7 | Prevention and treatment of complications associated with ovariectomy, subtotal ovariohysterectomy and ovariohysterectomy:** Surgical sterilisation of female dogs is a major abdominal procedure and should be treated as such. In most instances, sterilisation is performed on an elective basis, so any complication becomes more relevant. The incidence of perioperative complications in dogs is 7.5 to 20.6%, with increasing likelihood in heavier patients (Adin, 2011; Burrow et al., 2005; Fransson, 2017; Muraro & White, 2014). The great majority of complications are directly or indirectly caused by inadequate exposure, so keyhole abdominal incisions should be avoided. With increased experience smaller incisions are possible, but the incision should always be of adequate length to safely perform the procedure.

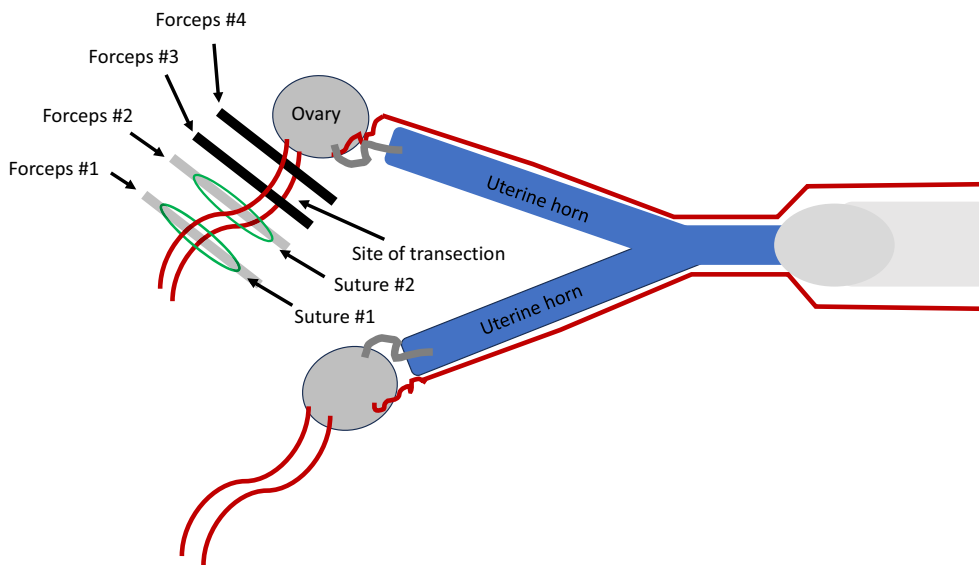
Haemorrhage either during or immediately after surgery is the most common complication reported and may occur from either the ovarian pedicle, broad ligament or uterine arteries (Fig 26). Ovarian pedicle bleeding is generally caused by overaggressive manipulation of vascular structures during attempts to gain visualisation, or poor ligation technique. Visualisation is improved by either blunt or sharp transection of the suspensory ligament. This manoeuvre should be performed as close to diaphragm as possible to avoid inadvertent damage to ovarian vessels. For traction, forceps can be placed on the proper ligament and used as a handle. Forceps placed on the ovarian pedicle may be rolled 90° in either direction to assist ligature placement but should never be directly elevated, or tearing of delicate tissue and vessels is likely.

Placement of two ligatures using a three forceps technique is frequently recommended for ligation of the ovarian pedicle, but when using this method, care must be taken to assure that the most dorsal (away from the ovary) ligature is an adequate distance from the most dorsal forceps. If less than 2 to 3 mm of tissue is allowed, the forceps will keep the tissues from tightening and complete vessel attenuation is prevented. If this situation appears likely to occur, it is better to use a four-forceps method where a ligature is placed in each of the two most dorsal forceps crushes (Fig 27). Surgeon's knots can bind or "lock-up" on the first throw resisting further tightening. This creates a dangerous situation in which the surgeon falsely thinks the knot has been tightly applied but it has not (Smeak, 2019). More dependable ligation is achieved using two pass friction knots such as the miller's, modified miller's, strangle or constrictor knot (Figs 7 and 8) on the first throw, and these are recommended especially in situations with very large or fatty pedicles. Haemorrhage can also occur during pedicle ligation if the defect in the mesovarium is made too cranial. Subsequently, any ovarian or uterine vessels caudal to the defect will be inadvertently transected without ligation.



**FIG 26. Haemoabdomen after surgical sterilisation in a bitch. Bruising and abdominal seepage of blood are apparent**





**FIG 27. Four forceps method for ligation of the ovarian pedicle. Four forceps are placed, and ligatures placed in the crushes of the two most dorsal forceps**

Each ovarian pedicle should be evaluated carefully after ligatures have been placed and the pedicle transected, recognising that crushed tissue may not bleed even if the ligatures are loose. The simple process of tissue elevation may also mask bleeding, so it is important to watch the pedicle closely as it is released and retracts back into the abdomen.

Excessive bleeding from the broad ligament is less common, but may occur in large, overweight or multiparous female dogs. While simple retraction and digital disruption of this tissue is often utilised, ligation of larger vessels is recommended.

Uterine artery bleeding is usually caused by slippage of circumferential ligatures, so except in very small uteri, at least one transfixation suture is recommended. Transfixation can be accomplished with either a traditional or modified method. In the traditional method, a bite is taken through tissue encompassing the vessel and tightened with the first half of a square knot. Both ends of the suture are passed around the structure to the opposite side and tied with a four-throw square knot. The modified method is similar except that a two-throw square knot is placed on the first side (Figs 18 and 19). To help prevent bleeding caused by inadvertent penetration of a vessel, transfixation sutures should always be combined with a simple circumferential suture placed further away from the cut edge. If transfixation is not utilised, two-pass friction knots such as the miller's knot are recommended.

Elective surgical sterilisation should be avoided during oestrus, especially by inexperienced surgeons, as increased vascularity and turgidity of reproductive structures increases the difficulty of obtaining secure ligations. If surgery is performed during oestrus, the use of a vessel fusion device greatly simplifies the procedure and improves safety. Owners of female dogs sterilised during oestrus with ligations at the level of the cervix or cranial vagina (OHE) must be cautioned to keep their dog separated from intact male dogs, as breeding may perforate the healing tissue and cause peritonitis. If sterilisation is delayed because of oestrus, surgery should not be performed for 2 months or at least until serum progesterone concentration has dropped to  $<2.0$  ng/mL, as female dogs will lactate if surgery is performed during this progesterone-dominated period.

If excessive bleeding is noted before closure, the incision should immediately be enlarged to allow complete evaluation of all potential sites. Attempts to assess and mitigate excessive haemorrhage without adequate exposure generally fail and increase the risk of inadvertent damage to other structures. Having a second surgeon scrub in as an assistant to aid retraction is recommended, and the availability of surgical suction with an attached tip designed for this situation is helpful. Either a Poole or Yankauer suction tip is appropriate (Figs 28 and 29). If bleeding is identified at one site, all sites should still be examined as multiple sources of haemorrhage are possible. Both ovarian pedicles are located caudal to their respective kidney and are exposed by retracting the colon towards the midline on the left and descending duodenum towards the midline on the right. This manoeuvre allows their respective mesenteries to act as a sling and displace abdominal viscera. The uterine vessels at the cervix are exposed by retroflexing the urinary bladder caudally and ventrally. Once the sites of bleeding are identified additional ligatures are placed. Vascular clips are particularly useful in this situation as they provide secure ligations while requiring less elevation of affected vessels (Fig 10).

Bleeding not detected and remedied at surgery will result in delayed haemoabdomen. Patients recover poorly, have pale mucous membranes and are tachycardic. Diagnosis is confirmed with serial determination of packed cell volume, abdominocentesis and/or abdominal ultrasound. If progressive haemoabdomen occurs, emergency exploratory laparotomy is required, with identification and management of affected vessels as described above.

Intermittent mild vaginal bleeding may occur for days to weeks after surgery, but more severe bleeding is typically caused by suture-associated erosion of a uterine vessel. Treatment generally requires revision surgery and ligation of the bleeding vessel.



**FIG 28. Poole suction tip.** The Poole suction tip has a central solid tube contained within a fenestrated sheath to prevent obstruction by abdominal viscera. It is particularly useful for evacuating pooled blood or other abdominal fluids

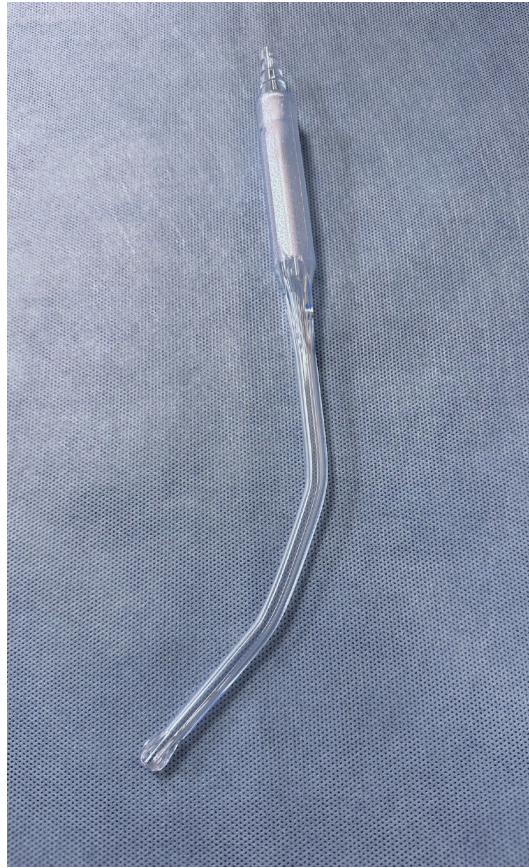Granulomas at the site of ovarian pedicle ligation are usually caused using braided non-absorbable suture material, often supplied in a cassette. They have also been reported after the use of non-implant grade commercially available cable ties (Werner et al., 1992) (Fig 9). Once a granuloma has formed it may cause a secondary fistulous tract, which generally ruptures in the flank area. The use of braided non-absorbable suture material or non-surgical grade implants of any type should be avoided. Treatment requires removal of causative material, re-ligation of ovarian vessels if needed and excision of the fistulous tract.

Inadvertent ligation or transection of one or both ureters is a severe potential complication of surgical sterilisation of female dogs (Plater & Lipscomb, 2020) (Fig 30). The true incidence of this complication is unknown because with unilateral ligation, some animals may never develop clinical signs. Ligation can occur either proximally at the level of the ovarian pedicle or distally at the uterine body. Distal ligation is most common and is generally associated with failure to empty the urinary bladder before surgery. If there is any distension of the bladder noted at surgery, it should be emptied by manual expression or cystocentesis.

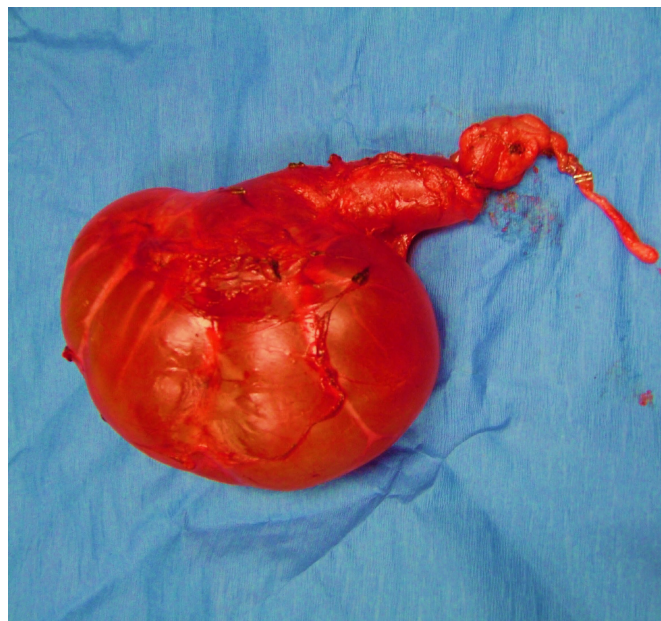
If inadvertent ureter ligation is noted at surgery, the offending suture can sometimes be gently cut free using magnification. Ureter ligation detected shortly after surgery is generally manifest by clinical signs of hydroureter, hydronephrosis and acute renal failure. In this situation, emergency laparotomy is indicated to remove the suture and stent the affected site if possible. Studies indicate that normal kidney function will return if complete obstruction is alleviated after 4 days, whereas 46% of glomerular filtration rate and tubular function return after 14 days and none after 40 days (Fink et al., 1980; Hardie & Kyles, 2004; Vaughan Jr. & Gillenwater, 1971; Vaughan Jr. et al., 1973). If removal is impossible or the ureter has been transected, resection and anastomosis can be attempted, or if the injury is very distal the intact proximal ureter can be anastomosed to the urinary bladder (Hardie & Kyles, 2004). If the ipsilateral kidney is functional, but the ureter irreparably damaged, a subcutaneous ureteral bypass system may be used to divert urine from the kidney to the urinary bladder. Patients with chronic ureter ligation do not have a functional ipsilateral urinary tract, so unilateral ureteronephrectomy is required.

ORS is caused by the presence of residual functional ovarian tissue after gonadectomy. Residual ovarian tissue produces endogenous hormones, resulting in clinical signs of oestrus in a presumably spayed animal. This syndrome has been associated with poor visibility of the ovarian pedicles, friable ovarian tissue, improper placement of ligatures or forceps and the use of keyhole incisions (DeNardo et al., 2001; Kustritz & Rudolph, 2001; McEntee, 1990; Miller, 1995; Wallace, 1991). Most ovarian remnants are associ-



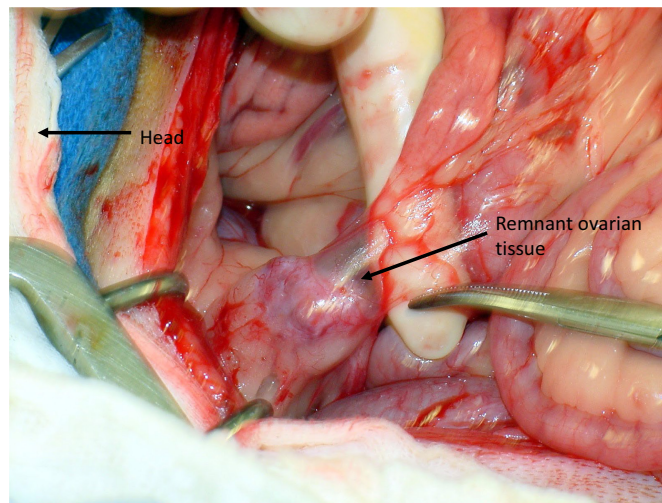


**FIG 29. Yankauer suction tip.** The Yankauer suction tip has a large opening surrounded by a bulbous head to allow effective removal of fluid without damaging surrounding tissue

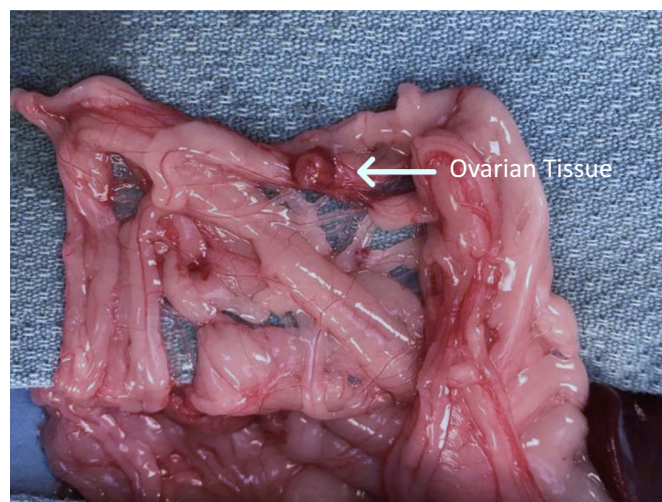


**FIG 30. Ureter ligation.** Inadvertent ligation of the ureter during surgical sterilisation has caused severe renal hydronephrosis

ated with residual tissue located at or near an ovarian pedicle. The right side is reported more frequently, likely because of the more cranially located and difficult to expose location (Ball et al., 2010; Fontes & McCarthy, 2020; Muraro & White, 2014) (Fig 31). Remnant ovarian tissue has also been reported free in the abdominal cavity, likely caused by fragmentation of the ovary at surgery



**FIG 31. Ovarian remnant syndrome. Remnant ovarian tissue noted at exploratory laparotomy for persistent signs of oestrus after surgical sterilisation**

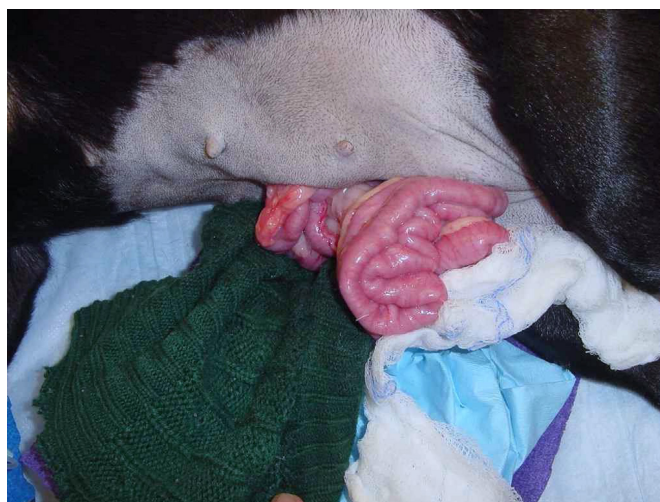


**FIG 32. Ovarian remnant syndrome. Ovarian tissue free in the abdomen. This patient had multiple previous laparotomies without identification of remnant tissue**

(Fontes & McCarthy, 2020) (Fig 32). The recommended treatment for ORS is surgical removal of the remnant tissue. Ovarian remnants are more easily visible when active structures are present as both mature preovulatory follicles and/or mature corpora lutea cause the ovarian remnant to stand out against the abdominal viscera background. Therefore, surgery should be performed while the animal is either in oestrus or in dioestrus. Exploratory laparotomy or laparoscopy should focus on the ovarian pedicles, but the entire abdominal cavity should be examined carefully. All suspected tissue should be excised and submitted for histologic examination.

Other reported complications of surgical sterilisation are typical of all abdominal surgeries, including incisional dehiscence (Fig 33), seroma and wound infection. It is often recommended that concomitant dental scaling be avoided with other surgical procedures as bacteraemia is a frequent sequela and organisms may secondarily colonise the surgical site (Nieves et al., 1997). To our knowledge, no direct association has been established between dental scaling and increased risk of surgical infection after any surgical sterilisation procedure. Performing concomitant dental scaling should be avoided, if possible, but such factors as current significance of the dental disease to patient health, quality of life, advisability of having multiple anaesthetic episodes and owner financial concerns should also be considered. If concomitant dental scaling is performed, appropriate systemic antimicrobial prophylaxis and oral antiseptic rinse will decrease bacteraemia and should be provided (Bowersock et al., 2000).





**FIG 33. Bowel evisceration after incisional dehiscence**

## 2.1.2 | Female cats

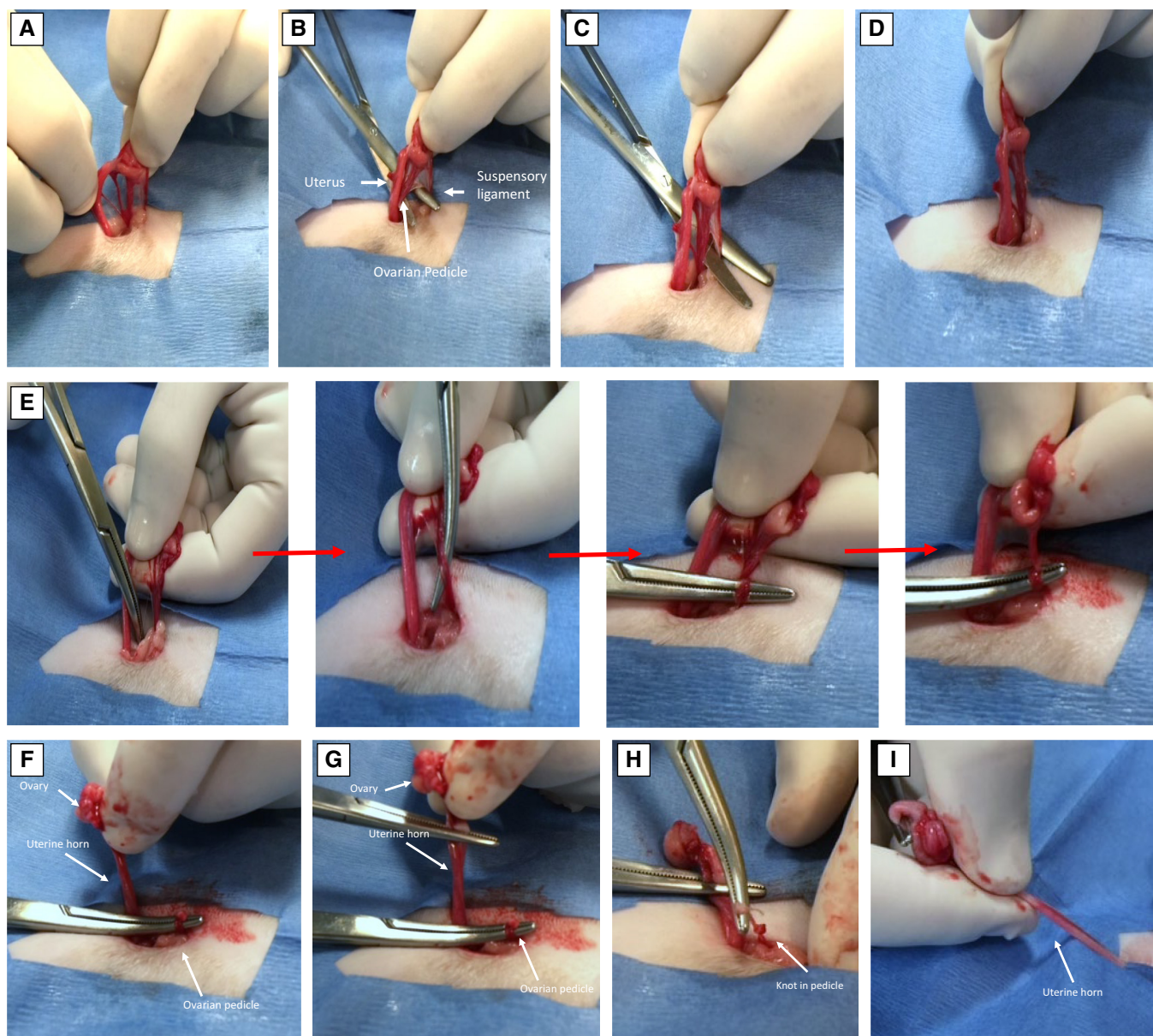
**2.1.2.1 | Ovariectomy, subtotal ovariectomy and ovariectomy:** As with dogs, cats can be surgically sterilised with removal of the ovaries alone (OE), or with concomitant partial (SOHE) or complete (OHE) removal of the uterus. The cervix is poorly differentiated from the uterine body in cats so differentiating between the latter two procedures at surgery is sometimes impossible. Each of the methods except OHE can be performed utilising a ventral midline or flank laparotomy. The flank approach does not allow adequate visualisation for complete removal of the entire uterus. Evidence is conflicting, but there is likely little clinically significant difference with regard to postoperative pain and wound complications between the two approaches (Coe et al., 2006; Grint et al., 2006; Swaffield et al., 2019). Laparoscopic sterilisation can be performed in cats but is rarely indicated or recommended due to small patient size and minimal invasiveness of a laparotomy in these patients.

Some method of easy external identification of sterilisation status should be provided (Griffin et al., 2016, 2020). Tattoo location and methods of application for owned indoor cats are the same as previously described for dogs. Sterilisation of community and feral cats should always be confirmed by ear tipping. Most sterilisation programmes in the USA recommend tipping the left ear, but some organisations remove the right tip or perform the procedure on one side or the other based on the sex of the cat (Dalrymple et al., 2022; Griffin et al., 2020). Consistency across programmes would be desirable. Regardless of side, enough of the ear tip should be removed to allow easy visualisation from a distance. Ear notching is not recommended because torn ear flaps are a frequent occurrence in free roaming cats and are easily mistaken for surgically notched ears. In cold climates, frostbitten ear tips may appear cropped but can often be differentiated because of their thickened irregular border (Griffin et al., 2020).

The precise method of ear tipping can vary based on surgeon preference but in most clinical situations would be considered a contaminated procedure. Clipping is optional and some surgeons feel should be avoided due to risk of causing pinna abrasions (Griffin et al., 2020). An antiseptic solution such as chlorhexidine or betadine is used to remove any gross debris and decrease bacterial load. In one common method (Griffin et al., 2020) a large straight haemostat such as a Carmalt forceps is placed across the pinna perpendicular to its long axis, exposing about one-third of the ear tip. Straight haemostats rather than curved are recommended so that the subsequent resection provides a distinctive straight edge that does not resemble normal ear curvature. Surgical scissors are then used to excise the distal ear tip by cutting along the edge of the instrument. The most common complication of clinical significance is excessive or delayed bleeding, reported in about 5% of cases (Dalrymple et al., 2022). Leaving the forceps in place for several minutes after resection (*e.g.* during a subsequent surgical sterilisation) and/or application of a cauterising agent such as silver nitrate to the cut surface will aid with haemostasis.

Unlike in the female dog, elective surgical sterilisation may be performed during oestrus as the extent of increase in vascularity and turgidity of feline reproductive structures is of no clinical significance.

**2.1.2.1.1 | Ventral midline laparotomy for ovariectomy in cats:** Location of the initial skin incision is often calculated by dividing the distance between the umbilicus and pubis into thirds and making the incision the length of the cranial third. The length of the incision depends on the cat's size, amount of abdominal fat and surgical experience of the operator. The incision should not be longer than needed but should always allow adequate exposure to safely perform the procedure. All other aspects of the laparotomy, identification and exteriorization of the uterine horns and ovaries are the same as for dogs. If using a spay hook it is common to inadvertently hook the fat pad that lies lateral to the bladder. The uterine horn in the cat resides just cranial to this structure. If the fat pad is exteriorized it is grasped and the spay hook directed just cranial to engage the uterine horn (Valdez, 2022).



**FIG 34. Auto-ligation of the ovarian pedicle in a cat. (A) Ovarian pedicle isolated. (B) Separate suspensory ligament from the pedicle. (C) Cut the suspensory ligament. (D) Vessels separated from uterine horn. (E) Single overhand throw placed in the pedicle and clamped. (F) Pedicle cut. (G) Uterine horn clamped. (H) Pedicle knot completed by pulling over the top of the haemostat. (I) Follow uterine horn to opposite side and repeat. (Images from Dr. April Paul)**

For pedicle ligation a single forceps is placed across the proper ligament and proximal uterine horn for manipulation. If needed for adequate visualisation, the suspensory ligament is cut, digitally broken or stretched. Many surgeons prefer to ligate the ovarian pedicle in cats without the use of forceps. In this method, a single ligature is placed around the ovarian pedicle and the ovarian pedicle transected between the ligature and the ovary. The two forceps method described previously for dogs can also be utilised, using mosquito forceps rather than the larger Kelly, Crile or Carmalt forceps recommended for canine patients.

A recently described method for pedicle ligation in cats is auto-ligation (Fig 34). After gaining experience with the technique, auto-ligation is quicker, safe and avoids the necessity of using suture (Rigdon-Brestle et al., 2022). This method is easier in larger cats, and the procedure should not be done in kittens until the surgeon is comfortable with larger patients (Valdez, 2022). To perform auto-ligation the ovarian pedicle is first fanned out and the suspensory ligament cut. A window is made in the mesovarium between the ovarian vessels and uterine artery and a single overhand throw is started in the pedicle with a needle driver. After placing the first half of the throw, the jaw of the needle driver is clamped. The uterus and uterine artery are then clamped at the level of the proper ligament to provide haemostasis. Finally, the pedicle is transected between the knot and ovary, and the overhand throw is completed by pushing the knot over the tip of the needle driver. For added safety some surgeons prefer to clamp the ovarian pedicle with a



mosquito forceps on the opposite side of the needle driver from the ovary before transecting the pedicle. This forceps is released once secure pedicle ligation is confirmed.

Once the pedicle is transected, a single suture is passed around the junction of the uterine tube and horn and tied. Two forceps are then placed between the ligature and ovary. Cutting between these forceps will free the ovary, which can be removed from the surgery site (Fig 6). The procedure is then repeated on the opposite side.

**2.1.2.1.2 | Ventral midline laparotomy for subtotal ovariectomy and ovariectomy in cats:** Location of the surgical incision for ventral midline laparotomy is slightly more caudal than for OE, often centred midway between the umbilicus and pubis. All other aspects of the laparotomy, identification of reproductive structures, exteriorisation of the ovaries and methods of pedicle ligation are the same as for OE. The cervix is poorly differentiated from the uterine body in cats so determining how much, if any cervix has been removed at surgery is often impossible. A single circumferential miller's knot is placed as far caudal to the uterine bifurcation as practical, and the tissue transected at least 3 mm cranial to that site. Forceps are generally neither required nor indicated.

**2.1.2.1.3 | Flank laparotomy for ovariectomy and subtotal ovariectomy in cats:** Techniques for both right and left flank laparotomy have been described in cats, but the right is often preferred because it is easier to access the more cranially located right ovary, and because the omentum covers the viscera when approached from the left (Howe, 2006; Krzaczynski, 1974; McGrath et al., 2004; Munif et al., 2022) (Fig 35). For the right flank laparotomy cats are placed in left lateral recumbency and a dorsal to ventral incision made just caudal to the midpoint between the last rib and iliac crest. In most cats, the incision length is about 2 cm. As with dogs, the abdominal wall is entered through a grid approach. The remainder of the surgery is then the same as described for ventral midline laparotomy in cats.

**2.1.2.1.4 | Laparoscopic ovariectomy, subtotal ovariectomy and ovariectomy in cats:** Laparoscopic sterilisation can be performed in cats but is rarely indicated or recommended due to small patient size and lack of evidence for decreased morbidity or better alleviation of pain after surgery (Coisman et al., 2014). Laparoscopic OE is sometimes performed on large cats (lions, tigers) maintained in zoo collections to avoid large incisions and allow early release back into exhibits.

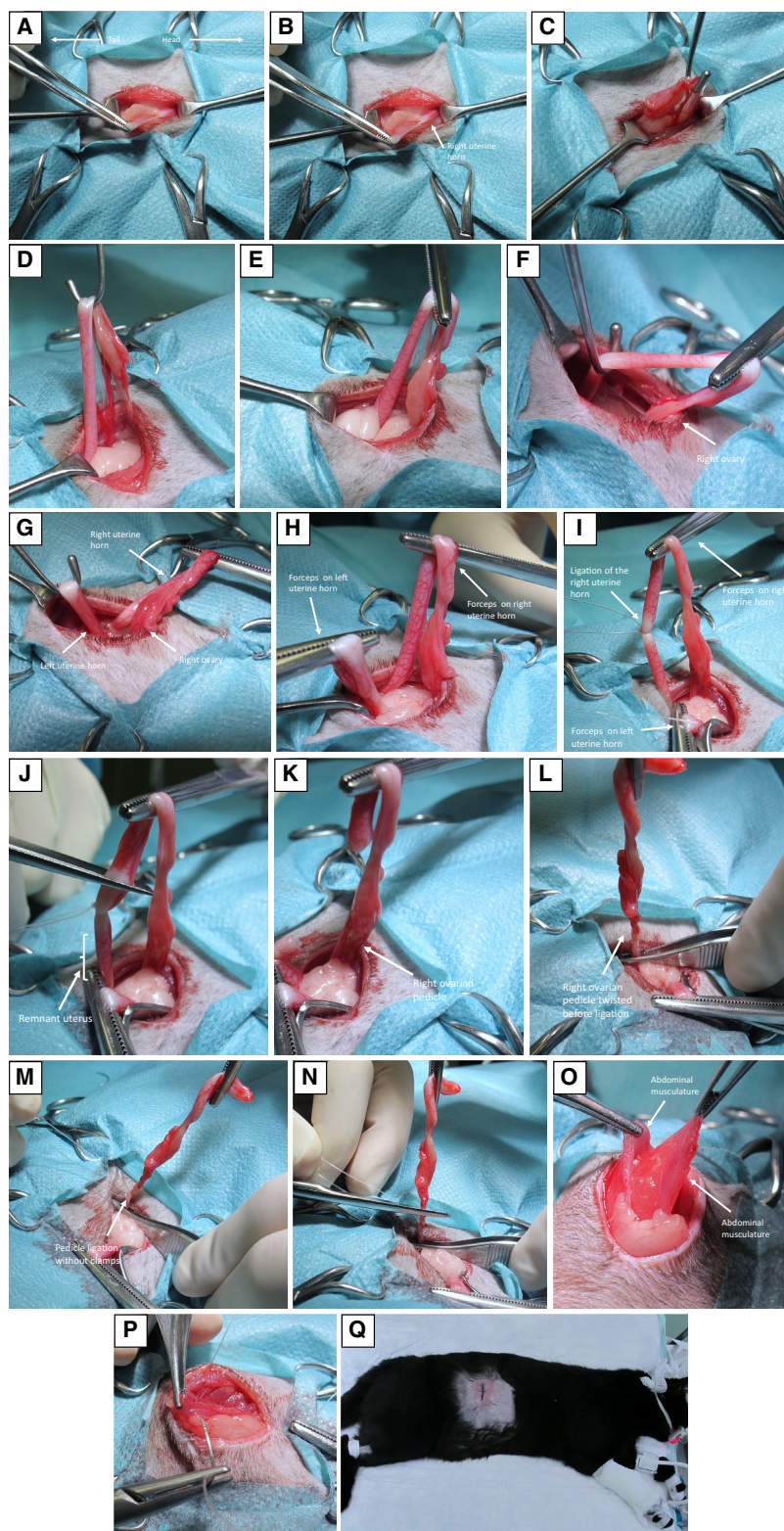
## 2.1.3 | Male dogs

**2.1.3.1 | Orchiectomy in dogs with descended testes:** Orchiectomy in dogs with descended testes can be accomplished with either a prescrotal or scrotal incision. While historically avoided, the scrotal approach is gaining increased popularity, especially in smaller dogs and in high-quality-high-volume-spay-neuter clinics (Brunn, 2022; Woodruff et al., 2015). In addition to incision location, male gonadectomy may be performed with either an open (vaginal tunic opened) or closed (vaginal tunic left intact) method. Bilateral orchiectomy is 100% effective as a sterilisation method. The duration of continued fertility after orchidectomy is debated. While it has been reported that some sperm (<1 million) may remain in the ejaculate for up to 21 days after vasectomy (Pineda et al., 1976; Schiff et al., 2003) to our knowledge there are no reports of pregnancy being established after orchiectomy.

**2.1.3.1.1 | Prescrotal orchiectomy in dogs:** All dogs should be examined carefully before surgery to confirm that both testes are descended into the scrotal sac. The prescrotal and inguinal areas are both clipped and surgically prepped. Clipping the scrotal area is a matter of debate. This area is very fragile and sensitive, especially in older dogs, and clipping can predispose to irritation and subsequent self-mutilation (Fig 36). Some surgeons prefer to simply apply antiseptics to the scrotum and avoid clipping entirely, especially in short haired dogs.

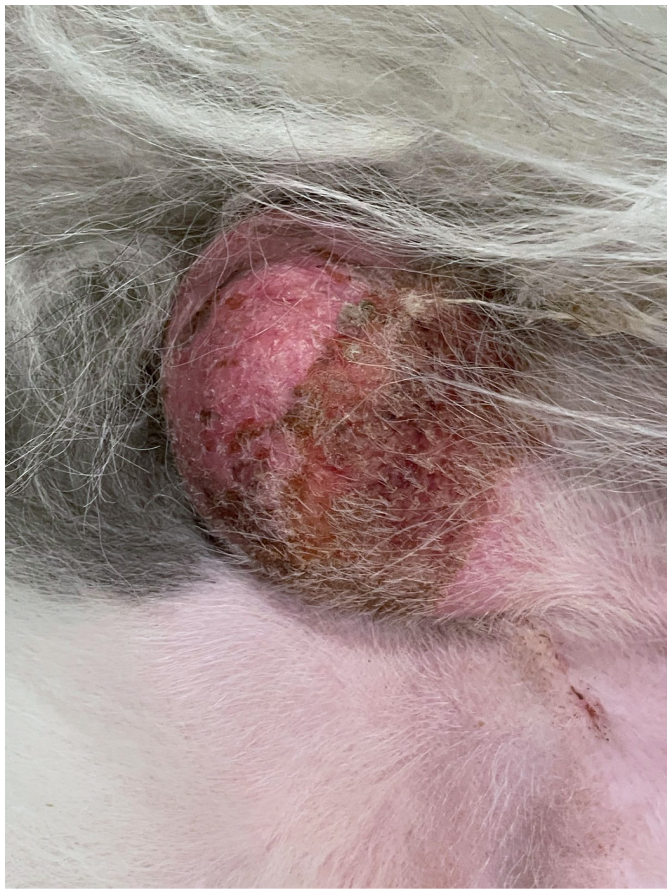
To perform prescrotal orchiectomy dogs are placed in dorsal recumbency and the first testis is pushed forward to the prescrotal area. A single, 2 to 5 cm long incision is then made on midline directly over the advanced testis. This incision needs to be slightly longer than the longitudinal length of the testis being removed. While maintaining the testis in this position, the subcutaneous tissue and spermatic fascia are incised with a scalpel blade. The scrotal ligament is then either incised or broken down digitally. Fascia and fat surrounding the spermatic cord are removed with a gauze sponge. While many surgeons perform this manoeuvre by pushing the relevant tissue into the surgical wound, it is preferable to pull it towards the testis, thus removing any damaged and avascular tissue rather than preserving it.

For open prescrotal orchiectomy, the vaginal tunic is incised longitudinally with a scalpel blade (Fig 37). Care should be taken to avoid incision through the tunica albuginea into the testis itself as unwanted haemorrhage will ensue. Many methods for ligation of the spermatic cord have been described and used with success. Forceps are generally not required at the site of ligature placement, especially in small dogs, but can be used at the surgeon's discretion. Two ligatures of size 0-0 to 3-0 absorbable material tied tightly are adequate. As with the ovarian pedicle, it may be beneficial to use a two-pass friction knot such as a miller's or constrictor knot in this situation. Ligation with surgical clips or a vessel-sealing device can decrease surgical time (Kanca & Yaman, 2022). Once the ligatures are completed two forceps are placed across the spermatic cord, which is then cut between them (Fig 38). In prepubertal gonadectomy (dogs 6 to 14 weeks of age) an alternate method is to first transect the vas deferens near the testis, and then tie the vas to the spermatic vessels with several square knots. The procedure is then repeated on the opposite side.

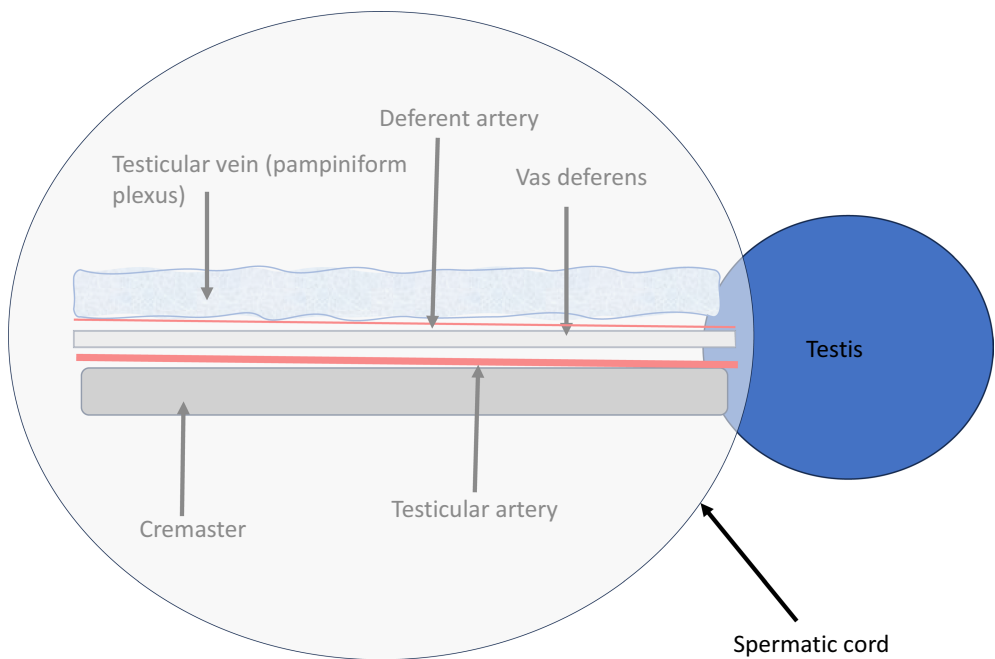


**FIG 35.** Flank subtotal ovariectomy in a cat. (A) Incision in the right flank. (B) Minimal dissection is required to visualise the right uterine horn. (C) Right uterine horn gently elevated to visualise the right ovary. (D) Further elevation uterine horn. (E) Uterine horn grasped and clamped. (F) Uterine horn followed caudally. (G) Continued retraction allows identification of the uterine bifurcation and left uterine horn. (H) Left uterine horn temporarily clamped. (I) Right uterine horn ligated routinely. (J) Right uterine horn transected. Note that a large amount of uterine horn is retained in this patient. The uterus can be removed to the level of the uterine body if desired. (K) Right ovarian pedicle exposed. (L) Right ovarian pedicle has been twisted before ligation. (M) Routine ligation right ovarian pedicle. (N) Right ovarian pedicle transected and released. (O) Process repeated on opposite side and closure begins with identification of the deep abdominal muscles. (P) Abdominal wall closure. (Q) Final closure can utilise an intradermal pattern or skin sutures (Images from Dr. S. Schäfer-Somi)



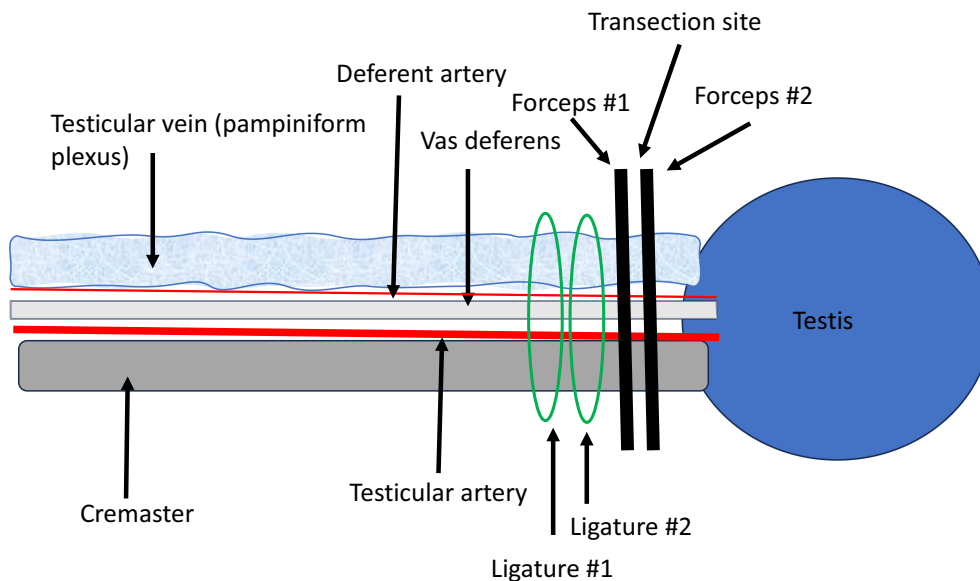


**FIG 36. Severe scrotal irritation after clipping for orchietomy**

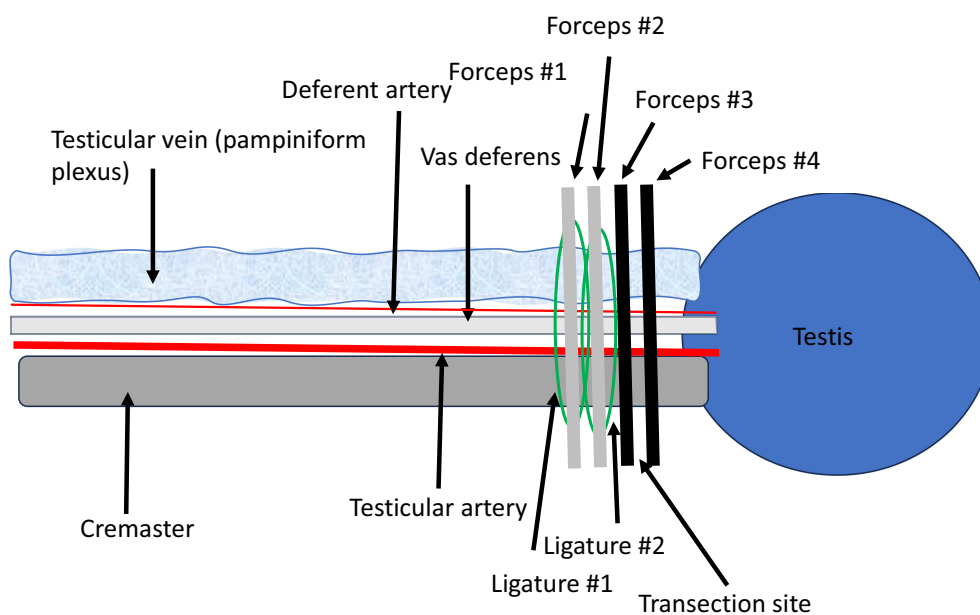


**FIG 37. Major structures contained within the spermatic cord**





**FIG 38.** Typical method for ligation and transection of the spermatic cord in a dog. Two ligatures are placed first. Forceps are placed caudal to the ligatures and transected between them allowing for removal of the testis



**FIG 39.** Alternative method for ligation and transection of the spermatic cord in a dog. Four forceps are placed first. A ligature is placed in the crush of each of the two most cranial forceps and then the cord is transected between the two most caudal forceps. Some surgeons prefer to transfix one of the ligatures to the cremaster muscle or use at least a single two-pass friction knot

For closed prescrotal orchiectomy the vaginal tunic is not incised. Because the vascular structures are separated from direct contact with the ligatures, some surgeons prefer placing these ligatures in sites that have been pre-crushed with forceps (Fig 39). Knot configurations such as the miller's knot are particularly appropriate. Transfixation of one of the two ligatures to the cremaster muscle will also aid in preventing slippage. In prepubertal gonadectomy the structures are very small, and auto-ligation of the cord can be performed as described below for male cats.

Closure with either open or closed prescrotal orchiectomy is generally with 3-0 or 4-0 absorbable suture material in the subcutaneous tissue and 3-0 or 4-0 absorbable suture material placed in an intradermal pattern. Using a back-and-forth pattern, a single strand of suture can be used for both layers and knotted at one end (Valdez, 2022). Skin sutures should be avoided, as dogs have a high propensity for licking at them if placed in this area. Skin glue can be placed if needed. Placement of a scrotal implant for cosmetic purposes is not recommended due to increased risk of infection and other complications after surgery as well as ethical concerns (see Chapter 6).

**2.1.3.1.2 | Prevention and treatment of complications associated with prescrotal orchiectomy in dogs:** Excessive haemorrhage is by far the most frequent complication of prescrotal gonadectomy in dogs (Adin, 2011). Bleeding is usually from the vaginal tunic or small subcutaneous vessels, causing peri-incisional bruising and scrotal haematoma. A more severe situation results when bleeding originates from testicular vessels, causing haemoabdomen.

Bruising and scrotal hematoma appear to be more common when the open method of orchiectomy is used (Hamilton et al., 2014; Hedlund, 2002) so the closed method is recommended when possible. Any bleeding within the subcutaneous tissues should be addressed before closure. Scrotal haematoma requires passage of blood into the scrotal sac, so it cannot occur if the openings into the scrotal sacs created during surgery are closed carefully. Scrotal ablation is recommended in giant breed dogs where the large amount of dead space and increased local vasculature may predispose to this problem. Incisional bruising and mild scrotal haematoma will generally resolve with cryotherapy and exercise restriction. More severe scrotal haematoma requires scrotal ablation.

Bleeding from testicular vessels is caused by inadequate ligation and is generally not detected during surgery. Retraction of the affected vessels causes post-operative haemoabdomen, often with no associated external signs of bleeding. Patients recover poorly, have pale mucous membranes and are tachycardic. Diagnosis is confirmed with serial determination of packed cell volume, abdominocentesis and/or abdominal ultrasound. If progressive haemoabdomen is detected, emergency exploratory laparotomy is required. To prevent this complication, the cut surface of the spermatic cord should be carefully visualised after transection, recognising that if forceps were used the crushed tissue may not bleed even if ligatures are inadequate. All tension should be eliminated before evaluation, as tension alone may also obscure haemorrhage. Many different methods of ligation are acceptable provided the surgeon has comfort and experience with the technique. The open method of orchiectomy has been recommended for large and giant breed dogs because direct vessel contact is theoretically more secure, but no data supports this, and the closed method is acceptable provided secure ligatures can be achieved. Surgeon's knots can bind or "lock-up" prematurely, creating a dangerous situation in which the surgeon falsely thinks the knot has been tightly applied when it is not (Smeak, 2019). More dependable ligation is achieved using two pass friction knots such as the miller's, modified miller's, strangle or constrictor knot on the first throw (Figs 7 and 8).

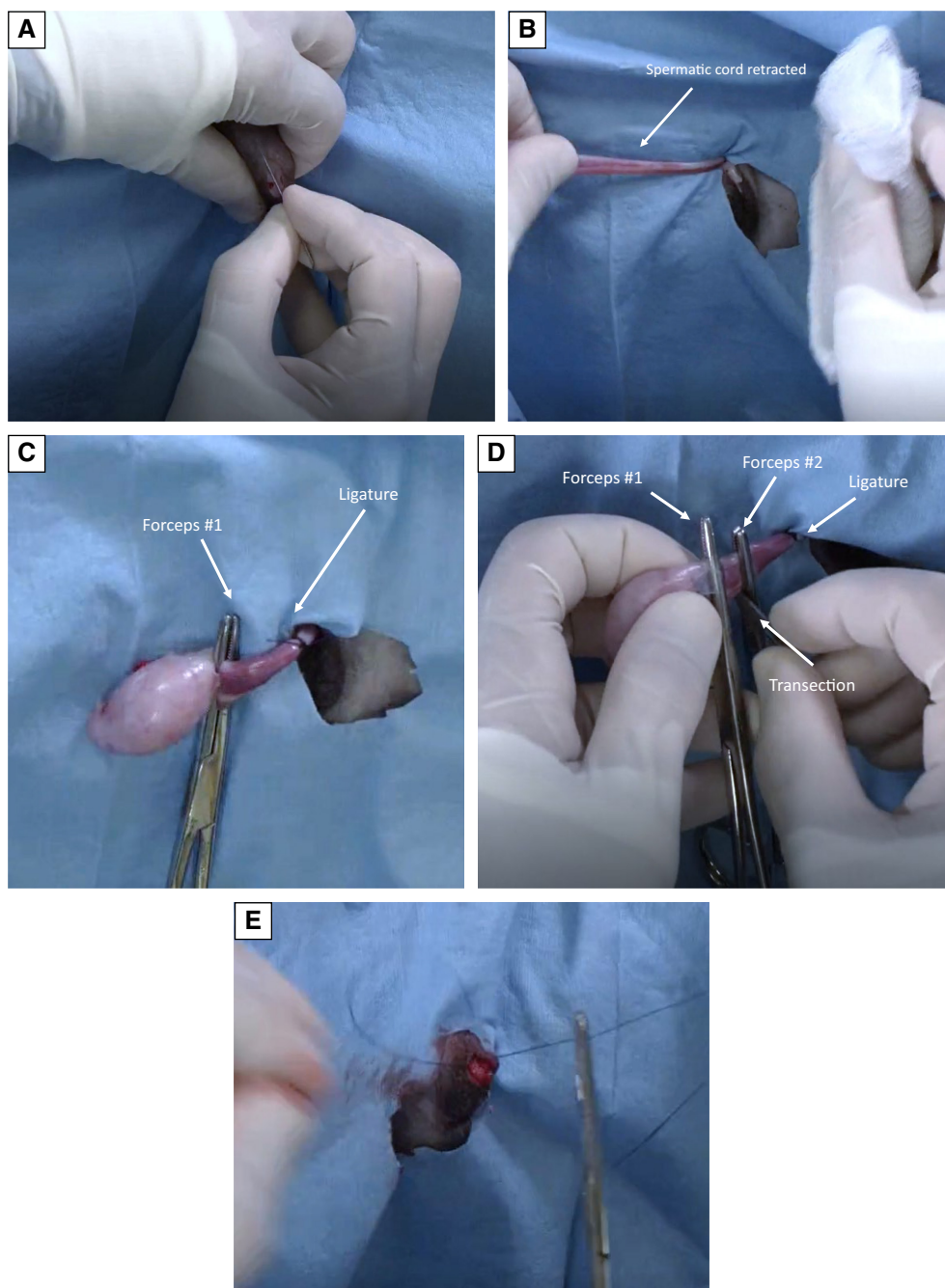
**2.1.3.1.3 | Scrotal orchiectomy in dogs:** Other than the location of the incision and closure, the surgical procedure and open *versus* closed options are the same for scrotal orchiectomy as with the prescrotal approach (Miller et al., 2018) (Fig 40). In addition, a suture-less scrotal technique can be utilised in paediatric and small dogs. In this method, each testis is individually exteriorized with gentle traction to break down fibrous attachments between the testes and scrotum. A haemostat is then directed parallel to the spermatic cord, pointed in a proximal direction and twisted to form a simple overhand knot. Finally, the spermatic cord is cut distal to the haemostat and the cut end slipped over the end to complete the knot (Miller et al., 2018). Deep tissues are either not closed or apposed with one to two simple interrupted buried absorbable sutures. The skin is closed with either skin glue or allowed to heal by second intention. Scrotal orchiectomy has been associated with less self-inflicted post-surgical trauma and decreased surgery times in small (0.9 to 11.4 kg) paediatric and juvenile dogs (Miller et al., 2018; Woodruff et al., 2015).

**2.1.3.1.4 | Orchiectomy in dogs with scrotal ablation:** Orchiectomy with scrotal ablation is required in situations where scrotal skin is damaged, and often recommended for giant breed dogs, where the large amount of potential dead space and increased scrotal vasculature may predispose to development of scrotal haematoma with other methods. Alternatively, owners may request this method for cosmetic reasons.

To perform scrotal ablation an elliptical incision is made around the base of the scrotum and subcutaneous tissue dissected circumferentially to isolate both spermatic cords. This incision should be close to the scrotum to provide adequate skin for subsequent closure without tension. The surgical procedure, including open *versus* closed options is then the same as for orchiectomy with other surgical approaches. The surgical wound is closed in three layers. A simple continuous or interrupted pattern is used to close the dead space and relieve tension, followed by a simple continuous pattern in the subcutaneous tissue and a buried intradermal pattern in the skin. Skin glue can be added if needed, but skin sutures should be avoided to prevent irritation and licking by the patient (Fig 41).

**2.1.3.2 | Orchiectomy in dogs with cryptorchid testes:** Although normal testicular descent in dogs should be complete by about 10 days after birth, it is recommended to wait until 6 months of age before declaring a dog cryptorchid, as this is when the inguinal ring completely closes (Johnston, Kustritz, & Olson, 2001a). Cryptorchid testes are at increased risk of becoming neoplastic so they should always be removed (Hayes et al., 1985; Pendergrass & Hays, 1975).

Unilateral cryptorchids are assumed to be fertile and since cryptorchidism is often a genetically linked trait, affected dogs should not be bred (Romagnoli, 1991). Considering potential health risks associated with loss of gonadal hormones, the descended (scrotal) testis may be maintained in situ provided that a recommendation is made not to breed. Otherwise, complete gonadectomy or vasectomy should be advised.

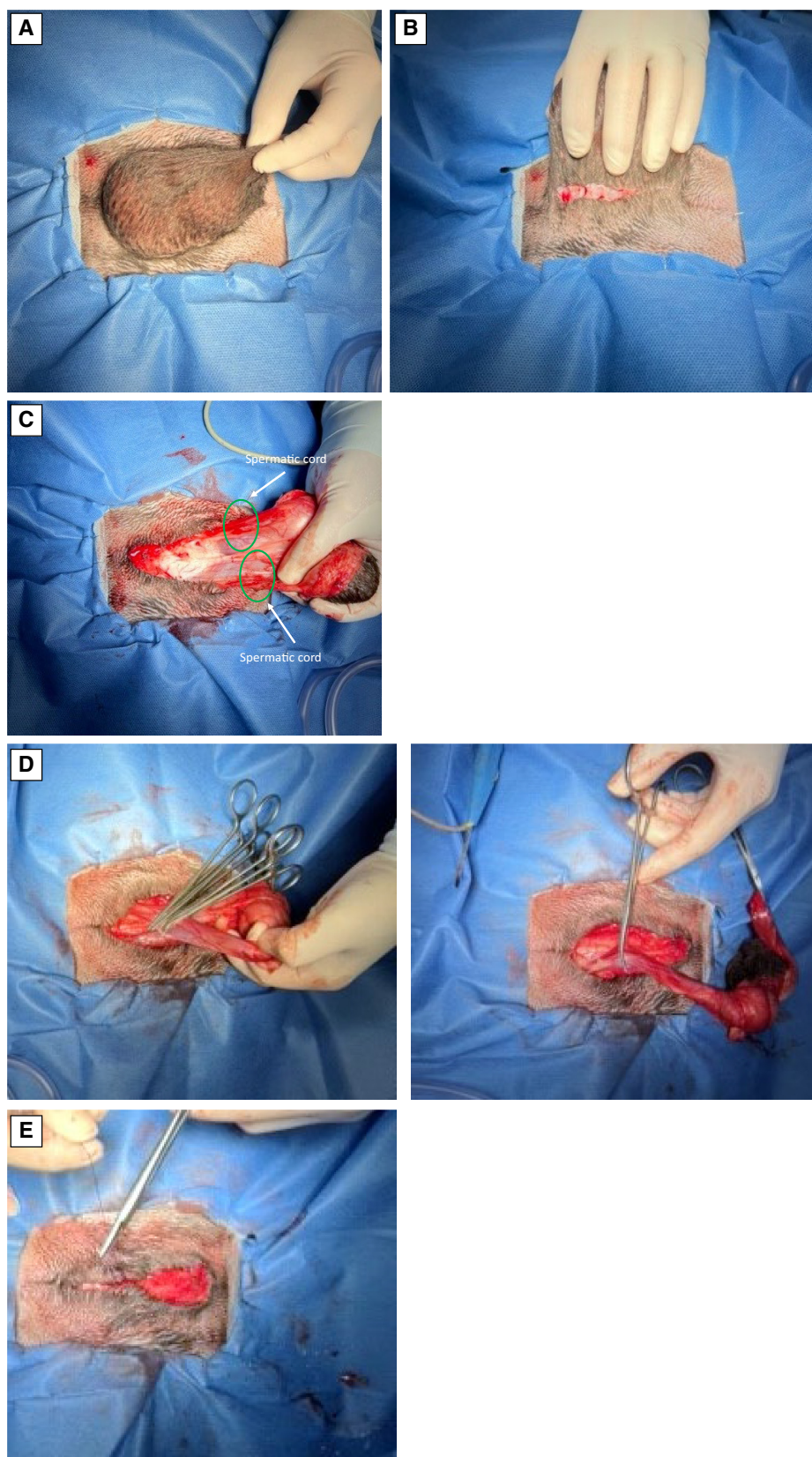


**FIG 40. Scrotal orchiectomy in a dog. (A) Incision made directly over the testis. (B) Testis retracted, and spermatic cord exposed. (C) First forceps placed and a single circumferential ligature tied. (D) Second forceps placed and spermatic cord transected between the forceps. (E) The incision can be closed with a single interrupted buried suture or left open (Images from Dr. April Paul)**

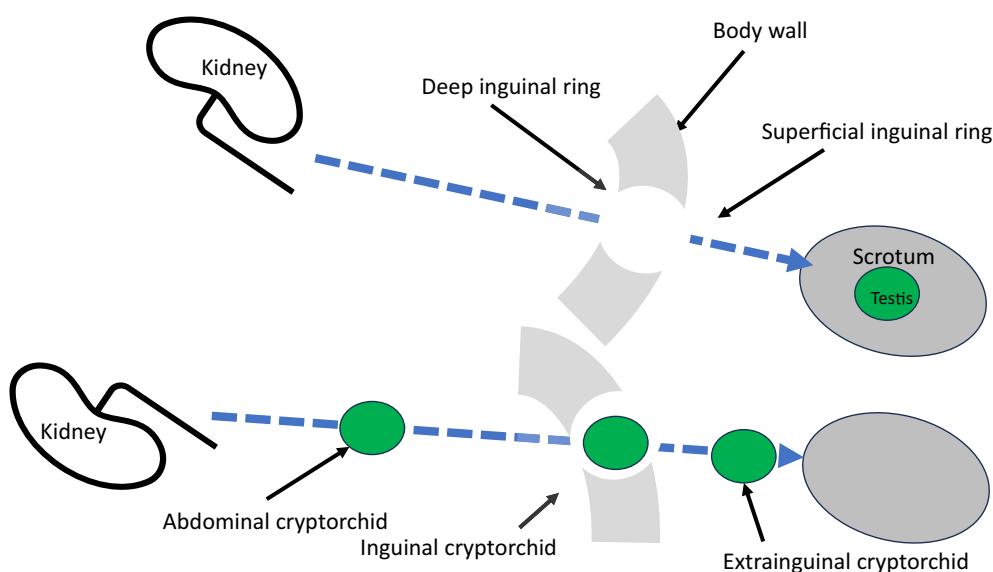
If the descended testis is preserved, owners should be informed about the potential for increased risk of neoplasia in this testis. In humans, the descended testis of a unilateral cryptorchid male has been estimated to have a 3.6 times increased risk of becoming neoplastic (Prener et al., 1996). Studies in dogs are limited, but while morphologic changes have not been confirmed, immunohistochemical markers suggestive of potential for future malignant transformation are elevated in the descended testis (Pecile et al., 2021; Veronesi et al., 2009). Regular palpation of the descended testis is critical if it is preserved.

In cases of unilateral cryptorchidism determination of the affected side is useful for surgical planning and this can be accomplished by pushing the descended testis forward and determining which inguinal ring it is directed towards, and/or by preoperative abdominal ultrasound. If one testis remains in the scrotal sac, it should always be left in situ unless the cryptorchid testis is removed so there is no confusion later regarding sterilisation status. Cryptorchid testes may be located anywhere along the normal path of

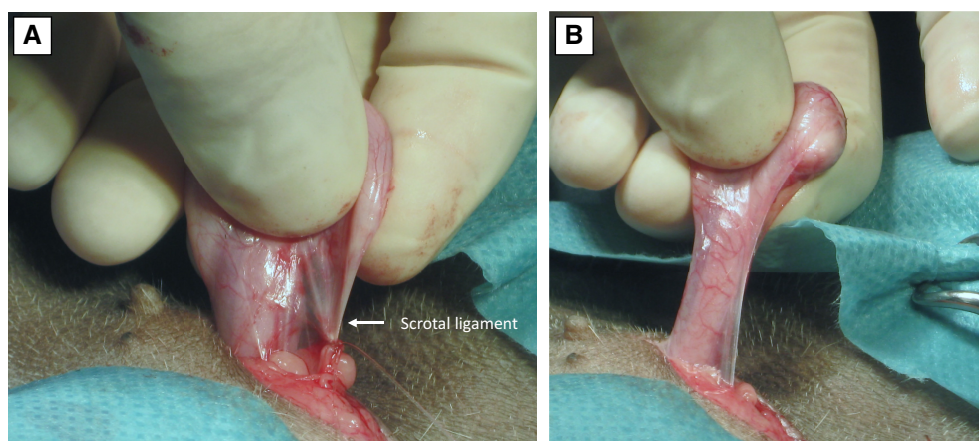




**FIG 41. Orchiectomy with scrotal ablation. (A) Scrotum after surgical preparation. (B) Scrotum and testes elevated and elliptical incision around base is begun. (C) Isolation of both spermatic cords. (D) Routine orchiectomy bilateral. (E) Elimination of dead space and intradermal skin closure**



**FIG 42. Normal testicular descent and forms of abnormal testicular descent**



**FIG 43. Extra-inguinal cryptorchid testis. (A) Incision is made directly over the palpable testis. The scrotal ligament can be broken down digitally or ligated as necessary to improve exposure. (B) Once exposed, routine open or closed orchiectomy is performed (Photos from Dr. S. Schäfer-Somi)**

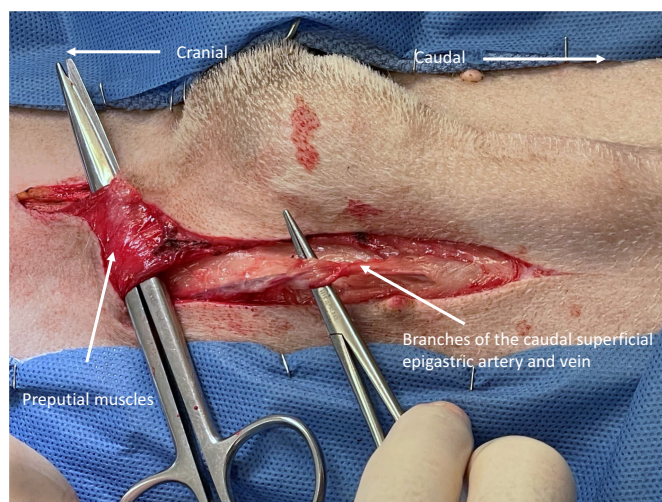
descent between the caudal pole of the kidney and scrotal sac and are classified and treated accordingly. Extra-inguinal cryptorchid testes are located between the superficial inguinal ring and scrotal sac, inguinal cryptorchid testes are situated within the inguinal canal and intra-abdominal cryptorchid testes are found in the caudal or mid-abdomen between the kidney and deep inguinal ring (Fig 42).

**2.1.3.2.1 | Cryptorchidectomy of an extra-inguinal testis:** A testis located outside the inguinal canal is generally easily palpable and can often be removed by pushing it caudally to a prescrotal position where it can be excised routinely. Alternatively, an incision can be made directly over it (Fig 43). Either an open or closed surgical technique of orchiectomy is appropriate once the testis is exposed.

**2.1.3.2.2 | Cryptorchidectomy of an inguinal testis:** A testis trapped within the inguinal canal cannot be palpated externally and is not visible within the abdominal cavity. Cryptorchidectomy in this situation requires incision directly over the inguinal canal. Meticulous dissection is necessary, with close attention paid to haemostasis, as the testis must be carefully distinguished from inguinal fat and lymph node. Once the testis and associated structures are exposed, removal is the same as for a descended testis.

**2.1.3.2.3 | Ventral midline laparotomy for cryptorchidectomy of an intra-abdominal testis:** Abdominally retained testes in dogs are usually removed through a combined parapreputial skin and caudal ventral midline abdominal incision. The use of small laparotomy incisions and a spay hook to retrieve retained testes has been reported, but potential complications are unacceptable,





**FIG 44. Ventral midline parapreputial approach to the caudal abdomen. Note the large branches of the caudal superficial epigastric vessels that may require ligation and preputial muscles requiring transection**

and this technique is not recommended (Bellah et al., 1989; Kirby, 1980; Schultz et al., 1996). Adequate exposure is critical when performing cryptorchidectomy. A ventral midline preputial approach to the caudal abdomen has been described and eliminates the need for extensive subcutaneous dissection while decreasing potential problems with haemorrhage from the caudal superficial epigastric vessels (Daniel et al., 2016) (Figs 44 and 45). This method may be appropriate if the retained testis is known to be located in the caudal abdomen near the deep inguinal ring.

Bilateral retained testes are often located caudal to the kidney while a unilateral retained testis is more commonly located in the caudal abdomen lateral to the bladder. The key to finding a retained abdominal testis is to first identify the vas deferens at the prostate, then to follow the vas to the retained testis (Fig 46). Following this rule will avoid reported complications such as inadvertent prostatectomy, ureteral damage, urethral transection and lymph node excision. Once the retained testis is identified and isolated, removal is the same as for a descended testis.

**2.1.3.2.4 | Laparoscopic cryptorchidectomy in dogs:** Laparoscopic cryptorchidectomy is a quick, efficient and minimally invasive technique that provides excellent visualisation of all involved structures. To perform the procedure, the patient is first placed in a head-down (Trendelenburg) position and a urinary catheter is placed. The Trendelenburg position shifts the abdominal viscera forward to improve exposure, while the urinary catheter evacuates the urinary bladder during the procedure. The abdomen is distended with carbon dioxide gas to a pressure of 10 to 15 mmHg using either a Veress needle or Hasson technique. The optical port is placed just caudal to the umbilicus and the caudal abdominal region is explored. If the retained testis is not easily visualised, the inguinal ring should be examined closely to see if the vas deferens and testicular vasculature extend into the inguinal canal. If they do, the laparoscopic procedure is abandoned and converted into routine open surgery for retrieval of an inguinal testis.

Once an intra-abdominal testis has been located, additional instrument ports are placed on each side just lateral to the rectus abdominis muscle about halfway from the umbilicus to the pubis. A grasping instrument is passed through the instrument port on the affected side to grasp and stabilise the testis away from abdominal viscera. Ligation of the testicular vasculature and associated structures is accomplished by stainless steel clips, or a vessel-sealing device passed through the opposite instrument port. The instrument port on the affected side is then enlarged slightly, and the testis is removed (Fig 47).

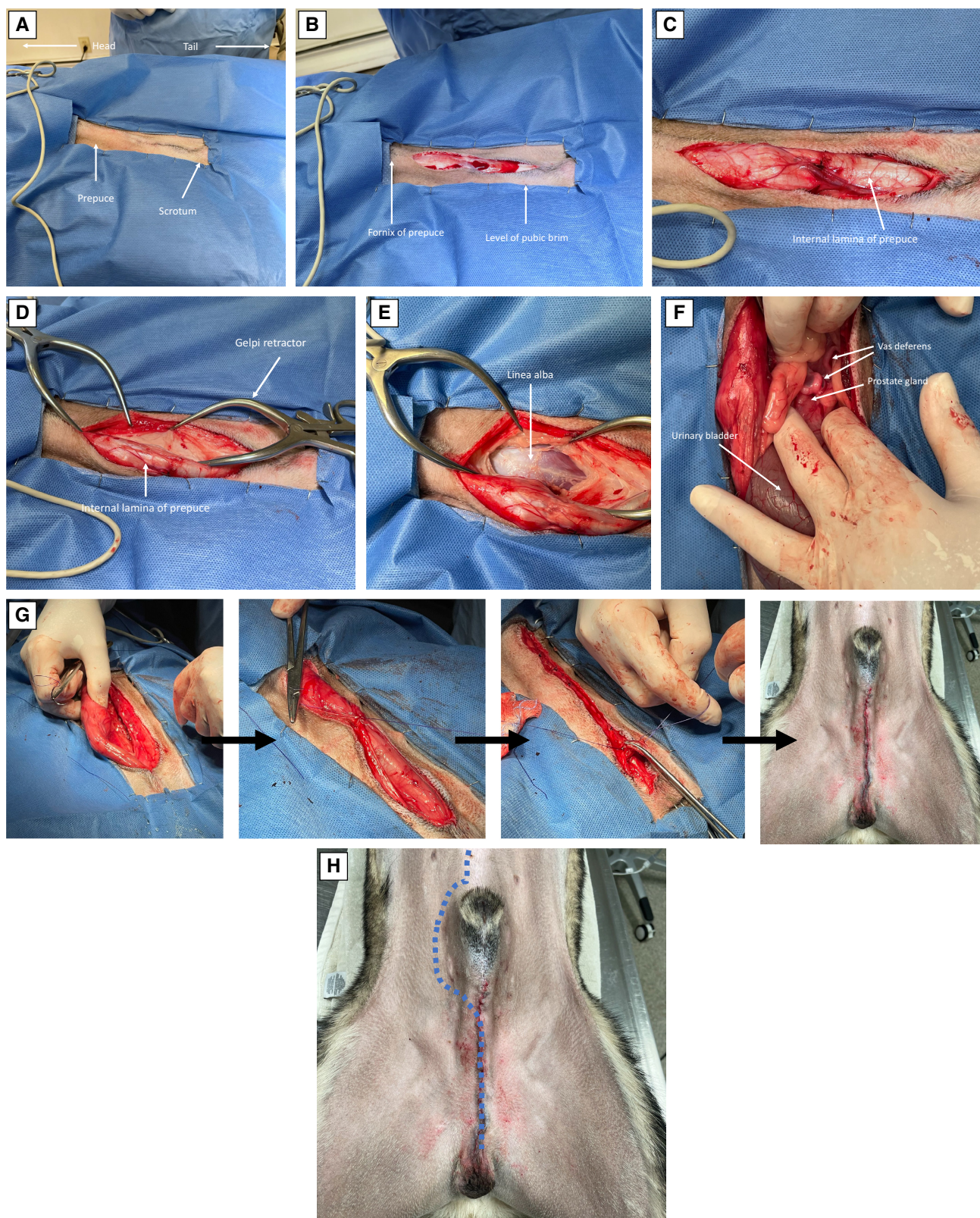
An alternate “laparoscopic assisted” technique can also be employed. In this technique, the retained testis is identified as previously, but an instrument port is created only on the affected side. The testis is grasped, brought against the body wall and then exteriorised by enlarging the instrument port. Ligation of vascular and associated structures is accomplished extracorporeally, and the ligated stump is returned to the abdomen (Fig 48).

## **2.1.4 | Male cats**

### **2.1.4.1 | Orchiectomy in cats with descended testes**

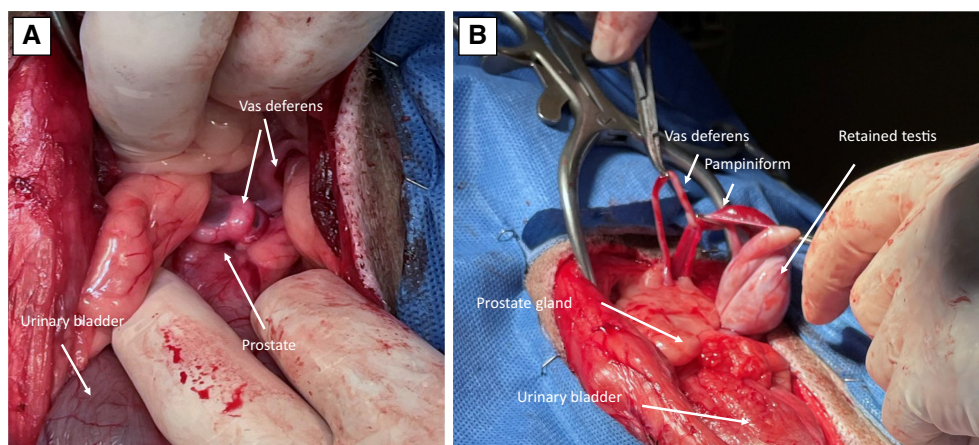
**2.1.4.1.1 | Scrotal orchiectomy in cats:** Scrotal orchiectomy has been the standard of care for sterilisation of male cats for many years. The procedure can be done in either dorsal or lateral recumbency with either both legs or just the upper leg pulled forward. Scrotal hair can either be gently clipped or plucked. A single midline or separate incisions over each testis are possible, but a single incision provides less opportunity for bleeding. Gentle even traction is used to extrude the testis and expose the spermatic cord.





**FIG 45. Ventral midline preputial approach to the caudal abdomen. (A) Positioning in dorsal recumbency. (B) Skin incision directly over penis and prepuce This incision generally extends from about 1.0 cm caudal to the fornix of the prepuce to the base of the prepuce. (C) Dorsal dissection exposes the internal lamina of the prepuce. (D) The penis underlying the exposed internal lamina is retracted laterally to expose the body wall. (E) Body wall exposed. (F) Incision through the linea alba exposes the caudal abdominal viscera. (G) Routine closure. Note that in the case demonstrated the incision has been extended caudally to include access for orchidectomy of a descended testis. (H) The skin incision can also be lengthened cranial if further abdominal exposure is necessary**





**FIG 46. Locating an abdominal cryptorchid testis. (A) The safest method to locate a cryptorchid testis is to palpate the prostate gland at the bladder neck. The vas deferens on each side enters at this site. (B) The vas deferens is followed to the retained testis**

As with dogs, both open (vaginal tunic opened) and closed (vaginal tunic left intact) techniques are possible at this point. Structures can be ligated with absorbable suture material, surgical clips or a vessel-sealing device.

A common option for male cat orchietomy that eliminates the need for sutures is auto ligation. The method is generally performed using a closed technique but can be done open as well. For auto-ligation a mosquito forceps is first directed parallel to the spermatic cord, pointed in a cranial direction. The forceps are then twisted around the cord by passing first under, then over and finally back under the spermatic cord. While holding the forceps in position, the spermatic cord with attached testis is brought over the top and grasped with the tip of the forceps, forming a loop. Transection of the cord on the testicular side allows removal of the testis. The free end of the spermatic cord is then pulled through the loop and tightened, forming a simple overhand knot (Hedlund, 2002).

A second sutureless option for male cat orchietomy requires open technique. After the vaginal tunic has been opened a window is made between the vas deferens and testicular vessels. The vas deferens is transected near the testis and following removal of the testis the vas is tied to the spermatic vessels with several square knots (Hedlund, 2002).

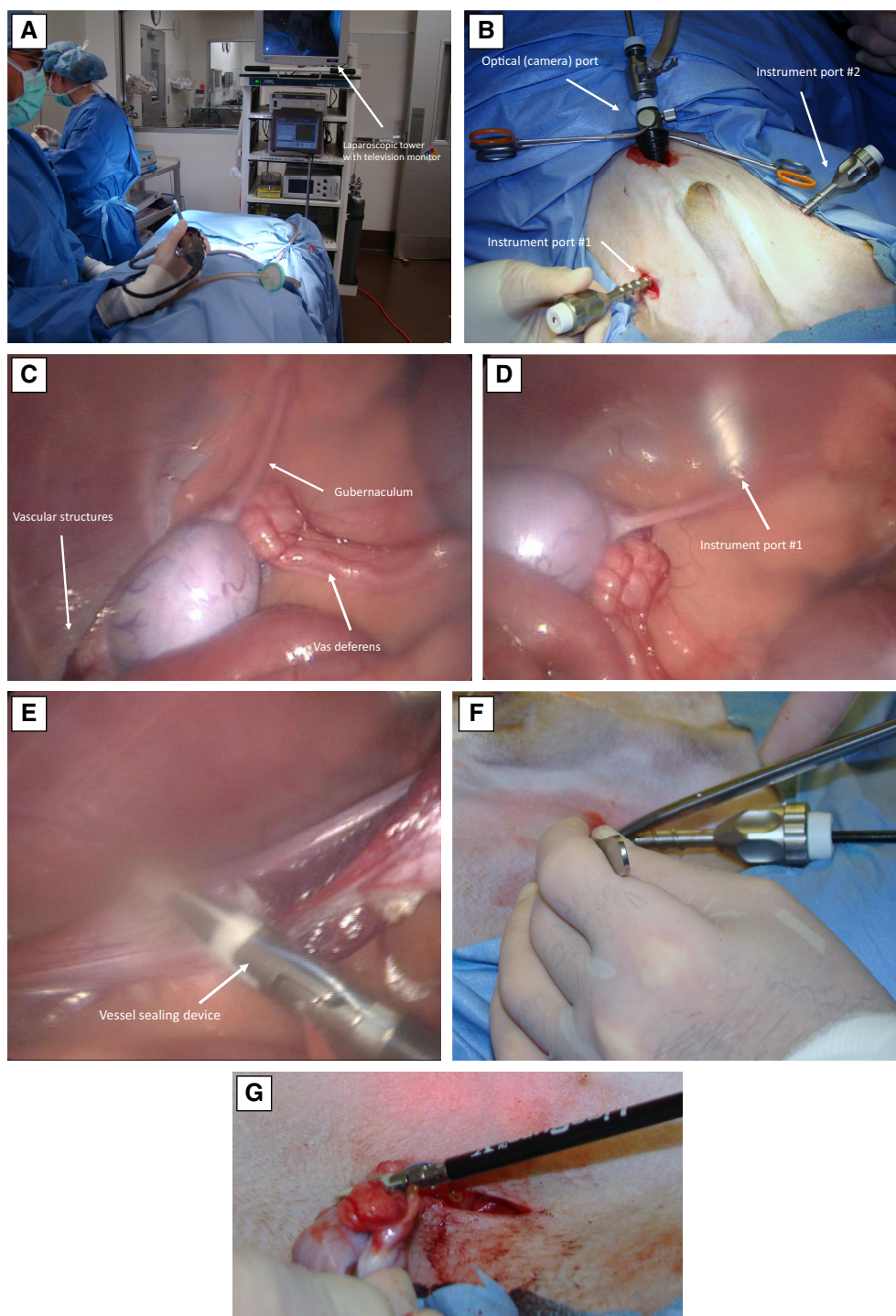
It should be noted that a final sutureless method, orchietomy by simple traction, is unacceptable. Simple traction depends on vessel spasm to prevent haemorrhage and was utilised historically to provide speed of operation in non-sedated patients (Hobday, 1924). Orchietomy using simple traction or any surgery without adequate sedation and analgesia is inhumane. Depending on vessel spasm to provide haemostasis given the availability of multiple superior options, has no place in modern veterinary practice.

Regardless of surgical method, the scrotal incision is frequently left open as this provides drainage and helps reduce the incidence of post-surgical self-inflicted trauma.

**2.1.4.2 | Orchietomy in cats with cryptorchid testes:** The incidence of cryptorchidism in cats has been reported to be between 0.4 and 3.8% with an increased risk in the Persian breed (Henderson, 1951; Millis et al., 1992; Richardson & Mullen, 1993). The condition is presumed to be heritable, and a polygenic mode of inheritance has been suggested (Herron & Stern, 1980). Although normal testicular descent is generally complete before birth in cats a definitive diagnosis should not be made in cats less than seven to 8 months of age (Sojka, 1980). As with dogs, cryptorchid testes may be located anywhere along the normal path of descent between the caudal pole of the kidney and scrotal sac and are classified and treated accordingly. Extra-inguinal cryptorchid testes are located between the superficial inguinal ring and scrotal sac, inguinal cryptorchid testes are situated within the inguinal canal and intra-abdominal cryptorchid testes are found in the caudal or mid-abdomen between the kidney and deep inguinal ring.

**2.1.4.2.1 | Cryptorchidectomy of an extra-inguinal testis:** Extra-inguinal cryptorchid testes are easily palpated in cats and can generally be removed routinely by manipulating the testis into a scrotal location or incising directly over it.

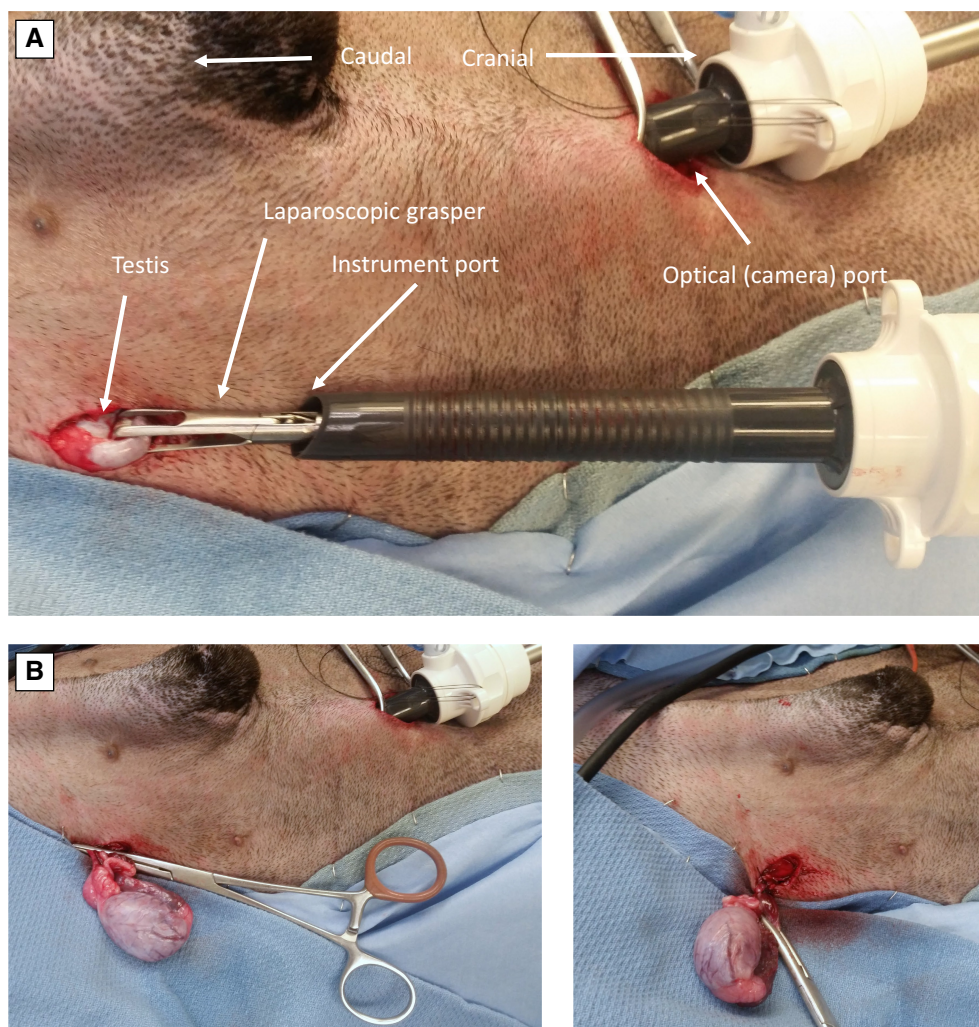
**2.1.4.2.2 | Cryptorchidectomy of an inguinal testis:** A testis trapped within the inguinal canal cannot be palpated externally and is not visible within the abdominal cavity. Most commonly, a cryptorchid testis is identified as inguinal during abdominal exploration. If a testis is not easily identified in the abdomen, the vas deferens should be identified as it enters the prostate and followed distally. If the vas extends into the deep inguinal ring and a testis cannot be palpated in the scrotal sac, then the testis is either inguinal or the animal has had an orchietomy performed previously.



**FIG 47. Laparoscopic cryptorchidectomy.** (A) Positioning for laparoscopic cryptorchidectomy. The television monitor is placed towards the caudal aspect of the patient. (B) The optical port is placed just caudal to the umbilicus and two instrument ports are located lateral to the rectus abdominus muscle, halfway between the umbilicus and pubis. (C) Visualisation of the cryptorchid testis and associated structures. (D) Instrument port #1 is seen penetrating the abdominal wall on the affected side. This port will be used to grasp and retract the testis. (E) Once the testis is elevated and retracted a vessel-sealing device is applied through instrument port #2 and across the vascular structures. (F) Instrument port #1 is enlarged slightly to allow retrieval of the testis. (G) Final retrieval

Testes located in this area require incision directly over the inguinal canal. Meticulous dissection is necessary, with close attention paid to haemostasis, as the testis must be carefully distinguished from inguinal fat and lymph node. Once the testis and associated structures are exposed, removal is the same as for a descended testis.





**FIG 48. Laparoscopic assisted cryptorchidectomy. (A) Using an optical port and single instrument port the cryptorchid testis is visualised, grasped and retrieved. (B) Ligations are performed extracorporeally**

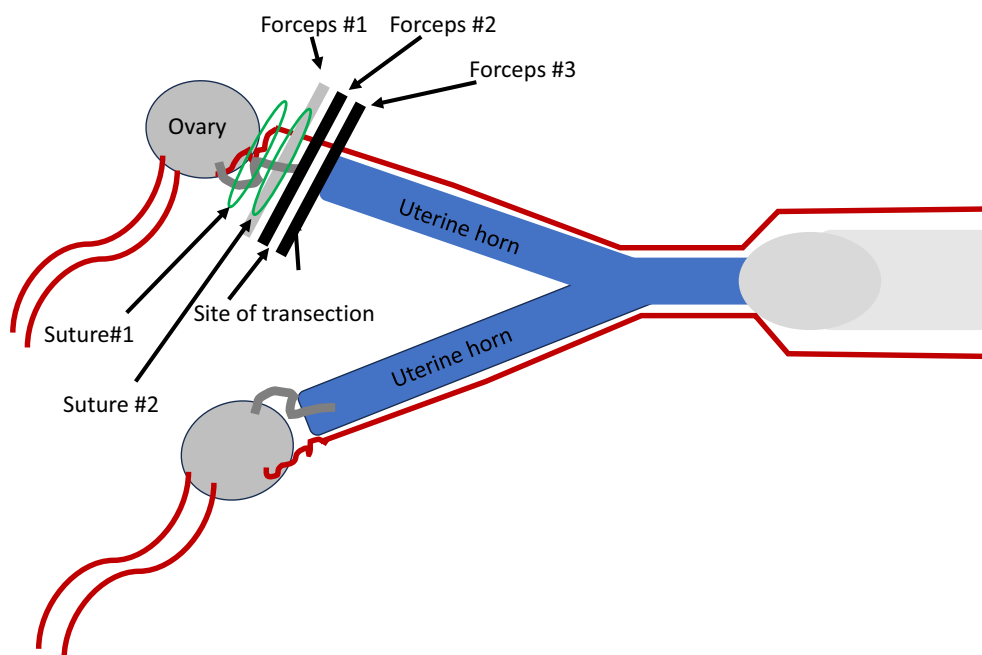
**2.1.4.2.3 | Ventral midline laparotomy for cryptorchidectomy of an intra-abdominal testis:** Abdominally retained testes are removed through a ventral midline caudal abdominal skin incision in cats. As with dogs, the key to finding a retained abdominal testis is to first identify the vas deferens at the prostate, then follow the vas to the retained testis. Once the retained testis is identified and isolated, removal is the same as for a descended testis.

## **2.2 | Surgical sterilisation of dogs and cats with preservation of gonadal hormones**

### **2.2.1 | Female dogs**

**2.2.1.1 | Hysterectomy:** HE is the most common method for surgical sterilisation when preservation of gonadal hormones is desired. The terms “ovary-sparing spay” and “ovary-sparing hysterectomy” have also been used to describe this procedure. Ovary-sparing spay is actually incorrect, as “spay” by definition indicates removal of the ovaries. Use of the term ovary-sparing hysterectomy is redundant, as hysterectomy alone precisely describes the procedure performed.

Preoperative preparation and postoperative management of dogs with hysterectomy is the same as for OHE. Owners should be reminded that after gonad sparing sterilisation female dogs will still demonstrate behavioural heat and attract male dogs during this period. Vaginal perforation has been reported after breeding both in intact female dogs and dogs sterilised by routine SOHE that were in oestrus at the time of surgery (Lunn et al., 2009; Morey, 2006). There is no evidence of increased risk of perforation in a female dog bred after hysterectomy, compared to intact female dogs and female dogs sterilised by other methods, however long-term data after hysterectomy are missing. Some clinicians recommend annual ultrasound exam of the mammary glands and ovaries to increase the likelihood of early detection of potential mammary gland and ovarian pathology.



**FIG 49. Location of forceps, ligatures and transection site of the mesosalpinx for a hysterectomy procedure**

Identification of animals sterilised using hormone-sparing methods is particularly important to avoid confusion and unnecessary reoperation. Unfortunately, a recent survey indicated that this is rarely practiced (Brent, 2019). Only 14.3% of veterinarians offering hormone-sparing sterilisation provided some means of external identification after hysterectomy and 31.8% after vasectomy. A simple tattoo (green “X” for hysterectomy and green “V” for vasectomy) placed at the same site as used for routine gonadectomy is recommended.

**2.2.1.1.1 | Ventral midline laparotomy for hysterectomy in dogs:** Surgical manipulations will be performed very caudal in the abdomen, so it is important that the urinary bladder be emptied by manual expression soon after anaesthetic induction. If this is not possible, the bladder should be emptied by cystocentesis once the abdomen is open. The surgical incision for hysterectomy generally extends from just caudal to the umbilicus to the pubic brim. Identification and exposure of both the ovaries and uterus are the same as for OHE.

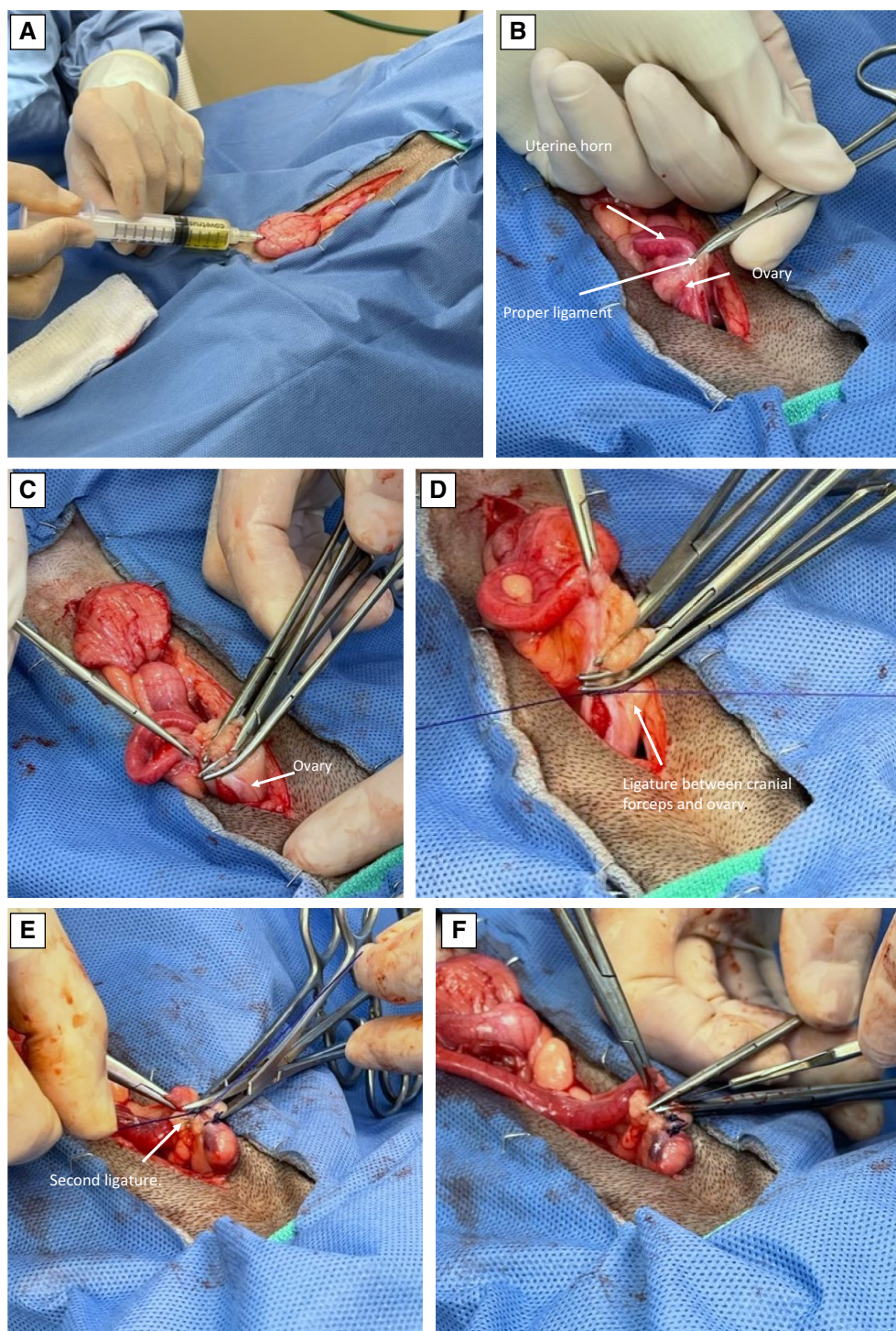
Once the first ovary is identified it is elevated with a haemostat placed on the proper ligament and a window made in the mesosalpinx at the junction with the uterine horn. In the committee's experience, releasing the suspensory ligament to facilitate exposure while leaving the ovary in situ does not appear to have negative consequences on hormone production.

Several methods of ligation can now be used with success, but regardless of technique, it is critical that all uterine tissue be removed to prevent increased risk of future cystic endometrial hyperplasia complex. Studies indicate that remnant tissue is most likely at the proximal ligation site, so particular caution is advised in this location (Mejia et al., 2020). The surgeon needs to recognise the close proximity of the uterine horn to the ovary; only a few millimetres of mesosalpinx separate the structures. Fat in the ovarian bursa often obscures visualization of the ovary, but the opening of the ovarian bursa into the peritoneal cavity is generally seen with the darker pink fimbriae of the uterine tube marking its location. In one common method, three forceps are placed across the mesosalpinx and two ligatures are placed. The first ligature lies between the ovary and most proximal forceps and the second in the crush of the most proximal forceps. The mesosalpinx is then sharply transected between the two remaining forceps (Kutzler, 2020b) (Figs 49 and 50). Using a knot design that has inherent resistance to slippage on the first throw such as a miller's knot may be advantageous, especially in large breed dogs. If proximity of the cranial uterine horn and ovary prevent definitive separation with multiple forceps, a single transfixing suture should be considered to minimize risk of leaving residual uterine glandular tissue after surgery (Mejia et al., 2020). Vessel-sealing devices, bipolar electrosurgical forceps or vascular clips can also be used for ligation and decrease surgery times.

Once the uterine horn is separated from the ovary, it is followed to the uterine body and then the opposite uterine horn and ovary. At this point, either the ovary-sparing procedure can be repeated, or the contralateral ovary removed. Removal of the opposite ovary does not alter the hypothalamic–gonadal axis and has the advantage of potentially decreasing the risk of subsequent ovarian pathology.

The broad ligament is then cut or bluntly dissected lateral to the uterine artery to the level of the vagina. Studies indicate the presence of glandular tissue responsive to gonadal hormones within the cervix, so transection should be at the level of the cranial vagina rather than cervix (Mejia et al., 2020). Several methods for ligation and transection can be used with success, but regardless of technique the uterine arteries should be individually transfixed. This location is very caudal in the abdomen and exposure can be difficult. A surgical assistant is helpful for retraction when performing this part of the procedure.

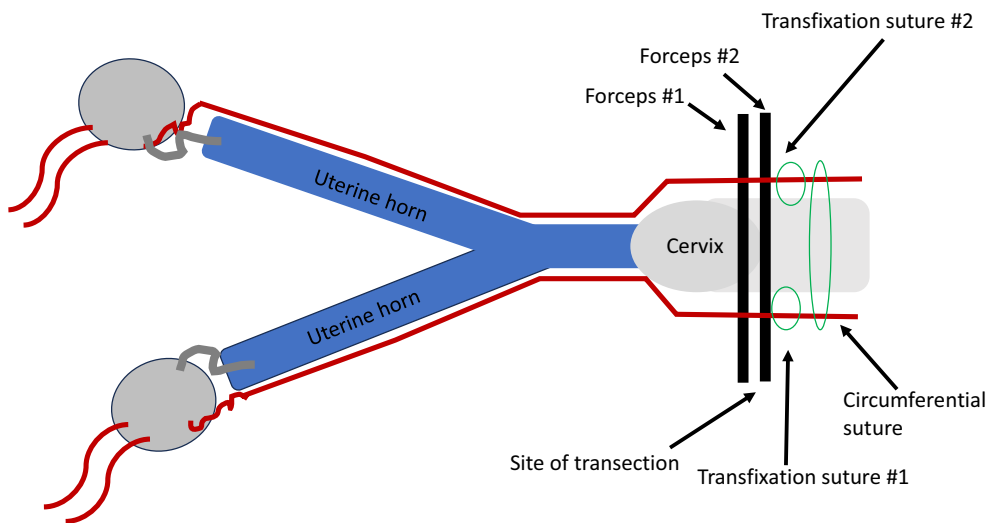




**FIG 50.** Intraoperative view of approach, forceps, ligatures and transection site of the mesosalpinx for hysterectomy in a bitch. (A) Urinary bladder completely emptied. (B) Proper ligament grasped for retraction. (C) Triple clamp mesosalpinx. (D) Ligature between cranial forceps and ovary. (E) Second ligature in crush of most cranial forceps. (F) Transect between middle and distal forceps

In one common technique, two forceps are placed at the junction of the cervix and vagina. Both uterine arteries are individually trans-fixed caudal to the forceps, and then a third circumferential ligature placed caudal to these. Similar to ligation of the ovarian pedicle, use of a knot configuration with inherent resistance to slippage on the first throw such as a miller's knot is advantageous for this circumferential ligature. The vagina is then transected between the two forceps (Figs 51 and 52). Remaining tissue should be checked to assure no uterus remains, and the cut surface evaluated carefully for bleeding before replacing back into the abdomen. Some surgeons prefer to place all ligatures without forceps, and then cut cranial to the ties through the cranial vagina, leaving at least 3 mm between the sutures and cut surface.





**FIG 51. Location of forceps, ligatures and transection site of the cranial vagina for a hysterectomy procedure. Note that the transfixation sutures are cranial to the circumferential suture. This provides some protection against possible haemorrhage if one of the transfixation sutures inadvertently penetrates a uterine artery**

While successful use of a vessel-sealing device has been reported for closure of the uterine horn in dogs, uterine bodies  $\geq 9$  mm in diameter failed at unacceptably low bursting strengths (Barrera & Monnet, 2012). Hysterectomy requires distal closure at the level of the vagina and bursting strength after application of a vessel-sealing device has not been investigated in this location. Until such studies are available use of a vessel-sealing device for closure of the cervix or cranial vagina is not recommended.

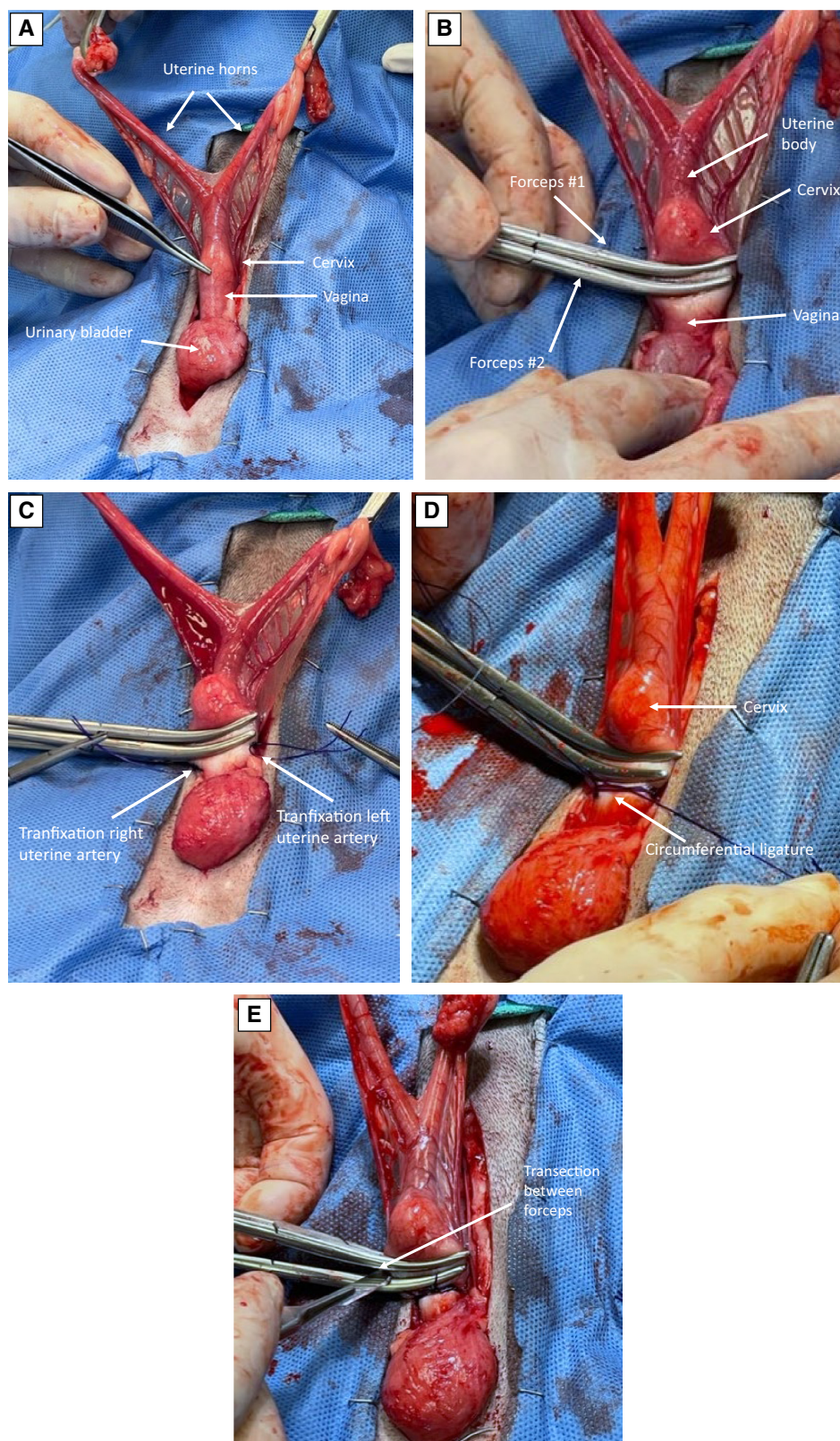
Closure is the same as for routine OHE.

**2.2.1.1.2 | Flank laparotomy for hysterectomy in dogs:** Flank laparotomy does not allow sufficient exposure for hysterectomy and is not recommended.

**2.2.1.1.3 | Laparoscopic hysterectomy in dogs:** Laparoscopic hysterectomy is often performed as a “laparoscopic assisted” procedure with either one or three ports (Fig 53). The single port method requires either an operating laparoscope or use of a port designed to accommodate both the camera and multiple laparoscopic instruments (Fig 22). For the three-port method, patient positioning, placement of the camera and first instrument port, and identification of the first ovary are the same as described previously for two port OE (Fig 23). This port is placed in a prepubic position. Once the first ovary is identified it is temporarily secured to the abdominal wall using an OE hook or #2 suture material attached to a large swaged on needle. The needle is passed through the abdominal wall, proximal uterine horn and then back through the abdominal wall to “skewer” and stabilise the ovary. In this position the ovary can be separated from the proximal uterine horn using electrocoagulation or a vessel-sealing device. It is critical to perform this manoeuvre directly adjacent to the ovary as any remaining uterine tissue may predispose to subsequent pyometra. Transecting a short section of proximal mesometrium facilitates subsequent retrieval of the uterine horn. The procedure is then repeated on the opposite side.

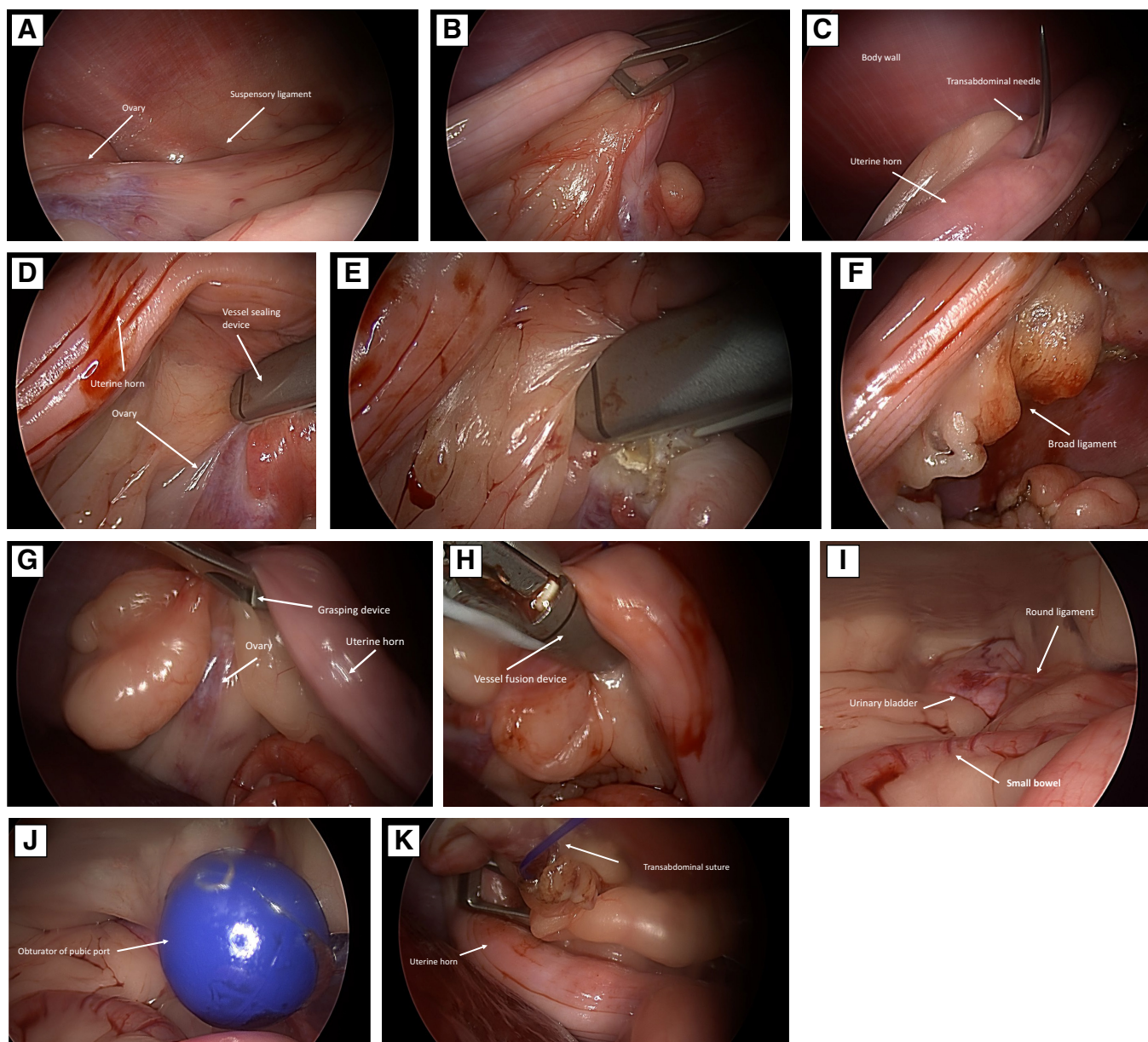
After both ovaries are separated from the uterine horns, the patient is positioned into dorsal recumbency, the telescope rotated 180° to view caudally, and a second instrument port is placed in a pre-pubic location under direct visualisation. The telescope is then rotated back 180° to view cranially and one of the transected proximal uterine horns identified. This is facilitated by lifting on the transabdominal fixation suture. The proximal uterus is grasped with an instrument placed through the pre-pubic port and retracted to the level of, but not through the port. Once in this location, the port site is enlarged sufficiently to allow the horn to be delivered through the incision. After the first horn is delivered, it is followed to the uterine body and opposite horn, which is also retrieved. The remainder of the procedure is then performed extracorporeally as an open hysterectomy. Closure of the port sites is the same as for laparoscopic OE.

**2.2.1.2 | Salpingectomy:** Unilateral or bilateral salpingectomy is sometimes performed in women for a variety of health concerns including contraception, infections and decreasing the risk of cancer. The procedure is generally performed laparoscopically. Bilateral salpingectomy provides sterilisation with preservation of gonadal hormones but is not recommended in dogs as persistent gonadal hormones with an intact uterus predispose to the development of CEH/pyometra complex.



**FIG 52.** Intraoperative view of forceps, ligatures and transection site of the cranial vagina for hysterectomy in a bitch. (A) Exposure of entire reproductive tract including cervix and cranial vagina. (B) Two forceps placed caudal to cervix. (C) Both uterine arteries are transected. Note that in the figure each uterine is transected to the uterine wall without passing the suture circumferentially. (D) Circumferential ligature placed caudal to transection sutures. A two-pass friction knot may be preferred in this location. (E) Final transection between the two forceps

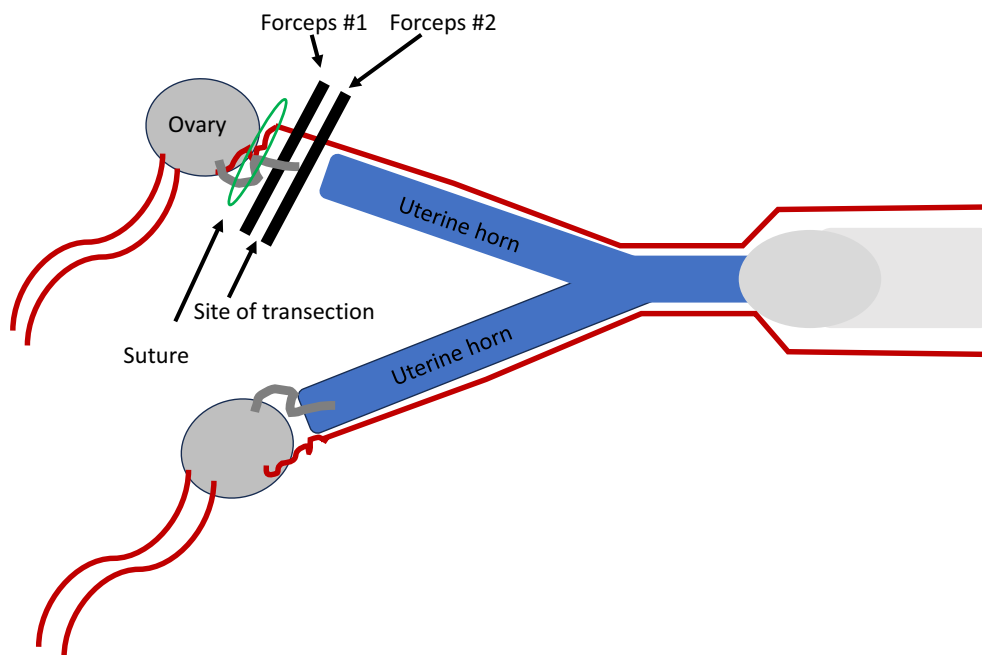




**FIG 53. Laparoscopic assisted hysterectomy.** (A) Laparoscopic view of the ovary and suspensory ligament. (B) Elevation of the proximal uterine horn. (C) Stabilisation of the proximal uterine horn with a transabdominal fixation suture. (D) Vessel-sealing device being applied to the junction of the uterine tube and ovary. (E) Vessel sealing at the junction of the uterine tube and ovary. (F) Proximal broad ligament fused to increase mobility. (G) Isolation of ovary on opposite side. (H) Vessel fusion on the opposite side. (I) Camera directed caudal to visualise additional port placement at the pubic brim. (J) Obturator placed for pubic brim port under direct visualisation. (K) Proximal uterine horn on one side is grasped with an instrument through the pubic brim port. It is then retracted through the caudal port and the process repeated on the opposite side until both uterine horns are exteriorized. The remainder of the procedure is performed extracorporeally as described for hysterectomy by laparotomy ([Fig 52](#))

**2.2.1.3 | Ovarian tissue implant:** Ovarian tissue implant refers to bilateral removal of the ovaries with or without simultaneous partial or complete removal of the uterus, followed by re-implantation of ovarian tissue into an area of portal vein drainage. Sites for re-implantation are most commonly beneath the stomach serosa or small intestine (Arnold et al., [1992](#); Le Roux, [1983](#); Le Roux & Van Der Walt, [1977](#)). While ovarian tissue implant procedures preserve gonadal hormones, they are not recommended for surgical sterilisation. If the uterus remains in situ as with OE or SOHE CEH/pyometra complex can occur. OHE with reimplantation of ovarian tissue eliminates the risk of CEH/pyometra complex and provides sterilisation with preservation of gonadal hormones, but hysterectomy is a simpler, safer and more reliable procedure.





**FIG 54.** Sites of forceps and suture placement for transection of the mesovarium in a feline hysterectomy procedure

## 2.2.2 | Female cats

Sterilisation of female cats with preservation of gonadal hormones is rarely recommended for client-owned animals due to behaviour issues associated with frequent hormonal cycling and high incidence of malignant mammary gland tumours in intact females (Misdorp et al., 1991; Overley et al., 2005). Sterilisation with preservation of hormones is occasionally recommended in research situations and has been suggested as potentially a more effective method to control community cat populations (McCarthy et al., 2013; Mendes-de-Almeida et al., 2006; Mendes-de-Almeida et al., 2011).

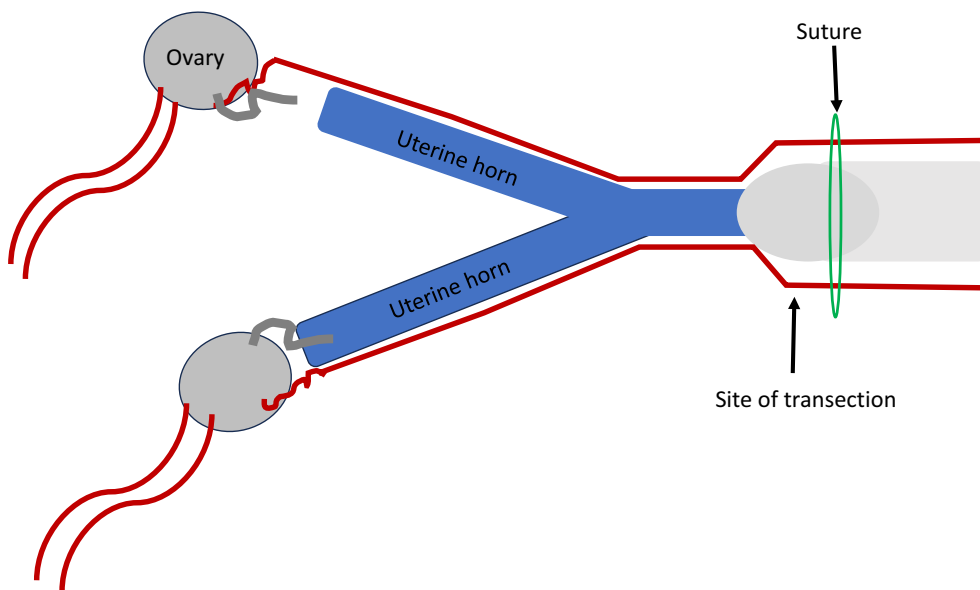
### 2.2.2.1 | Hysterectomy

**2.2.2.1.1 | Ventral midline laparotomy for hysterectomy in cats:** The surgical approach, identification and isolation of reproductive structures for HE in cats is the same as described for OHE, as access to both the proximal and distal extents of the uterus is required. To separate the proximal uterine horn, two forceps are placed across the mesosalpinx, directly abutting the ovary and a single circumferential ligature placed between the most cranial forceps and ovary. The tissue is then transected between the forceps (Fig 54). Some surgeons prefer to avoid forceps altogether in this situation and simply place a single ligature across the mesosalpinx, followed by transection between the ligature and uterine horn, leaving at least 3 mm normal tissue.

Identification of the cervix is difficult in cats as it lacks the highly cartilaginous nature seen in dogs. Ligatures are placed caudal to the uterine bifurcation, but whether this tissue is uterine or cervical is often unknown. Regardless of anatomic location, forceps are generally neither required nor indicated. A single circumferential miller's knot is placed caudal to the uterine bifurcation and the tissue transected at least 3 mm cranial to that site (Fig 55).

## 2.2.3 | Male dogs

**2.2.3.1 | Vasectomy:** Vasectomy in male dogs is generally performed using either a prescrotal (Clinton, 1972; McCarthy, 2019; Rubin, 1977) or laparoscopic (Silva et al., 1993; Wildt et al., 1981) surgical approach. The laparoscopic vasectomy is most commonly indicated when combined with a second laparoscopic abdominal surgery such as prophylactic gastropexy. Alternate methods reported include implantation of an intravasal filtering device, ultrasound ablation, non-invasive laser surgery and electrocoagulation (Chen et al., 2010; Cilip et al., 2011; Rao et al., 1980; Roberts et al., 2002a). After vasectomy, the seminiferous tubules will continue to produce sperm, so the epididymis may initially distend and dilate. Rarely, a spermatocele may cause epididymal fluid to extravasate, causing an inflammatory reaction or sperm granuloma (Mayenco Aquirre et al., 1996; Perez-Marín et al., 2006). Scrotal discomfort is reported in about 15% of vasectomised men (Leslie et al., 2007). Vasectomised dogs occasionally present after surgery with recurrent scrotal dermatitis which may be caused by scrotal discomfort as well.



**FIG 55. Site of suture placement and transection of the cranial vagina in a feline hysterectomy procedure**

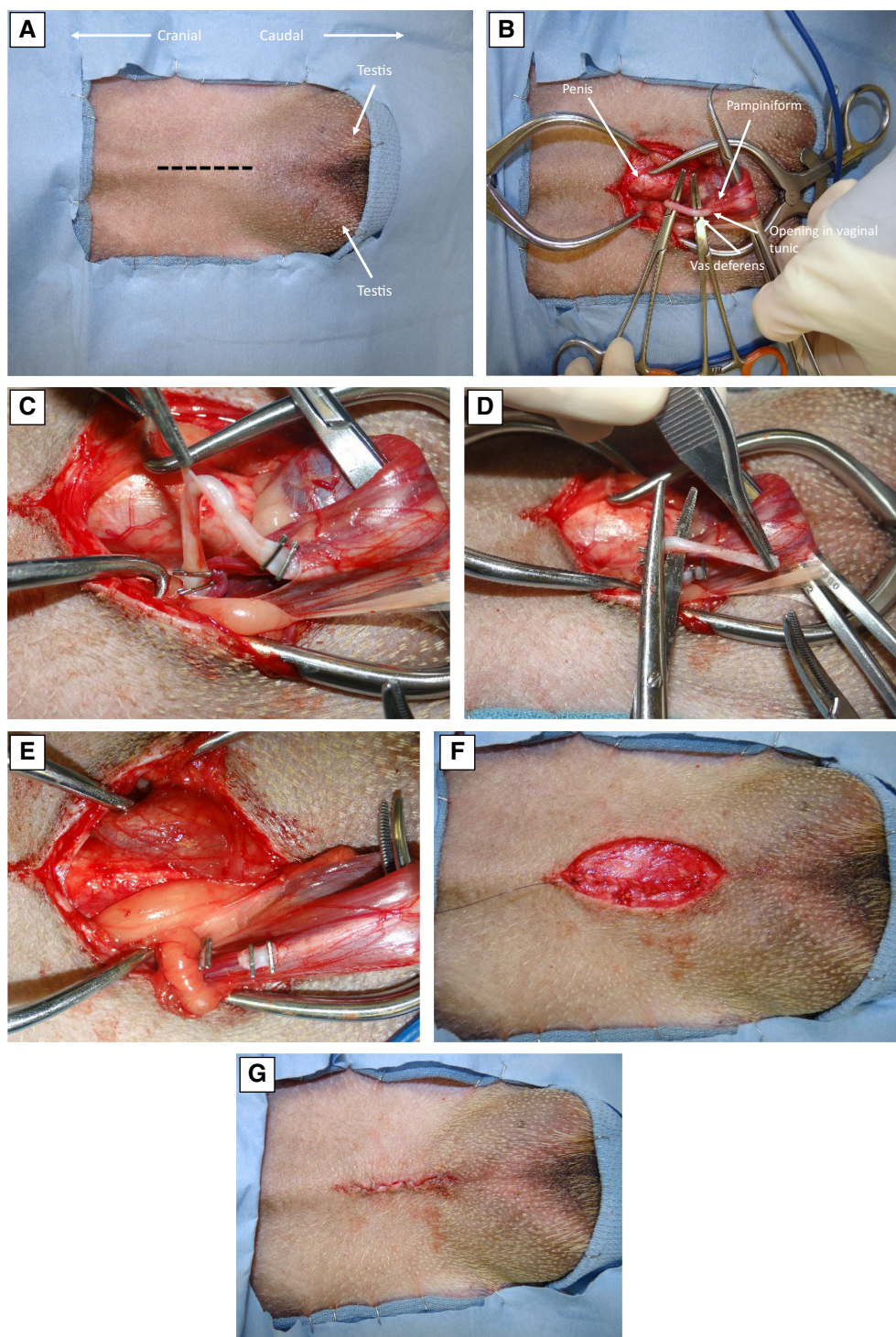
Studies regarding time to azoospermia after vasectomy in dogs are conflicting, but in one study spermatozoa were detected in ejaculates of male dogs up to 21 days after vasectomy (Pineda et al., 1976; Schiff et al., 2003), so contact with females in heat should be avoided during this period or pregnancy is possible. The presence of spermatozoa can be decreased to 6 days after vasectomy by flushing of the vas deferens at the time of surgery (Frenette et al., 1986).

**2.2.3.1.1 | Prescrotal vasectomy in dogs:** Prescrotal vasectomy is a straightforward procedure easily performed in general practice (Clinton, 1972, McCarthy, 2019, Rubin, 1977) (Fig 56). In most dogs, the spermatic cords can be palpated as they extend from the scrotum towards the inguinal rings and aids orientation. A 3- to 5-cm prescrotal midline incision is made slightly cranial to the site for routine prescrotal orchiectomy. Careful dissection in a lateral direction exposes the spermatic cord. If localization is difficult, it is sometimes useful to manipulate the testis caudally and cranially to tense and relax the cord. Visualisation is improved by separating the incision with self-retaining Gelpi or Weitlaner retractors (Figs 57 and 58). Once the spermatic cord is identified and freed of surrounding fat and fascia, it is isolated by circumferential passage of a haemostat. A small incision is then made in the vaginal tunic with a scalpel blade or tenotomy scissor. The testicular vessels lie in the lateral fold of the visceral vaginal tunic, while the vas deferens and associated deferential artery and vein lie in the medial fold. Extreme care should be taken to avoid any disruption of the pampiniform plexus. If the pampiniform is inadvertently damaged, very small holes may be treated with pressure, cryotherapy (iced saline-soaked sponge) and/or topical haemostatic agents. Local infusion of phenylephrine (0.22 mg/kg of 10 mg/mL solution diluted 1/3) could also be attempted. More extensive lacerations require gonadectomy of the affected testis. The vas deferens with associated deferent artery is identified as a turgid white structure. Circumferential ligatures are placed 1 to 2 cm apart and a short section of vas deferens excised between them. Closure of the vaginal tunic can be performed with fine (4.0 to 5.0) absorbable suture material although this appears unnecessary. The subcutaneous tissues are closed with absorbable suture and an intradermal pattern or glue used for the skin.

**2.2.3.1.2 | Laparoscopic vasectomy in dogs:** To perform laparoscopic vasectomy, the urinary bladder is first emptied by either manual expression or catheterization. Maintaining a urinary catheter during the procedure is helpful to assure the bladder is completely empty and improve visualisation. The patient is placed in a dorsal slightly head-down (Trendelenburg) position with the optical tower located towards the feet. The abdomen is distended with CO<sub>2</sub> using either a closed (Veress needle) or open (Hasson) method. Intra-abdominal pressure between 12- and 14-mmHg maximises working space while minimising detrimental physiologic effects. After distension is obtained, either a single or double port method can be employed.

For the single port method an access port allowing passage of both the telescope and operating instruments is generally utilised. The port allows passage of three separate devices and is placed just caudal to the umbilicus (Fig 22). After telescope insertion, the vas deferens is identified as it passes towards the inguinal ring on the affected side. Unlike after passage through the inguinal ring, the vas deferens is distinctly separate from other structures of the spermatic cord in this location. Damage to the testicular artery and vein must be avoided as testicular atrophy will occur causing gonadal hormone levels to be similar to traditional orchiectomy (Hsu et al., 1993; Mathon et al., 2011; Tavares et al., 2021).

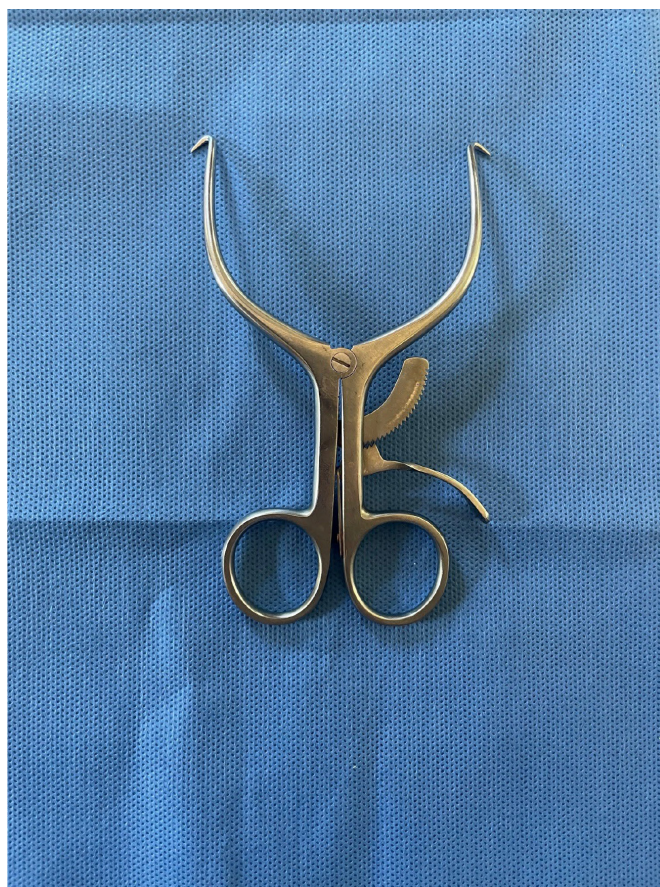



**FIG 56. Prescrotal vasectomy in the dog. (A) Prescrotal incision. (B) Isolate and incise vaginal tunic to expose vas deferens. (C) Clip or ligate vas deferens. (D) Excise 1.0 to 2.0 cm. section of vas deferens. (E) Section excised. (F) Subcutaneous closure. (G) Intradermal skin closure**

A vessel-sealing device is passed through a second opening in the port and is used to simultaneously cut and seal the structure. If a vessel-sealing device is not available, endoscopic cautery can be used in a similar fashion. A final option is to place two endoscopic vascular clips and use endoscopic scissors to remove a short (1 to 2 cm) section of the vas. In any of these situations, a laparoscopic grasping forceps can be placed through the third opening in the port to retract and stabilise the vas if necessary.

For the double port method standard single access laparoscopic ports are utilised. The camera port is placed just caudal to the umbilicus. After identification of the vas deferens, a second port is placed under direct visualisation 4 to 8 cm lateral to the camera



**FIG 57. Gelpi retractor**

port. A vessel-sealing device, endoscopic cautery or vascular clips/scissors are then used to transect the vas as with the single port method. If additional stabilisation of the vas is necessary, a laparoscopic grasping forceps can be passed through a third port 4 to 8 cm lateral to the camera port on the opposite side (Fig 59).

#### **2.2.4 | Male cats**

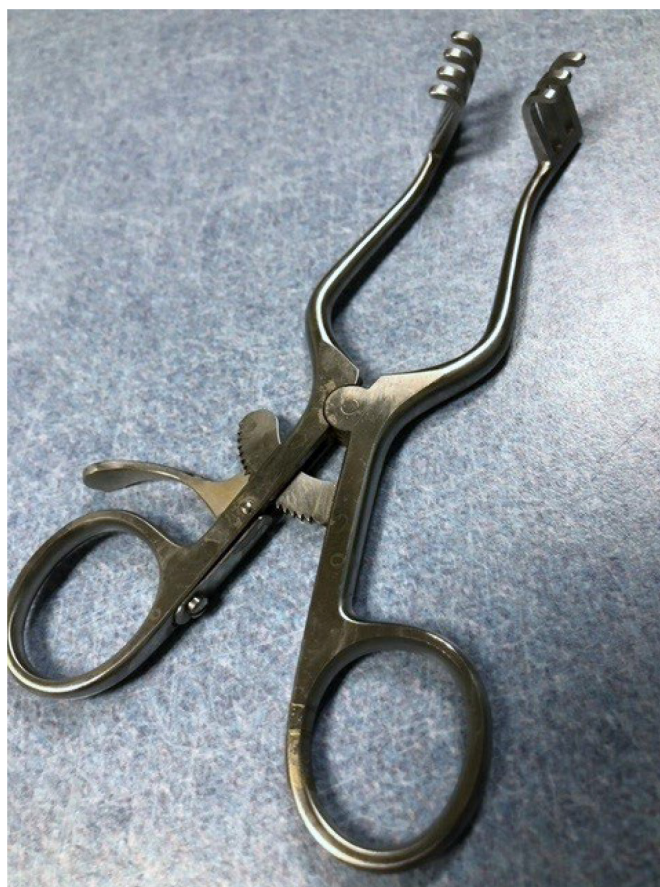Sterilisation of male cats with preservation of gonadal hormones is rarely recommended for client-owned animals due to difficulty with behaviour problems, urine odour and marking. Sterility with preservation of hormones is occasionally recommended in research situations and has been suggested as possibly a more effective method to control feral cat populations (McCarthy et al., 2013).

**2.2.4.1 | Vasectomy:** Vasectomy in male cats can be performed with bilateral inguinal, prescrotal, ventral midline abdominal or laparoscopic approaches. Spermatozoa can be detected in ejaculates of male cats up to 49 days after vasectomy (Pineda & Dooley, 1984), so contact with females in heat should be avoided during this period or pregnancy is possible. The presence of spermatozoa in ejaculates can be decreased to 7 days after vasectomy by flushing the vas deferens at the time of surgery (Frenette et al., 1986).

**2.2.4.1.1 | Bilateral inguinal vasectomy in cats:** For bilateral inguinal vasectomy in cats, 1½- to 2-cm incisions are made over each spermatic cord between the testis and external inguinal ring (Norsworthy, 1975; Pineda & Dooley, 1984). After blunt dissection, the isolated vas deferens is fixed with two forceps, double ligated and severed between the ligatures.

**2.2.4.1.2 | Prescrotal vasectomy in cats:** Prescrotal vasectomy is the same as for inguinal, other than the location of the incision (Downes, 1969; Herron & Herron, 1972).





**FIG 58. Weitlaner retractor**

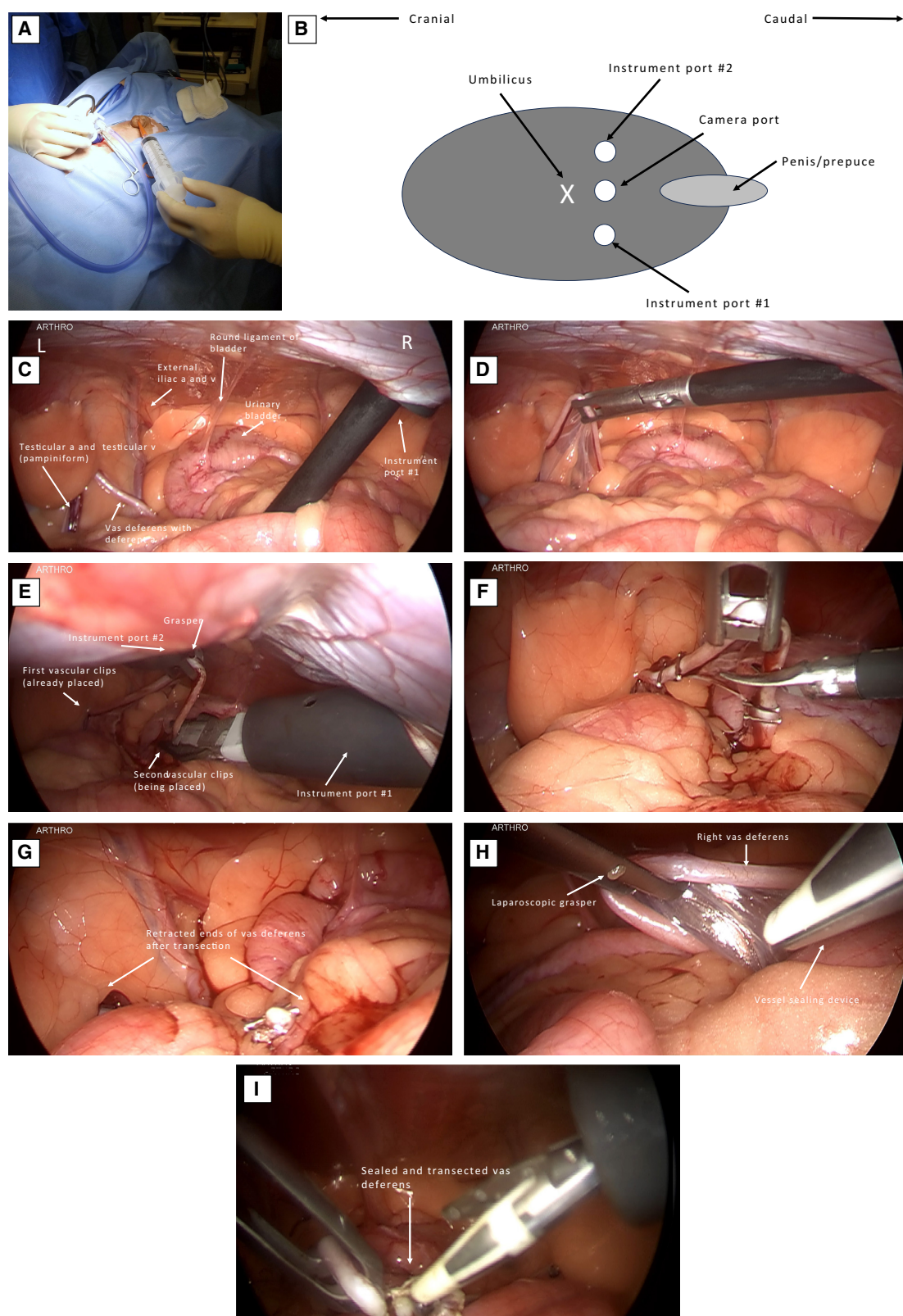
**2.2.4.1.3 | Ventral midline laparotomy for vasectomy in cats:** Ventral midline abdominal vasectomy in cats can easily be performed by general practitioners without the need for advanced surgical training or specialised equipment (McCarthy, 2019). Before surgery, it is critical that the urinary bladder is completely empty. Cystocentesis should be performed intraoperatively if preoperative bladder expression is inadequate. After routine clipping and surgical prep, a 2-cm incision is made extending cranial from about 1 cm from the pubic brim. The emptied bladder is exteriorized and retracted caudally, allowing easy visualisation of the vas deferens on each side crossing into the prostatic urethra. The vas deferens are either double ligated and transected between the ligatures, or more simply can be individually cauterised with a cautery pencil. Closure of the abdominal cavity is routine (Fig 60).

**2.2.4.1.4 | Laparoscopic vasectomy in male cats:** Laparoscopic vasectomy can be performed in male cats, but generally is not indicated due to the simplicity and minimal morbidity of open surgery. The abdominal incision for open surgical vasectomy is smaller than that required for laparoscopic ports and surgical manipulations are no greater than utilised with laparoscopy.

**2.2.4.2 | Epididymectomy in male cats:** Epididymectomy has been described as a method for sterilisation of male cats with preservation of gonadal hormones and may be easier and quicker than vasectomy (Furthner et al., 2023). Patients are placed in dorsal recumbency, scrotal hair is plucked or shaved, and the site prepared for surgery. While firmly holding the testis, the tail of the epididymis is palpated, and a short scrotal incision made directly above the protuberance of the tail of the epididymis. The tunica dartos is incised and the part of the tail of the epididymis located inside the vaginal tunic exteriorized. A transverse cut is made through the vaginal tunic and a section of the tail of the epididymis removed by “rubbing off” with blunt finger dissection. Sutures are not placed (Fig 61). Long term studies regarding behavior as well as field studies investigating the efficiency of epididymectomy for feral cat population control have not been performed.

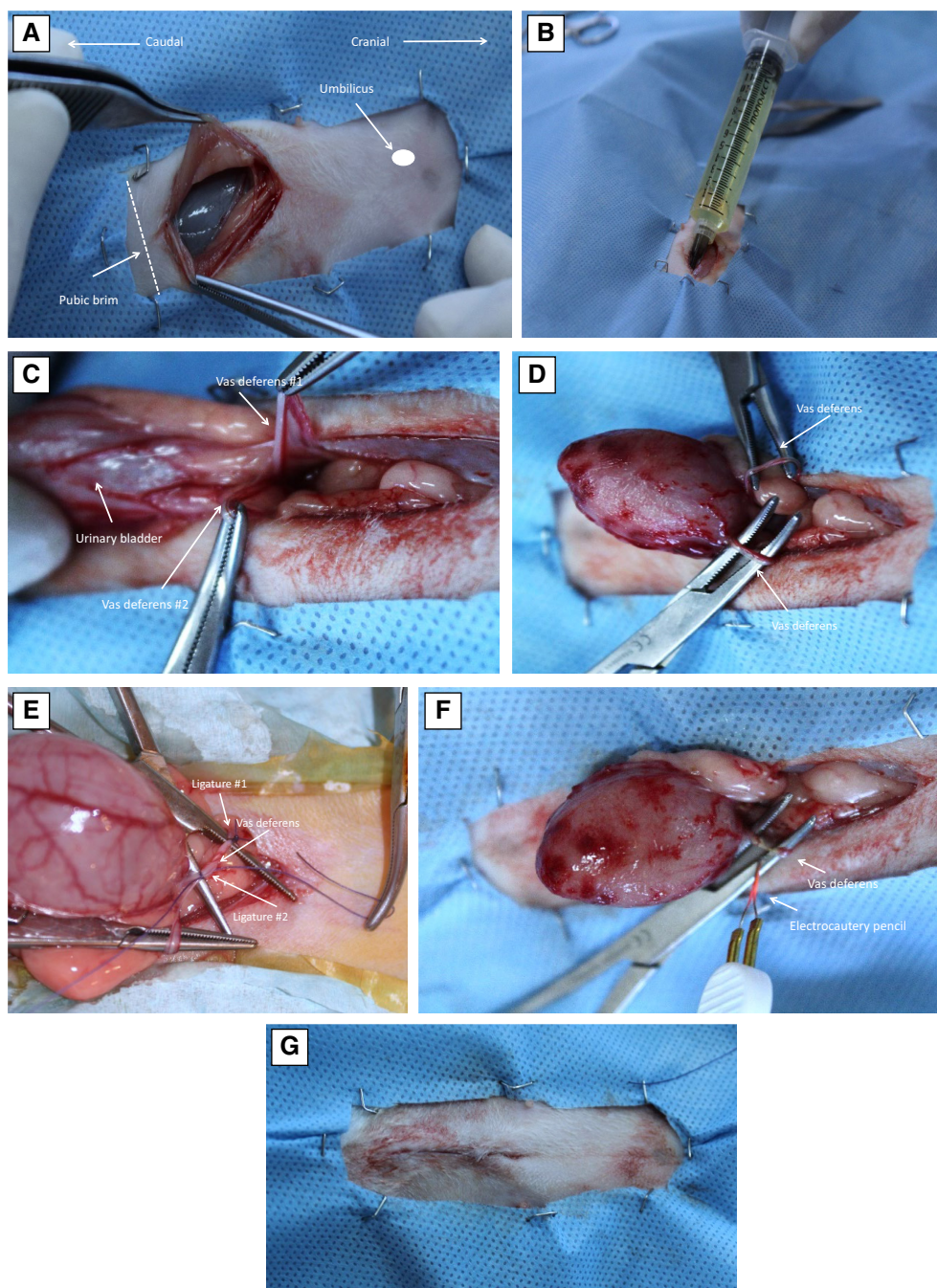
## **2.3 | Antimicrobial use for surgical sterilisation**

Surgical site infections (SSIs) are a significant cause of concern in veterinary patients undergoing sterilisation procedures. In addition to discomfort and morbidity in affected animals, there is client dissatisfaction because of increased costs and required interventions



**FIG 59.** Laparoscopic vasectomy in a dog using three ports. (A) Urinary bladder should be evacuated. (B) Location of ports. (C) Laparoscopic view after placement of camera port and first instrument port. (D) Elevation of the left vas deferens. (E) A second port has been placed on the left side and a laparoscopic grasper used to stabilise the vas deferens while vascular clips are placed from the original port on the right. (F) Transection and excision of a short section of the vas deferens with scissors. (G) Retracted ends of the vas deferens. (H) Elevation of the right vas deferens. (I) A vessel-sealing device can be used for both transection and sealing



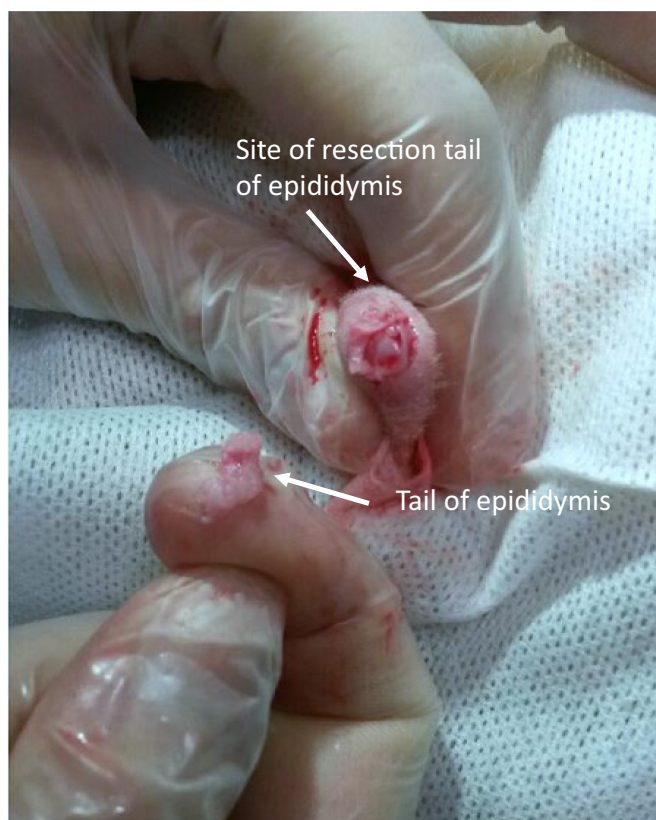

**FIG 60. Ventral midline laparotomy for vasectomy in cats. (A) Caudal ventral midline approach. (B) Urinary bladder completely emptied to allow exteriorization. (C) Urinary bladder retracted caudally exposes vas deferens and associated vessels. (D) Both vas deferens isolated with haemostats. (E) Double ligate and transect. (F) Electrocautery can be used rather than ligation. (G) Intradermal closure**

(Cimino Brown, 2012). Most infections are caused by microorganisms from the patient's endogenous flora, but they can also originate from exogenous sources such as the operating room environment, surgeon or surgical equipment.

Antimicrobial prophylaxis represents a special situation of antimicrobial usage, in that the goal is to prevent, rather than treat infection. In humans, one common tool used to determine the need for antimicrobial prophylaxis is the Wound Classification Scheme described by the National Research Council (Kamel & McGahan, 2011) (Table 1).

Conventionally, antimicrobial prophylaxis is recommended for contaminated and selected clean-contaminated, but not clean surgical wounds. Antimicrobials are used in surgeries classified as dirty, but by definition the usage in this situation is for treatment rather than prophylaxis as they are already infected. One limitation for use of the human wound classification scheme in veterinary patients is the large variability in classification level for a given procedure (Brown et al., 1997). OHE performed by a gowned and



**FIG 61. Epididymectomy in a tomcat. The patient is in dorsal recumbency and a section of the tail of the epididymis is removed by “rubbing off” with blunt finger dissection (From Furthner et al., 2023)**

**Table 1. Wound classification system described by the National Research Council**

Clean
• Non-traumatic, non-inflamed wound with no entry into the urogenital, gastrointestinal or respiratory tracts
• No break in aseptic technique
Clean contaminated
• Entry into the gastrointestinal, urogenital or respiratory tracts under controlled conditions without unusual contamination
• A clean surgical procedure with a minor break in aseptic technique or drain placed
Contaminated
• Fresh traumatic wounds (<4-hour old)
• Spillage from the gastrointestinal or urogenital tracts
• Major break in aseptic technique
Dirty (infected)
• Traumatic wound >4-hour old or with devitalized tissue or foreign bodies
• Perforated viscus encountered
• Acute bacterial inflammation or pus encountered
• Clean tissues transected for access to an abscess

gloved surgeon using sterile towels and drapes in a high-quality operating room with air filtration would likely be classified as “clean,” but the same procedure performed in a field situation may actually be “contaminated.”

Data regarding antimicrobial prophylaxis in veterinary patients is limited and conflicting, but in general, it has not been consistently associated with decreasing rates of infection in clean or clean-contaminated surgical procedures. Antimicrobials are toxic substances and the use of an antimicrobial with the premise that “it can’t hurt” is patently wrong. Inappropriate and over-use of antimicrobials promotes antimicrobial resistance, an increasingly important problem in both veterinary and human health care. Antimicrobial prophylaxis is not a substitute for asepsis, gentle tissue handling, meticulous haemostasis, judicious use of suture materials and accurate apposition of tissue without tension (Cimino Brown, 2012; Frey et al., 2022; Jessen et al., 2019). Surgical sterilisation procedures performed in a veterinary hospital by an experienced surgeon should be classified as “clean,” and antimicrobial prophylaxis is unwarranted.



Antimicrobial prophylaxis should be considered for procedures in clinical situations that may potentially increase risk of infection, or if an infection would have disastrous consequences. The only factors which have been consistently associated with infection rate in clean or clean-contaminated surgical procedures in veterinary patients are surgery and anaesthesia time (Beal et al., 2000; Brown et al., 1997; Eugster et al., 2004; Jessen et al., 2019). Surgical sterilisation procedures are generally of short duration, but this may not be true for procedures in large and/or obese dogs, especially performed by inexperienced operators (Vasseur et al., 1988). Other comorbidities that could potentially predispose to infection include endocrinopathies, advanced age (>8 years of age), abnormal body condition score (malnutrition, obesity) or immunosuppression (Jessen et al., 2019). SSI in a feral animal released immediately into the wild would likely have disastrous consequences, so antimicrobial prophylaxis should be considered in this situation.

If antimicrobial prophylaxis is employed, several rules must be strictly adhered to.

1. The antimicrobial should be effective against the organism(s) expected to be encountered during the surgical procedure. In the great majority of sterilisation procedures, the predicted contaminating microorganism would be a staphylococci species originating from the patient's skin. For this reason, a first-generation cephalosporin such as cefazolin (20 mg/kg IV) is often chosen. First generation cephalosporins have a low incidence of adverse side effects, favourable pharmacokinetics, low cost and are available in an intravenous form.
2. Studies in humans demonstrate repeatedly that if antimicrobial prophylaxis is to be effective, the antimicrobial must have therapeutic levels at the time the incision is made. To accomplish this, the antimicrobial must be given intravenously sometime in the 2 hours preceding surgery (Classen et al., 1992). Antimicrobials given by other routes or at different times have no demonstrated effect on infection rates after clean or clean/contaminated surgical procedures. Antimicrobials given inappropriately may actually increase the risk of infection with a resistant organism if an infection does occur.
3. The antimicrobial should not be administered beyond 24 hours after surgery.

## 2.4 | Surgical sterilisation and pain control

All surgical procedures are painful, and provision of adequate analgesia is mandatory in every situation. Many acceptable options are available for use with surgical sterilisation, and choice of the analgesic protocol will vary depending on the physical location where the procedure is being performed (hospital *versus* field), degree of surgical trauma, age and health of the patient, availability of certain medications and familiarity of the surgeon with the drugs being used. Management of surgical pain begins before surgery, is maintained through the surgical procedure and is continued afterwards. Multimodal management of pain is recommended for optimal analgesia. Local anaesthetic techniques (intraperitoneal, incisional, intratesticular and ovarian) are particularly appropriate as they may provide excellent analgesia without causing systemic side effects (Steagall et al., 2020).

Careful attention must be paid to drug dosing, especially in very small patients. In very large and very small patients, calculating drug doses based on body surface area or metabolic scaling is recommended to improve accuracy (Griffin et al., 2016). For situations in which an accurate bodyweight cannot be obtained before drug administration, such as programmes serving feral cats, safety is increased by using reversible agents, avoiding drugs that result in marked cardiorespiratory depression and estimating bodyweight as accurately as possible (Griffin et al., 2016).

Specific analgesic guidelines and protocols to consider for surgical sterilisation in both dogs and cats are published by the World Small Animal Veterinary Medical Association (WSAVA) in a separate document, available at: <https://wsava.org/global-guidelines/global-pain-council-guidelines/>

## 3 | NON-SURGICAL STERILISATION IN DOGS AND CATS

### 3.1 | Hormonal downregulation

#### 3.1.1 | GnRH agonists and antagonists

GnRH is a decapeptide produced by the hypothalamus. GnRH controls the synthesis and release of luteinizing hormone (LH) and follicle-stimulating hormone (FSH) from the anterior pituitary. In males, LH regulates testosterone synthesis, which is needed for the maintenance of spermatogenesis. Testosterone is also needed for the development of secondary sexual characteristics, including behavioural characteristics such as territorial marking (spraying), mounting and inter-male aggressiveness. In males, FSH regulates oestradiol synthesis and is necessary for the initiation and maintenance of spermatogenesis. In females, both LH and FSH are required for folliculogenesis and regulate oestradiol synthesis. In addition, LH induces ovulation and corpora lutea formation, regulates progesterone synthesis and is necessary for pregnancy maintenance during the last half of gestation.

Singular or multiple substitutions in the amino acid sequence of GnRH create molecules that can stimulate the effects of GnRH (agonist) or inhibit them (antagonist). There are several short-acting formulations of GnRH agonists (*e.g.* gonadorelin, buserelin, historelin) commercially available for use in veterinary medicine for ovulation induction in livestock and for treatment of cystic ovarian disease in cattle. There is only one commercially available long-acting formulation of a GnRH agonist labelled for use in dogs and cats (deslorelin) to induce reversible infertility.

**3.1.1.1.1 | GnRH agonist: Deslorelin:** Deslorelin acetate is a synthetic GnRH agonist that differs from native GnRH by two amino acid substitutions. After application of a subcutaneous implant, low doses of deslorelin are continuously released, initially stimulating LH and FH, but then the sustained activation of GnRH receptors suppresses LH and FSH synthesis and release. Commercially, the deslorelin implant comes in two strengths (4.7 mg and 9.4 mg) that vary in length of efficacy in male dogs for at least 6 and 12 months, respectively. The labelled application varies by country but includes induction of reversible infertility in male dogs and male cats as well as prepubertal female dogs.

**3.1.1.1.1.1 | Male dogs:** Subcutaneous administration of a 6.0 mg deslorelin implant reduces plasma LH and testosterone concentrations to undetectable values within 4 weeks (Junaidi et al., 2003) and reduces testicular size by about 50% of the pre-treatment size (Junaidi et al. 2009a; Junaidi et al. 2009b). Subcutaneous administration of a 4.7 mg deslorelin implant significantly decreases the proportion of motile sperm, total sperm numbers and semen volume, resulting in infertility (Romagnoli et al., 2012). Spermatogenesis was suppressed for more than a year in the majority of male dogs that received doses of >0.25 mg of deslorelin/kg of bodyweight (Trigg et al., 2001). The 4.7 and 9.4 mg deslorelin implants reduce testosterone concentrations to below 0.1 ng/mL for at least 180 and 400 days, respectively (Trigg et al., 2006). In a few implanted dogs (2/7) GnRH/hCG stimulation increased testosterone to measurable levels (Stempel et al., 2022a). Serial administration of multiple implants at 6-month intervals did not diminish efficacy (Romagnoli et al., 2023; Trigg et al., 2006). For small dogs (weighing <10 kg) administered a 4.7 mg deslorelin implant, testosterone concentrations may be suppressed for over 2 years (Trigg et al., 2006). This suggests an effect of bodyweight on the duration of action of the deslorelin implant.

Treatment-induced effects on male fertility are completely reversible (Dube et al., 1987; Trigg et al., 2001). Testosterone concentrations returned to normal within 2 weeks (Stempel et al., 2022b), prostate volume within 7 weeks and semen quality returned within 2–4 months following implant removal (Trigg et al., 2001; Stempel et al., 2022b). Side effects observed in male dogs include an acute increase in serum testosterone concentration (known as a “flare up” effect), which results from the initial stimulatory effect deslorelin has on LH and FSH. This increase in testosterone may cause transitory changes in behaviour, including increased aggression towards male dogs and increased sexual behaviour (De Gier et al., 2013), particularly in overly active or slightly unstable dogs. This can be prevented by administering cyproterone acetate (2 mg/kg BID) for 14 days (Masson et al., 2021).

Treatment of 4-month-old prepubertal male dogs with a 4.7 mg or 9.4 mg deslorelin implant postponed puberty until 2.5 and 3.2 years of age, respectively (Sirivaidyapong et al., 2012). Administration of two 9.4 mg deslorelin implants to 1-day-old puppies also significantly postponed puberty without affecting height or bodyweight compared to untreated litter mates (Faya et al., 2018). Side effects observed in treating prepubertal (1-day-old) male dogs with two 9.4 mg deslorelin implants included a delay in testicular descent and/or the development of bilateral cryptorchidism (Faya et al., 2018). This side effect was not reported when older (4-month-old) male dogs were treated with either one 4.7 or 9.4 mg deslorelin implant (Sirivaidyapong et al., 2012).

**3.1.1.1.2 | Female dogs:** In prepubertal female dogs, administration of a 9.4 mg deslorelin implant can delay puberty until 20 months of age or older and then be followed by normal fertility (Gontier et al., 2022; Kaya et al., 2015; Lacoste et al., 1989). Neither body development (height, humeral length) nor bodyweight was affected by puberty postponement in female dogs, despite a significant delay in epiphyseal closure (Kaya et al., 2015).

In postpubertal female dogs, postponement of oestrus for periods of up to 27 months was observed (Trigg et al., 2001). However, in about half of the female dogs, the length of oestrus postponement was similar to the interoestrus interval and an “actual” oestrus postponement was not observed (Trigg et al., 2001). The predominant disadvantage for treating postpubertal female dogs with a deslorelin implant is an induction of a potentially fertile oestrus that occurs within 1 to 4 weeks following implant administration, like the “flare up” reported in dogs (Borges et al., 2015). To avoid this effect, deslorelin treatment should be initiated before the female dogs is 4 months of age, within a period of 60 days following an ovulatory oestrus, within 7 days of parturition or following 7 days of oral exogenous progestin treatment (*e.g.* megestrol acetate 2 mg/kg/day) (Romagnoli et al., 2009; Sung et al., 2006; Wright et al., 2001). It is important to mention that the “flare up” effect can occur even when serum progesterone exceeds 60 ng/mL (Corrada et al., 2006; Fontaine & Fontbonne, 2011; Maenhoudt et al., 2012; Palm & Reichler, 2012).

The administration of deslorelin in adult female dogs may cause two types of side effects. The first type of side effect is due to suppression of the HPG axis with consequent deprivation of gonadal hormone secretion. Clinical manifestations associated with this side effect include weight gain, coat and behavioural changes, pseudocyesis, urinary incontinence and cystitis (Brändli et al., 2021). These effects are not unexpected as hormonal downregulation with deslorelin results in a similar change in gonadal hormone concentrations



as surgical gonadectomy. However, these changes are reversible as they generally disappear once the deslorelin treatment is discontinued. The second type of side effect may result from a pre-existing reproductive disease that is exacerbated by the initial stimulation to the HPG axis from deslorelin. Clinical manifestations associated with this side effect include uterine diseases, persistent oestrus, follicular cysts and ovarian neoplasia, which are mainly reported in older female dogs (Arlt et al., 2011; Palm & Reichler, 2012) but can occur in younger female dogs as well (Brändli et al., 2021). The high concentrations of LH and FSH that are released during the flare up reaction may precipitate subclinical ovarian or uterine conditions, which are common in intact older female dogs (Arlt & Haimel, 2016) and unusual in younger female dogs (Sforza et al., 2003; Troisi et al., 2023). For this reason, the off-label use of deslorelin for oestrus suppression in older female dogs is not recommended due to the high frequency of underlying uterine or ovarian diseases in these patients. However, more research is needed to clarify the role of deslorelin in the development of these side effects.

**3.1.1.1.3 | Male cats:** Following administration of a 4.7 mg deslorelin implant to male cats, there is an initial rise in serum testosterone concentrations followed by a slow and highly variable reduction in serum testosterone concentrations to <0.1 ng/mL over 3 to 11 weeks (Goericke-Pesch et al., 2011; Gültiken et al., 2017). The reduction in testosterone concentration is followed by a reduction in testicular volume and sexual behaviour (including urine marking) (Goericke-Pesch et al., 2011; Novotny et al., 2012). Both the 4.7 mg and 9.4 mg deslorelin implants reversibly decrease semen volume, sperm progressive motility, sperm concentration and normal sperm morphology in male cats (Gültiken et al., 2017; Novotny et al., 2012; Novotny et al., 2015; Romagnoli et al., 2017). The site of implant insertion (intrascapular *versus* periumbilical) did not influence duration of suppression of testosterone secretion (Romagnoli et al., 2019). Severe oligozoospermia and asthenozoospermia occurs within 70 days after deslorelin implant administration (Novotny et al., 2015; Romagnoli et al., 2017). Duration of infertility ranges from 6 to 28 months following deslorelin implant administration, depending on deslorelin strength (4.7 mg *versus* 9.4 mg) and breed (Furthner et al., 2020). Following implant removal, fertility is completely restored 60 to 90 days later (Ferré-Dolcet et al., 2020a; Goericke-Pesch et al., 2011, 2014; Novotny et al., 2015; Romagnoli et al., 2019).

**3.1.1.1.4 | Female cats:** Administration of a 4.7 mg deslorelin implant to prepubertal female cats significantly postponed puberty by an average of 4 months (Risso et al., 2012). In postpubertal female cats, the duration of efficacy of deslorelin treatment (4.7 mg and 9.4 mg) is variable and can last for over 3 years in some female cats (Goericke-Pesch et al., 2013; Toydemir et al., 2012). After the end of deslorelin implant efficacy or after implant removal, postpubertal female cats returned to normal cyclicity and fertility within 3 to 6 months depending on season (Goericke-Pesch et al., 2013). Associated with the “flare-up” effect, administration of a deslorelin implant frequently induces fertile oestrus with ovulation in peripubertal and postpubertal female cats (Ackermann et al., 2012; Goericke-Pesch et al., 2013; Munson et al., 2001; Toydemir et al., 2012; Zambelli et al., 2015). Other reported complications in adult female cats that can occur within a few weeks after deslorelin implant treatment include persistent oestrus, CEH, lactation and mammary fibroadenomatous hyperplasia (Furthner et al., 2020). Similarly to the bitch, these side effects may result from a pre-existing condition which is exacerbated by deslorelin (such as CEH), or be the result of corpora lutea development following ovulation induced by deslorelin (such as lactation and mammary fibroadenomatous hyperplasia). Persistent oestrus is a rare condition in deslorelin-treated queens whose pathogenesis has so far not been elucidated (Ferré-Dolcet et al., 2022). Weight gain has also been reported a few months after deslorelin implant treatment (Munson et al., 2001).

**3.1.1.2 | GnRH antagonists: acyline and antide:** Unlike GnRH agonists, GnRH antagonists directly block pituitary GnRH receptors, resulting in an immediate suppression of LH and FSH synthesis and secretion without the “flare up” effect (Heber et al., 1982; Herbst, 2003; Vickery, 1985). However, GnRH antagonists require high doses to competitively inhibit responses to endogenous GnRH (Vickery, 1985). The degree and duration of LH and FSH suppression depends on the amount of GnRH antagonist administered (Fraser, 1988). Although no GnRH antagonists are licensed for use in veterinary medicine, research has supported the use of acyline and antide in female dogs and female cats (Garcia Romero et al., 2012; Risso et al., 2010; Valiente et al., 2009a; Valiente et al., 2009b).

**3.1.1.2.1 | Female dogs:** Subcutaneous administration of acyline (0.11 to 0.33 mg/kg) to female dogs in the first 3 days of pro-oestrus postpones oestrus for 3 weeks without any side effects observed (Valiente et al., 2009a). However, acyline administration during the first 2 days following administration of a deslorelin implant (9.4 mg) did not prevent the “flare up” effect and ovulation was not prevented (Valiente et al., 2009b).

**3.1.1.2.2 | Cats:** Two subcutaneous injections of antide (6 mg/kg) 15 days apart will suppress ovarian activity in female cats within 17 to 56 days (Pelican et al., 2005). In addition, one subcutaneous injection of acyline (330 µg/kg) to female cats postpones oestrus and ovulations for about 18 days (Risso et al., 2010). However, the same treatment administered to male cats had no effect on testosterone concentrations but did impair spermiogenesis (Garcia Romero et al., 2012).

### 3.1.2 | Progestogens

Progestogens have been used for oestrus postponement in female dogs and female cats for decades. Efficacy as well as adverse effects depend upon the type of progestogen administered, dose, timing of treatment relative to the stage of the oestrous cycle, treatment regimen and age, reproductive health and systemic health of the animal.

**3.1.2.1 | Megestrol acetate:** Megestrol acetate (MA) is a synthetic progestogen available as an oral medication (pills or syrup). MA is a short-acting compound, with a half-life of only a few hours. MA has an affinity for the progesterone receptor that is 15 to 25 times greater than endogenous progesterone. MA also has a high affinity for the androgen receptor and glucocorticoid receptor (Jänne et al., 1978; Schindler et al., 2003).

**3.1.2.1.1 | Female dogs:** Administration of MA at 0.01 mg/kg/day orally for 154 days postponed oestrus in 50% of female dogs (Harris & Wolchuk, 1963). Administration of MA at 0.05 mg/kg/day orally for 365 days postponed oestrus in 80% of female dogs (Harris & Wolchuk, 1963). Return to oestrus following MA administration with the 0.05 mg/kg/day dosage was 70.5 days (range 28 to 111 days) (Harris & Wolchuk, 1963). Administration of MA at 0.55 mg/kg/day orally for 32 days effectively suppressed oestrus in 98% of late anoestrous female dogs for 120 to 180 days (range 30 to 210 days) (Burke & Reynolds Jr, 1975). When given at low dosages, MA can be administered daily for up to 1 year without side effects (Harris & Wolchuk, 1963).

When given for eight consecutive days at 2.2 mg/kg/day in the first 3 days of pro-oestrus, MA is effective at postponing oestrus in 92 to 97% of female dogs, within 3 to 8 days (Burke & Reynolds Jr, 1975; Concannon & Meyers-Wallen, 1991; Wildt et al., 1977). Effectiveness varies in female dogs with very short or very long pro-oestrus periods (Burke & Reynolds Jr, 1975; Concannon & Meyers-Wallen, 1991; Wildt et al., 1977). The interval from treatment to return to oestrus ranges from 1 to 9 months (mean: 4 to 6 months) and fertility following treatment is usually normal (Concannon & Meyers-Wallen, 1991; Wildt et al., 1977). Treating female dogs for three or more consecutive cycles or at the pubertal oestrus has the potential to negatively affect fertility (Romagnoli & Lopate, 2017).

The use of MA at a dose of 0.25 to 2.2 mg/kg/day may stimulate appetite and result in weight gain in female dogs. Some female dogs may exhibit mild mammary and endometrial enlargement, mammary nodules and elevated serum glucose concentrations (Evans & Sutton, 1989; Nelson et al., 1973; Weikel et al., 1975; Wildt et al., 1977). Incidence of pyometra using the above intermediate to high dosages for 8 days was 0.8% of female dogs (Burke & Reynolds Jr, 1975; Wildt et al., 1977). When used at dosages higher than 2.2 mg/kg/day or treatment lengths longer than 8 days, MA can induce insulin resistance and may cause adrenocortical suppression (Beck, 1977; Van den Broek & O'Farrell, 1994; Weikel & Nelson, 1977).

**3.1.2.1.2 | Female cats:** Oestrus postponement with MA is successful in female cats when MA is given at very low dosages. An MA dose of 2.5 mg given as one pill/week/adult female cat (corresponding to 0.625 mg/week or 0.009 mg/kg/day for a 4 kg female cat) is effective at oestrus postponement and safe for up to 30 weeks (Houdeshell & Hennessey, 1977; Oen, 1977). At this dosage, reported side effects from MA were increased appetite and bodyweight, occurring in 33 and 13% of treated female cats, respectively (Houdeshell & Hennessey, 1977; Oen, 1977). Additional side effects from MA at this dosage were temperament change and mammary enlargement (Romagnoli, 2015). A formulation of MA labelled for female cats is commercially available in some countries with a prescribed oral dosage of 0.011 mg/kg/day and a maximum duration of treatment of 12 months.

Short-lasting adrenocortical suppression (Chastain et al., 1981; Middleton et al., 1987) and impairment of glucose metabolism (Middleton & Watson, 1985; Moise & Reimers, 1983; Peterson, 1987) have been reported in female cats treated with 0.625 mg/kg/day for 1 week or every other day for 2 weeks. Serious and long-lasting endocrine and glucose metabolic effects occurring when the above dosage is given for prolonged periods result from the interaction of MA with the glucocorticoid receptor. At the 0.625 mg/kg/day dosage given daily for weeks or every other day for months, female cats have developed mammary gland lesions (mammary hyperplasia, as well as benign and malignant tumours), skin lesions (cutaneous xanthomatosis), blindness (due to hyperlipidaemia causing opacity of the anterior chamber) and uterine lesions (CEH, pyometra, adenomyosis), as well as more severe and longer lasting endocrine side effects (diabetes and adrenocortical suppression) (Bellenger & Chen, 1990; Bulman-Fleming, 2008; Ellis, 1975; Ghaffari, 2008; Hayden et al., 1981, 1989; Hinton & Gaskell, 1977; Long, 1972; MacDougall, 2003; Orhan, 1972; Pukay & Stevenson, 1983; Remfry, 1978; Skerritt, 1975; Teale, 1972; Walker, 1975; Watson et al., 1989; Wilkins, 1972).

**3.1.2.1.3 | Male dogs:** In dogs, daily oral MA treatment (2 mg/kg) for 7 days produced no change in semen quality and increasing the dosage to 4 mg/kg produced only minor secondary sperm abnormalities (England, 1997). Unlike in female dogs, changes in insulin resistance and adrenocortical suppression have not been reported in dogs, although further research is needed.



**3.1.2.2 | Medroxyprogesterone acetate:** Medroxyprogesterone acetate (MPA) was the first synthetic progestogen commercially available for veterinary use. MPA is longer-acting than MA with a half-life of 12 to 17 hours when administered orally or 40 to 50 days when injected (Romagnoli, 2015). MPA has an affinity five times higher than endogenous progesterone for the progesterone receptor. MPA has an affinity 100 and 1000 times lower than MA for the androgen and glucocorticoid receptor, respectively (Selman et al., 1996).

**3.1.2.2.1 | Female dogs:** MPA administered orally to female dogs at 0.01 or 0.05 mg/kg/day for 1 year resulted in no cases of breakthrough oestrus (Harris & Wolchuk, 1963). Return to oestrus following MPA administration with the 0.01 mg/kg/day dosage was 93.8 days (range: 22 to 243 days) and with the 0.05 mg/kg/day dosage was 211.7 days (range 116 to 311 days) (Harris & Wolchuk, 1963). MPA has also been administered subcutaneously to female dogs at dosages of 1.5 mg/kg every 13 weeks, 2 mg/kg every 3 months, 3 mg/kg every 4 months or 2.5 mg/kg every 5 months for oestrus postponement (Concannon, 1995, 2013; Evans & Sutton, 1989; Jordan, 1994).

Parenteral MPA treatment at dosages under 2 mg/kg every five to 6 months is anecdotally safe in female dogs under 2 years of age for up to three consecutive treatments, provided that liver and kidney function are normal and there is no clinical or ultrasonographic evidence of uterine or mammary lesions before treatment (Romagnoli & Lopate, 2017). However, long-term studies about the safety of repeated low doses (under 2.0 mg/kg) parenteral MPA treatment are needed. Parenteral MPA treatment at dosages over 2.5 mg/kg or any dosage given more frequently than every 5 months to female dogs increases the risk of benign and malignant mammary tumours, CEH, insulin resistance, diabetes mellitus, hyperinsulinemia and acromegaly (due to increased growth hormone secretion from mammary tissue) (Beijerink et al. 2007a; Bhatti et al., 2007; Concannon et al., 1980, 1981; Kim & Kim, 2005; McCann et al., 1987).

**3.1.2.2.2 | Female cats:** Oral administration of MPA to female cats at dosage of 0.05 mg/kg/day safely and effectively postpones oestrus for up to 12 months, with only mild adverse effects on fertility at the first post-treatment pregnancy but not at subsequent pregnancies (Harris & Wolchuk, 1963). Repeated treatment and/or long-term observation was not performed. However, parenteral administration of MPA at 1.6 to 6.25 mg/kg (Colton, 1965), resulted in uterine and mammary pathologies in female cats (Enginler & Senunver, 2011; Hernandez et al., 1975; Loretto et al., 2005; Thornton & Kear, 1967). Even at these high dosages, MPA is rarely diabetogenic or adrenal suppressive compared to overdosing female cats with MA (Romagnoli, 2015).

**3.1.2.2.3 | Male dogs:** Like MA, MPA administered subcutaneously at 10 mg/kg (England, 1997) does not adversely affect fertility in dogs. However, subcutaneous administration of MPA at 20 mg/kg significantly decreased sperm motility, morphology and concentration within 3 days (England, 1997). Because of the rapidity of the response, the author postulated the effect was mediated by direct actions of MPA on epididymal spermatozoal maturation and transport. In another study, LH was suppressed for only very brief periods and histological changes were seen mainly in the epididymal head (Paramo et al., 1993). In this study, the acrosome was detached from the sperm head except in the most anterior area, with the detached portion of the acrosome forming a fan-like projection (Paramo et al., 1993). Adverse effects were not reported following MPA treatment in dogs.

### 3.1.3 | Androgens

**3.1.3.1 | Mibolerone:** Mibolerone is a synthetic androgen that was commercially marketed in North America for oestrus postponement in dogs and cats and withdrawn from the market at the end of the last century due to its potential for human abuse (Burke et al., 1977). Mibolerone is available through compounding pharmacies.

**3.1.3.1.1 | Female dogs:** The oral dose for mibolerone in female dogs varies with bodyweight and breed. For female dogs up to 12, 12 to 23, 23 to 45 and over 45 kg, the mibolerone dosage is 30, 60, 120 and 180 mg/day, respectively. Any German shepherd dog (Alsatian)-derived purebred or mixed breed should receive the maximum daily dosage (180 mg/day). The reason for the higher dosage requirement within Alsatian lineage is unknown. If treatment is initiated at least 30 days before the onset of pro-oestrus, oestrus can be postponed for up to 2 years with continuous therapy. Oestrus postponement with mibolerone is commonly used following medical management of pyometra, when administering progestogens for oestrus postponement would be contraindicated.

Following cessation of the treatment, return to oestrus occurs within 70 days (range 1 to 7 months). Continuous treatment up to 5 years has been reported, but it is generally not recommended to treat continuously for more than 24 months. Reported side effects in female dogs include clitoral hypertrophy, vaginitis, increased body odour, mounting behaviour and epiphora (Burke, 1982; Sokolowski & Geng, 1977). Mibolerone should not be used in pregnant female dogs, females with hepatic or renal dysfunction or Bedlington terriers.

**3.1.3.1.2 | Female cats:** The oral dosage for mibolerone is 50 mg/cat/day as lower doses do not postpone oestrus (Burke et al., 1977). However, this dose approaches toxicity, and hepatic dysfunction has been reported with 60 mg/cat/day, with mortality ensuing at doses of 120 mg/cat/day (Burke, 1982). Cervical skin thickening and clitoral hypertrophy developed in mibolerone-treated female cats, which did not resolve after withdrawal (Burke et al., 1977). For these reasons, progestogens are preferred to mibolerone for oestrus postponement in female cats.

**3.1.3.2 | Other androgens:** A variety of other androgens have been used for oestrus postponement in female dogs, but their administration raises doping concerns because of the competitive enhancements of the anabolic steroids. Before administering any androgen, female dogs should be healthy, in anoestrus, not pregnant and have normal hepatic function. Oral administration of methyltestosterone (1 mg/kg) twice weekly is effective at oestrus postponement in female dogs (Blythe et al., 2007; Gannon, 1976).

Oral administration of methyltestosterone at 50 mg/dog/day to intact adult male greyhounds for 90 days also resulted in decreased mean daily sperm output and mean testicular length that returned to normal 90 days after the end of treatment (Freshman et al., 1990). As with mibolerone, oestrus postponement with androgens is commonly used following medical management of pyometra, when administering progestogens for oestrus postponement would be contraindicated.

### 3.1.4 | Melatonin

**3.1.4.1 | Female cats:** The domestic female cat is a seasonal long-day breeder, meaning that reproductive activity is influenced by photoperiod. Female cats cease oestrous cyclicity when the photoperiod is reduced from fourteen hours to eight hours and oestrous cycles resume 12 to 26 days ( $15.6 \pm 0.5$  days) after the photoperiod is increased from eight hours to fourteen hours (Leyva et al., 1989a). Melatonin is a neurohormone produced by the pineal gland in a circadian rhythm of secretion with greater concentrations during periods of darkness (Reiter, 1991). Decreasing photoperiod results in high endogenous melatonin concentrations, stopping oestrous cyclicity in female cats. Administration of oral or parenteral melatonin will mimic this situation. Melatonin tablets are readily available over the counter in pharmacies and vitamin stores world-wide, but the purity of the active ingredient may be not regulated. Melatonin implants are commercially available for veterinary use in a limited number of countries. Unlike oral melatonin administration, melatonin implants maintain constant serum melatonin concentrations.

Administration of oral melatonin (30 mg) daily 3 hours before 12 hours of darkness to female cats for 35 days postponed oestrous cyclicity (Graham et al., 2004). Oestrous cyclicity returned to normal 21 to 40 days after the end of treatment (Graham et al., 2004). It is important to note that lower doses of melatonin (<30 mg) do not postpone oestrous cyclicity (Faya et al., 2011). Female cats administered a melatonin (18 mg) implant had rapid and prolonged oestrus postponement lasting for about 2 to 4 months (Faya et al., 2011; Gimenez et al., 2009; Schäfer-Somi, 2017). Melatonin implants containing 12 mg suppressed oestrus in two out of four female cats for an average of 75 days (range: 53 to 94 days). Administration of five implants was effective in three of four female cats but did not prolong duration of effectiveness (Griffin et al., 2001). The authors emphasised the highly individualised dosage required (Griffin et al., 2001). To improve the efficacy of the 18 mg melatonin implant, it should be administered during interoestrus because high oestrogen concentrations during pro-oestrus and oestrus interfere with responses to both endogenous and exogenous melatonin (Lincoln et al., 2005). If the melatonin implant is administered during oestrus, oestrus postponement may be delayed 5 to 30 days and the duration of oestrus postponement is reduced by about half (Gimenez et al., 2009; Graham et al., 2004; Leyva et al., 1989b). Melatonin (18 mg) implants administered to prepubertal female cats do not affect growth (Faya et al., 2011).

Oestrus lasting for 1 to 10 days with ovulation and pseudopregnancy has been reported after melatonin (18 mg) implant administration during interoestrus (Gimenez et al., 2009; Schäfer-Somi, 2017). In addition, CEH has been reported in female cats receiving melatonin (12 mg) implants, but it is not known if these pathologies existed before implant administration (Griffin et al., 2001). However, female cats can be fertile following treatment with melatonin implants and produce healthy offspring (Schäfer-Somi, 2017).

**3.1.4.2 | Male cats:** Unlike female cats, male cats remain fertile and produce semen throughout the year with minimal seasonal variation (Blottner & Jewgenow, 2007; Nuñez-Favre et al., 2012; Stornelli et al., 2009; Tsutsui et al., 2009). Administration of melatonin (18 mg) implants to male cats did not induce infertility (Nuñez-Favre et al., 2014).

## 3.2 | Immunocontraceptives

### 3.2.1 | Immunisation against gonadotropin-releasing hormone

Antibody titres against GnRH suppress reproductive behaviour, suppress synthesis and secretion of gonadotropins (LH, FSH) and steroid hormones (oestrogen, testosterone), and result in gonadal atrophy (Jung et al., 2005; Ladd et al., 1994). However, develop-



ment of a GnRH immunocontraceptive vaccine is problematic because GnRH is not naturally immunogenic. Vaccine formulations are designed to increase the antigenicity of a GnRH-conjugate. Research in dogs and cats with GnRH vaccines date back three decades and there have been dozens of vaccines designed for research trials that have never been commercialised. There are currently two GnRH vaccines commercially manufactured.

**3.2.1.1 | GnRH-conjugated to keyhole limpet haemocyanin:** This vaccine is approved for use in the USA for wild white-tailed deer and prairie dogs as well as feral horses. The formulation consists of two components that are mixed to form an emulsion for injection. GnRH is conjugated to a mollusc-derived carrier protein (keyhole limpet haemocyanin or blue protein) (Bender et al., 2009) that is contained within a mollusc stabilising buffer (Gionfriddo et al., 2011). Three additional amino acids are added to GnRH to act as a spacer and to facilitate conjugation to the carrier protein. The second component is a mineral oil-based adjuvant that contains killed *Mycobacterium avium*, which induces both a local inflammatory response and a prolonged immune response, as well as significant injection site reactions.

**3.2.1.1.1 | Male dogs:** Sixty-six percent (2/3) vaccinated dogs (0.6 mL IM once) developed infertility within 3 to 4 weeks after immunisation that persisted for about 14 weeks (Griffin et al., 2004). All three vaccinated dogs experienced severe injection site reactions that persisted throughout the duration of the study.

**3.2.1.1.2 | Female dogs:** All vaccinated female dogs (0.5 mL IM once; n=7 GnRH vaccine alone and n=7 GnRH vaccine in combination with a rabies vaccine) had progesterone concentrations that remained below 1 ng/mL for 60 days but no other fertility assessments were made (Vargas-Pino et al., 2013). Additionally, 70% of these vaccinated female dogs had focal to severe diffuse chronic granulomatous myositis or diffuse coagulative necrosis in the injected muscle site. Long-term effects of vaccination were not determined because female dogs were euthanased 60 days after vaccination.

**3.2.1.1.3 | Male cats:** Sixty-six percent (6/9) vaccinated male cats (IM once) developed infertility secondary to azoospermia or severe asthenozoospermia within 3 months that persisted until the end of the experiment (Levy et al., 2004). However, the reversibility of the vaccine in this study was not determined because male cats were castrated at 6 months after vaccination. No side effects were reported in the male cats of this study.

**3.2.1.1.4 | Female cats:** All female cats vaccinated with a GnRH vaccine in combination with a rabies vaccine (n=5) had a significant reduction in anti-Müllerian hormone serum concentrations and evaluation of vaginal cytology and ovarian histology suggested that reproductive cyclicity was suppressed (Novak et al., 2021). Female cats immunised with a GnRH vaccine (n=15; 0.5 mL IM once) were introduced to fertile male cats 4 months after vaccination (Levy et al., 2011). Compared to controls, vaccinated female cats in this study had a significantly longer time to conception (39.7 months *versus* 4.4 months). A total of 93% of vaccinated female cats remained infertile for the first year following vaccination, whereas 73, 53, 40 and 27% were infertile for 2, 3, 4 and 5 years, respectively (Levy et al., 2011). Non-painful but persistent late-onset granulomatous injection site masses appeared 2 years after initial vaccination in five female cats from this study. In a separate study with a similar experimental design, 60% (12/20) of vaccinated female cats became pregnant within 4 months and 45% (9/20) had injection-site reactions ranging from swelling to transient granulomatous masses (Fischer et al., 2018). Injection site masses were also reported in 67% (4/6) of vaccinated female cats, with the average number of days from vaccination to mass development of 110 days (range: 18 to 249 days) (Vansandt et al., 2017).

**3.2.1.2 | GnRH-conjugated to diphtheria toxin:** This vaccine is available in most countries and labelled for boars intended for slaughter for temporary immunocastration and reduction of boar taint. Each 1 mL of vaccine contains 0.2 mg GnRH-conjugated to diphtheria toxoid and an adjuvant (150 mg of diethylaminoethyl-dextran hydrochloride and 1 mg chlorocresol). Serum testosterone concentrations in male cats dropped to basal levels 6 weeks after vaccination (n=9; 0.5 mL SQ twice at 4 weeks apart) (Ochoa et al., 2023). In addition, there was a progressive decrease in testicular volume, penile spines and semen quality from 8 weeks after vaccination until 24 weeks (end of study). However, the reversibility of the vaccine in this study was not reported.

## 3.2.2 | Immunisation against zona pellucida

The zona pellucida (ZP) is a protective layer of proteinaceous, acellular, gelatinous material that covers the outer surface of the ova in mammals. Fertilisation begins with sperm binding to the ZP type 3 (ZP3) receptor. Porcine ZP3 (pZP3) is commonly used for research and commercial vaccine development for domestic and wild mammalian species. For reasons explained below, pZP3 vaccines are not appropriate for use in female dogs and female cats.

**3.2.2.1 | Female dogs:** Vaccination of female dogs (n=4) against pZP3 prevented pregnancy in 75% of vaccinated female dogs exposed to fertile dogs (Srivastava et al., 2002). Reversibility of this vaccine was not evaluated in this study but ovarian histopathology revealed inhibition in follicle development and atretic changes to the zona pellucida. This was supported by a separate study showing serum progesterone concentrations remaining low during oestrus in pZP3-vaccinated female dogs, suggesting ovulation failure as the cause of infertility rather than impairment of sperm binding sites (Mahi-Brown et al., 1982). In addition, two of pZP3-vaccinated female dogs (n=3) in this study developed prolonged pro-oestrous bleeding and oestrous behaviour. Ovarian histopathology revealed ovarian cysts with autoimmune oophoritis (Mahi-Brown et al., 1988).

**3.2.2.2 | Female cats:** Female cats vaccinated against pZP3 produce high anti-pZP3 titres, but these antibodies have a low affinity for feline ZP3 protein and as a result, pZP3 vaccination does not prevent oestrous cyclicity or pregnancy in female cats (Gorman et al., 2002; Levy et al., 2005).

### 3.2.3 | Immunisation against GnRH and ZP

A preliminary vaccination trial combining GnRH and dog ZP3 (dZP3) antigens was conducted on two female dogs (Gupta et al., 2022). Three vaccinations 4-weeks apart resulted in significant antibody titres and a booster dose on day 383 led to an increase in antibody titres that were maintained until day 528. Although mating studies resulted in pregnancies, the number of pups born following dZP3-GnRH immunisation was reduced. Additional research with a larger sample size and control group is needed before the merits of this approach can be determined.

## 3.3 | Chemical castration

Male dogs and cats can be sterilised following injection of chemical agents injected into the testis, epididymis or vas deferens. This technique gradually induces azoospermia as well as a variable reduction in testosterone concentrations. Intratesticular injection is not technically challenging, does not require general anaesthesia, is inexpensive and is suitable for large-scale sterilisation programmes (Pineda et al., 1977). Intraepididymal injections can be delivered into the tail or head of the epididymis and may require general anaesthesia and ultrasound guidance, especially when performed in male cats. Intratesticular injection results in minimal signs of discomfort as afferent nerve endings associated with pain sensation are located on the scrotal skin and in the capsule of the testis rather than within the testicular and epididymal parenchyma. Local and systemic adverse reactions occur infrequently following intratesticular and intraepididymal injections. Currently, there are no long-term safety and efficacy studies on intratesticular or intraepididymal injections as a non-surgical sterilisation option for male dogs or cats.

### 3.3.1 | Intratesticular injection

**3.3.1.1 | Calcium chloride:** Ingredients to prepare the calcium chloride solution for intratesticular injection (e.g. sterile analytical grade calcium chloride) are readily available in many countries (Golden, 2014). However, the formulation, concentration and volume of the calcium chloride solution for intratesticular injection are not yet standardised. Effectiveness of the calcium chloride solution appears to vary from no change to complete destruction of sperm production depending on volume, vehicle and calcium chloride concentration (Golden, 2014).

Intratesticular injections of calcium chloride should be performed using a sterile needle directed from the ventral aspect of each testis approximately 0.5 cm from the epididymal tail towards the cranial aspect of that testis. The calcium chloride solution (volume depends on testicular mass) should be carefully deposited along the entire route by linear infiltration while withdrawing the needle from the proximal to distal end.

Intratesticular injection of a calcium chloride solution induces intratesticular oedema, necrosis and fibrosis, which causes degeneration of seminiferous tubules (and germ cells) and the interstitial (Leydig) cells. In addition, intratesticular injection of a calcium chloride solution induces free radicals produced within testicular tissue following the injection leading to lipid peroxidation and destruction of other cellular structures (Jana et al., 2005).

**3.3.1.1.1 | Male dogs:** Five concentrations (0%, 10%, 20%, 30%, 60%) of calcium chloride in saline were administered via intratesticular injection to groups of 10 dogs each (Leoci et al. 2014b). Total sperm count, semen volume and testosterone concentration showed significant dose-dependent decreases with 10 to 60% calcium chloride compared to the control group (0% calcium chloride) or baseline for each calcium chloride group. In this study, azoospermia was achieved until the end of the study (12 months) following the injection in 60 and 80% of treated dogs after administration of a 10 and 20% calcium chloride, respectively. Calcium chloride at a 30 or 60% concentration resulted in azoospermia in 100% of dogs, but more side effects were



observed, while no side effects were noticed at lower doses (Leoci et al. 2014b). For each treatment group in this study, testosterone concentrations decreased an average of 35 to 70% at 6 months following treatment. However, testosterone concentrations rebounded by the 12-month time point in all groups except the 60% calcium chloride group, which remained at the low end of physiological range throughout the study (Leoci et al. 2014b). Sperm motility dropped to zero or near zero in all dogs treated with calcium chloride in this study. In addition, testicular size was significantly smaller at 12 months post injection for all groups in this study when compared to baseline. Leoci et al. (2019) then administered 20% calcium chloride in 95% ethanol intratesticularly (n=37 dogs) and no adverse effects were reported. All dogs treated with calcium chloride in this study became sterile with azoospermia achieved over the 9-month study period. Serum testosterone concentrations significantly decreased following intratesticular treatment with calcium chloride (Leoci et al., 2019).

Calcium chloride at a 7.5% concentration in 0.5% dimethyl sulfoxide was injected into each testis of six dogs (Silva et al., 2018). Following injection, pain was observed by testicular palpation in one dog from this study and this dog received analgesic therapy. An increase in testicular volume was evident within 24 hours after treatment, followed by gradual reduction for 3 weeks (Silva et al., 2018). Five of six dogs from the treated group in this study had azoospermia 15 days after injection and the remaining dog developed azoospermia 30 days after injection. There was no significant difference in testosterone concentrations during the 60-day experimental period (Silva et al., 2018). However, the histological evaluation showed testicular degenerative lesions.

In another study, calcium chloride at 20% concentration in lidocaine solution (n=21) or alcohol (n=21) was administered via intratesticular injection to dogs (Leoci et al. 2014a). Testes of dogs treated with calcium chloride in either diluent significantly decreased in size. After administration of calcium chloride in lidocaine solution, sterility was achieved for the duration of the study (12 months) in 75% of treated dogs (Leoci et al. 2014a). However, all dogs in this study receiving intratesticular injections of calcium chloride in alcohol had azoospermia for the duration of the 12-month study period. Testosterone concentrations significantly decreased following either treatment with calcium chloride and sexual activity disappeared (Leoci et al. 2014a). Testosterone returned to pre-treatment concentrations by 12 months for the group treated with calcium chloride in lidocaine, whereas dogs injected with calcium chloride in alcohol had a 63.6% drop in testosterone level, which remained at the low end of physiological range throughout the study. No adverse effects were reported (Leoci et al. 2014a).

**3.3.1.1.2 | Male cats:** Intratesticular calcium chloride injection is reported to be well tolerated in male cats. Baran et al. (2010) injected 0.20 mL per testis of 0% (n=1), 5% (n=1), 10% (n=1) or 20% (n=1) calcium chloride and found that the 5% and 10% treated male cats were oligospermic (<20 million sperm/mL in ejaculate), whereas the 0% treated male cats had a normal ejaculate (>20 million sperm/mL). The 20% treated male cats did not ejaculate any sperm, and histologic evaluation showed degenerated germ cells and calcification of the seminiferous tubules and interstitial cells along with significant fibrosis at 60 days post-treatment (Baran et al., 2010).

Jana and colleagues (2011) injected a volume of 0.25 mL per testis of 0% (n=6), 5% (n=6), 10% (n=6) or 20% (n=6) calcium chloride in saline with 1% lidocaine. Mild discomfort could be observed one to five minutes after injection in this study. Testicular swelling was evident by 24 hours, peaking 2 to 4 days following injection and then decreasing over a period of 3 to 4 weeks (Jana & Samanta, 2011). In this study, the intratesticular injection of 5% calcium chloride induced dissolution of germ cells associated with atrophy of the seminiferous tubules but these effects were inconsistent throughout the testes. The intratesticular injection of 10% calcium chloride induced coagulative necrosis in the seminiferous epithelium and interstitial spaces with degenerated and coagulated germ cells present in combination with fibrous tissue in tubular and interstitial spaces (Jana & Samanta, 2011). Intratesticular injection of 20% calcium chloride solution resulted in complete testicular necrosis of the entire germinal epithelium, with only fibrous and hyaline tissue remaining. At 60 days post treatment, serum testosterone concentrations were an average of 2.15 ng/mL in the 20% calcium chloride group compared with 7.82 ng/mL in the 0% calcium chloride group (Jana & Samanta, 2011). These authors also reported a reduction in sex-linked behaviours following treatment.

Care should be taken to prevent seepage of calcium chloride solution from the injection site because, if the solution remains on or under the scrotal skin, tissue necrosis occurs (Jana & Samanta, 2011). These authors reported that if the solution was immediately wiped away, the complications may be avoided. Scrotal skin necrosis can also develop if an excessive volume is injected or leakage occurs outside of the tunica albuginea (Koger, 1978). Although sample sizes are small, no serious adverse effects were reported.

**3.3.1.1.2 | Zinc gluconate:** Zinc gluconate (13.1 mg zinc/mL) neutralised to pH 7.0 with 0.2 M L-arginine has been commercialised by several companies and distributed under several brand names. This formulation received USA Food and Drug Administration approval for use in puppies three to 10 months old but has been used off-label in older dogs and male cats (Oliveira et al., 2013). Although there is currently no product commercially available, the zinc gluconate solution can be prepared from raw ingredients (Rafatmah et al., 2019).

The procedure for intratesticular injection of zinc gluconate involves inserting a 27-gauge needle connected to a 0.5 mL U100 insulin syringe into one pole of the testis and gently pushing it towards the other pole. The solution is deposited homogeneously throughout the testis as the needle is withdrawn. Similar to calcium chloride, the needle for zinc gluconate should be inserted parallel

to the long axis of the testis. However, unlike calcium chloride, the needle for zinc gluconate should be inserted into the dorsal-cranial area of each testis, lateral to the caput epididymis (close to the rete testis and efferent ducts). No explanation is provided by investigators using either calcium chloride or zinc gluconate for the difference in direction of needle insertion.

In dogs, the zinc gluconate solution is administered intratesticularly at a rate of 0.3 mL for every 12 to 14 mm of testis width (Wang, 2002). In male cats, the zinc gluconate solution is administered intratesticularly at a rate of 1 mL for every 27 mm of testis width (Oliveira et al., 2013).

**3.3.1.2.1 | Male dogs:** Rafatmah et al. (2019) administered intratesticular injections of zinc gluconate to healthy adult dogs (n=5). The general health of all dogs was reported to be normal after the injection and post injection testicular swelling was limited to 2 days of treatment. In this study, the average diameter of the testes and serum concentration of testosterone did not change significantly. In a separate study of free-roaming dogs (n=36), testosterone concentrations remained unchanged compared to intact controls in 66% of the dogs receiving intratesticular injections (Vanderstichel et al., 2015). Following intratesticular injection with zinc gluconate, histopathological analyses revealed germ cell degeneration in the seminiferous tubules, but Leydig cells retained a normal structure (Rafatmah et al., 2019).

Vannucchi et al. (2015) investigated the efficacy of a double testicular injection of zinc gluconate associated with dimethyl sulfoxide (n=15) or 0.9% saline solution (control group; n=7). No clinical abnormalities or signs of pain were noted. However, the injection of zinc gluconate and dimethyl sulfoxide significantly reduced libido and testosterone concentrations (Vannucchi et al., 2015). Decrease in sperm count and sperm motility and an increase in major sperm defects were observed 15 days after the first intratesticular administration of zinc gluconate and dimethyl sulfoxide. Ultrasonography revealed reduced testicular volume and changes in testicular echotexture in treated animals. Histology revealed tissue degeneration, fibrosis and calcification of testicular parenchyma (Vannucchi et al., 2015).

During a behavioural study conducted in the Chilean Patagonia in 2012, severe necrosuppurative orchitis and ulcerative dermatitis were observed in 6% (2/36) of dogs sterilised with zinc gluconate according to the manufacturer's instructions, a week after the intratesticular injection (Forzán et al., 2014). Although this method of sterilisation dogs is relatively uncomplicated, the occurrence of severe adverse reactions several days after administration emphasises the need for the provision of long-term monitoring and veterinary care if using this method.

**3.3.1.2.2 | Male cats:** A single intratesticular injection of zinc gluconate (n=6) resulted in a seminiferous epithelium with an absence of germ cells in the basal and adluminal compartments of all treated male cats (Fagundes et al., 2014). Ultrastructural evaluation of Leydig cells revealed loss of nuclear chromatin, increased smooth endoplasmic reticulum, and mitochondria degeneration. Sertoli cells had various degrees of cytoplasmic vacuolization and the diameter of seminiferous tubules, epithelial height and tubular area were reduced compared to controls (Fagundes et al., 2014). In a separate study, a single intratesticular injection of zinc gluconate (n=11) resulted in azoospermia in 91% (10/11) of male cats by day 60 and reduced testicular size by day 120 (Oliveira et al., 2013). By day 120, penile spines were absent in 36% of treated male cats and reduced in another 54% of treated male cats. Plasma testosterone concentrations were not significantly different in treated male cats but owners reported reduced aggression, roaming, mounting and urine marking (spraying). In another study, a single intratesticular injection of zinc gluconate (n=115) reduced serum testosterone concentrations and testicular size as well as resulted in azoospermia (Levy, 2010). No injection-site reactions were reported during 12-month monitoring period post injection (Levy, 2010). However, Oliviera and colleagues (2013) reported transient testicular swelling with reduced activity and feed intake for 1 day after injection.

### 3.3.1.3 | Glycerol

**3.3.1.3.1 | Male dogs:** Intratesticular injection of a 70% glycerol solution in dogs did not result in azoospermia or sterility (Immegart & Threlfall, 2000).

**3.3.1.3.2 | Male cats:** Madbouly and colleagues (2001) investigated two different volumes of 70% glycerol [0.5 mL (n=7) and 1.0 mL (n=7)] for intratesticular injection. Glycerol (0.5 mL) resulted in a significant decrease in serum testosterone concentration and testicular length 3-weeks post injection; whereas glycerol (1.0 mL) resulted in a significant decrease in testicular length 1-week post-injection and serum testosterone concentration 2-weeks post injection, as well as inducing azoospermia in epididymal samples (Madbouly et al., 2021).

### 3.3.2 | Intra-epididymal injections

**3.3.2.1 | Male dogs:** Leoci and colleagues (2009) administered 20% calcium chloride in 95% ethanol into the head of the epididymis using ultrasound guidance. All dogs (n=37) treated with calcium chloride became sterile with azoospermia achieved over the 9-month study period (Leoci et al., 2019). In this study, serum testosterone concentrations were unchanged following intraepi-

didymal injections. The authors also reported that performing intraepididymal injections required the same amount of time as a routine castration and no adverse effects were noted. In a separate study, 1.5% chlorhexidine gluconate in 50% dimethyl sulfoxide was injected into the tail of each epididymis once resulting in irreversible azoospermia in dogs by 91 days after injection (Pineda et al., 1977). These authors also demonstrated that two intraepididymal injections of the same solution resulted in irreversible azoospermia within 35 days after injection.

**3.3.2.2 | Male cats:** The tail of the epididymis in male cats is very small and is more difficult to locate than in dogs. Intraepididymal injections for male cats require a 30-gauge needle. Injection of a 4.5% solution of chlorhexidine digluconate into the tail of both epididymides resulted in azoospermia or severe oligospermia (Pineda & Dooley, 1984). In this study, however, there was considerable variation in the response to treatment among male cats, both within and between treatment groups (0.05 and 0.10 mL). At various time points following the intraepididymal injection, 75% (3/4) of male cats in the 0.05 mL treatment group became irreversibly azoospermic compared with only 25% (1/4) in the 0.10 mL treatment group (Pineda & Dooley, 1984). In this study, transient scrotal swelling was reported within the first 2 weeks following injection. Male cats demonstrated a withdrawal reaction when pressure was applied to the epididymal area of the scrotum. Other than pain on palpation, the intraepididymal injections did not impair ambulation or alter the general behaviour of the male cats. Histological evaluation following intraepididymal injections with chlorhexidine digluconate revealed normal germinal epithelium with active spermatogenesis but sperm granulomas were found bilaterally in the epididymides (Pineda & Dooley, 1984).

In a separate study, intraepididymal injection of 50 mg of zinc arginine (0.5 mL/epididymis) resulted in azoospermia within 90 days following injection (Fahim et al., 1993). Histologic examination of the testes in this study revealed normal seminiferous tubules with atrophy of the rete testes, an absence of spermatozoa within the epididymis and ductus deferens and no sperm granuloma formation. It is important to mention that intraepididymal saline injection did not induce azoospermia (Pineda et al., 1977).

## 3.4 | Mechanical methods

### 3.4.1 | Intrauterine devices

The use of copper-coated intrauterine devices (IUDs) has been reported. After the IUD was inserted transcervically, the female dogs (n=8) were mated but none of them became pregnant (Volpe et al., 2001). Over a two-year period, no side effects were observed, except in one female dog that developed persistent oestrus until the device had been removed. However, in a separate study (n=9), T-shaped copper-coated IUDs resulted in a uterine perforation in two female dogs (Larsson et al. 1981a). Another female dog in this study who received a copper-coated double-loop IUD developed severe endometritis, necessitating a hysterectomy 5 months after insertion. When copper IUDs were placed directly into the abdominal cavity of female dogs (n=8) to mimic a situation where the IUD perforated the uterus, the IUDs were covered by fibrin and adhesions, and in one female dog, a subserous subacute abscess with moderate granulation developed (Larsson et al., 1981b). Based upon the results of these studies, the use of intrauterine devices should not be recommended.

### 3.4.2 | Therapeutic ultrasonography

Therapeutic ultrasonography is different from diagnostic ultrasonography because of the heat that is produced. When therapeutic ultrasonography is directed at the vas deferens or epididymis in dogs, it induces thermal coagulative necrosis with luminal occlusion within 2 weeks after treatment (Fahim et al., 1977; Fried et al., 2002; Roberts et al. 2002a; Roberts et al. 2002b). However, skin burns were reported in about 20% of cases (Roberts et al. 2002a, Roberts et al. 2002b). Therapeutic ultrasonography can also be applied to the testes (Leoci et al., 2015). Dogs (n=20) that received 5-minute applications of therapeutic ultrasonography (1.5 W/cm<sup>2</sup>) three times at 48-hour intervals covering the entire testicular area at frequency of 1 MHz developed permanent azoospermia, reduced testicular volume and histologic testicular damage within 40 days of treatment (Leoci et al., 2015). Serum testosterone concentrations did not change. Some local tenderness after treatment was reported but no other adverse effects (Leoci et al., 2015). More research is needed on the safety and efficacy before this method can be recommended for routine clinical use.

## 3.5 | Gene therapy

### 3.5.1 | Gene silencing

Gene silencing is the regulation of gene expression in a cell to prevent the expression of a certain gene. The mechanism of gene silencing can be accomplished using RNA interference (RNAi), small interfering RNAs (siRNAs), or gene editing using CRISPR/cas9 (Dissen et al., 2012; Javaid et al., 2022). Most of the research in this area is limited to in vitro cellular or rodent models. However, Dissen et al. (2017) developed a method to deliver interfering siRNA to the hypothalamus of cats using an adeno-associated virus (AAV) to silence Kiss1 genes (Dissen et al., 2017). One problem with this method has been the high percentage of owned and free-



roaming domestic cats with antibodies against AAVs (Li et al., 2019). However, not all AAV antibodies neutralise the gene silencing AAVs (Adachi et al., 2020).

### 3.5.2 | Gene overexpression

Gene therapy can be used to deliver a gene that could result in overexpression of anti-Müllerian hormone (AMH). Similar to gene silencing, most of the research in this area is limited to in vitro cellular or rodent models. However, sustained overexpression of AMH in female cats has been demonstrated using an AAV delivery [ $n=3$  given a low concentration ( $5 \times 10^{12}$  viral genomes/kg);  $n=3$  given the high concentration ( $1 \times 10^{13}$  viral genomes/kg)] via a single intramuscular injection (Vansandt et al., 2023). At the high concentration, AMH inactivated primordial follicles and blocked ovulation. For over 2 years following a single injection (at both the low and high concentrations), ectopic AMH expression did not impair oestradiol secretion or oestrous cyclicity but prevented ovulation and pregnancy (Vansandt et al., 2023).

## 4 | HEALTH BENEFITS OF STERILISATION WITH LOSS OF GONADAL STEROID HORMONES

Gonadectomy leads to the irreversible loss of reproductive hormones, which coincides with a loss of the negative feedback of gonadal steroids on the hypothalamic–pituitary axis (HPA). The latter causes permanently increased blood concentrations of LH and FSH (Beijerink et al. 2007b). The impact of these facts on the development of certain diseases in gonadectomised dogs is currently under investigation (Ettinger et al., 2019; Kiefel & Kutzler, 2020; Kutzler, 2020a, 2023; Zwida & Kutzler, 2022) and may vary between individuals. Several beneficial effects of gonadectomy have been described and are reported here. Concluding statements on benefits of gonadectomy for each condition should not be regarded as final but should be considered in view of corresponding detriment/s of gonadectomy for the same or connected condition/s. Furthermore, new evidence in this field is continually emerging and may shift the risk/ benefit calculation over time. Where appropriate, the effect of paediatric (at 6 to 16 weeks of age) and prepubertal gonadectomy is emphasised (see Table 2).

### 4.1 | Female dogs

#### 4.1.1 | Reproductive tract diseases

**4.1.1.1 | Ovarian diseases:** Complete gonadectomy prevents ovarian disease including cancer and ovarian cystic diseases (Reichler, 2009). Ovarian cysts are defined as fluid filled structures present on the ovary not related to physiological oestrus; they can grossly be grouped into cystic rete ovarii, subsurface epithelial structures, follicular cysts and luteinized cysts or cystic corpus luteum. Their size can vary remarkably (Fig 62). Ovarian cysts represent 80% of all ovarian diseases (Dow, 1960); presence of clinical signs depend on steroid hormone production which may be absent they can be without signs, especially in young female dogs, but may produce steroid hormones. In case of endocrinologically active cysts, cycle irregularities like primary or secondary anoestrus or persistent oestrus may occur;

**Table 2. Health benefits of sterilisation with loss of gonadal steroid hormones in female dogs**

Condition	Occurrence (%)	Substantial morbidity*	Breed at risk†	Influencing factors
Ovarian tumours	0.5 to 6.3 (GCT: 50% among ovarian tumours)	Yes	No	Age
Pyometra, CEH	>20 to >50 until >10 years of age	Yes	Yes‡	Age, breed/genetics geographic location
Vaginal tumours	1.9 to 3 (of all tumours)	No	No	Age, steroid hormones
Uterine tumours	0.03 to 0.4 (of all tumours)	Yes	No	Age
Mammary tumours	8.4 to 52	Yes	Yes§	Age, age at gonadectomy, gestagens, obesity, epigenetics ...
Transmissible venereal tumour (TVT)	<1 (reported incidence)	No	No	Mating
Vaginal prolapse	–	No	No	Large breeds, familiar disposition
Progesterone dependent diabetes mellitus	Assumed to be low	No	Yes¶	Age, increased body condition score, exogenous hormones (gestagens)
Behaviour: Overt pseudopregnancy	>50 to 75	No	Yes	Nutrition, another lactating female dog

\*Can be life-threatening

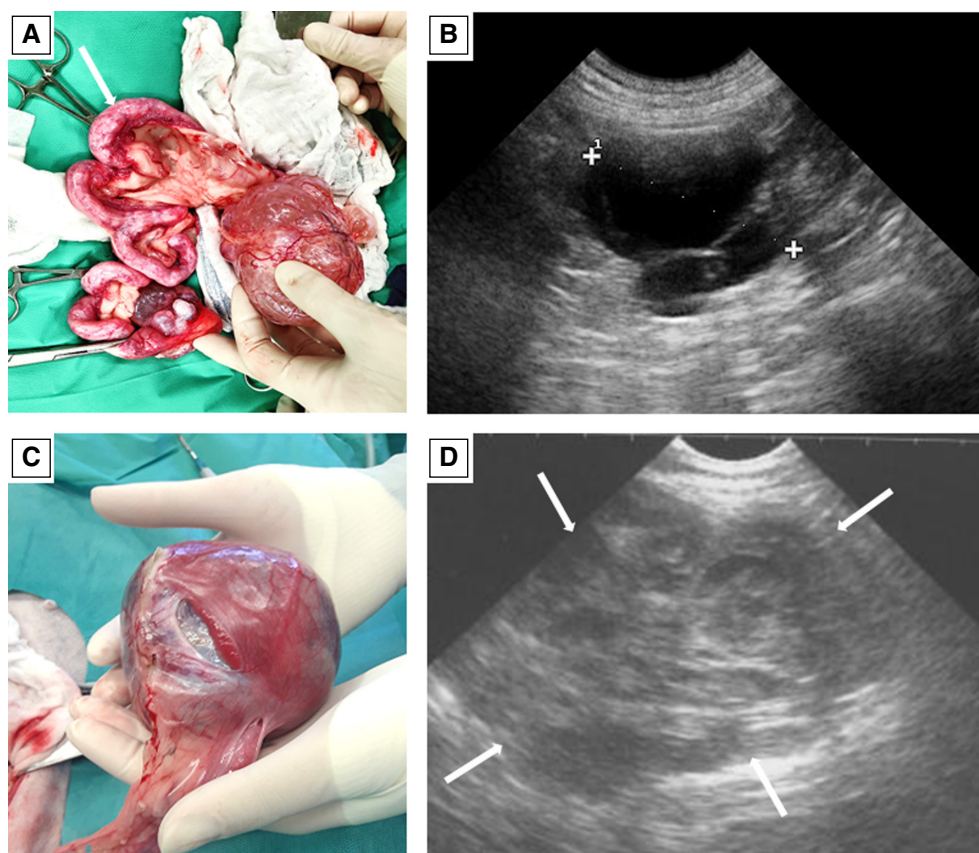
†According to literature (see chapter 4. health benefits of gonadectomy)

‡Golden retriever, Leonberger, Irish wolfhound, Bernese mountain dog, great dane, Staffordshire bull terrier, Rottweiler, Bullterrier, Doberman, Bouvier des Flandres, Airdaleterrier (Jitpean et al., 2012)

§English springer spaniel, English cocker spaniel, Brittany spaniel, Doberman, boxer, English setter, Pointer, German shepherd dog, poodle, dachshund; Staffordshire bull terrier, Lhasa apso, Yorkshire terrier, Maltese

¶Elkhounds, Nordic spitz breeds

||Afghan hound, beagle, boxer, dachshund, Dalmatian, Basset hound, Pointer



**FIG 62. Ovarian cysts and an ovarian tumour. (A)** A large ovarian cyst and **(B)** its sonographical appearance (crosses). The thin walls and the size are typical for follicular cysts. They can but do not always secrete hormones. Note the chronically diseased uterus (ampullar shape, thickened wall; arrow) – histopathology revealed CEH and secondary bacterial infection was found. **(C)** A large ovarian tumour and **(D)** its sonographical appearance (arrows). Note the irregular structure and small fluid-filled cavities. Histopathology revealed a granulosa cell tumour. However, the size of canine ovarian tumours may vary remarkably; any grossly/sonographically abnormal structure may be a tumour

high serum oestrogen concentrations can cause hypoestrogenism, a syndrome characterised by alopecia, hyperpigmentation, seborrhoea organ disturbances like CEH, increased susceptibility to infections and bone marrow failure with pancytopenia (Gaunt & Pierce, 1986). Diseased animals can suffer from different organ diseases inclusive CEH, non-regenerative anaemia and increased susceptibility to infections. Reported prevalences are highly variable (for review: Arlt & Haimerl, 2016; Kumar et al., 2019; Lopate & Foster, 2010).

Ovarian tumours may be life threatening, especially when metastasizing, growing too large or producing oestrogens and progesterone (Ferré-Dolcet et al. 2020b; Lopate & Foster, 2010). Histologically three main types can be differentiated: epithelial tumours from the ovarian surface epithelium (adenoma, adenocarcinoma and others), sex-cord stromal tumours originating from sex-cord and stromal cells (granulosa cell tumour, thecoma, luteoma) and germ-cell tumours from primordial germ cells of the ovary (dysgerminoma, teratoma) (Ferré-Dolcet et al. 2020b; Nielsen et al., 1976). The main predisposing factor is age as most tumours are diagnosed in bitches older than 10 years (Hayes & Young, 1978; Nielsen et al., 1976; Norris et al., 1970); although occasionally granulosa cell tumours (Coggeshall et al., 2012; Norris et al., 1970; Troisi et al., 2023), adenocarcinoma (Troisi et al., 2023) and teratoma (Coggeshall et al., 2012; Patnaik & Greenlee, 1987; Troisi et al., 2023) may be diagnosed in young to adult (1.5 to 6, years of age) female dogs. Other predisposing factors like breed are not confirmed and require further investigation. The recorded frequency of occurrence varies considerably between studies and ranges between 0.5 and 6.3% (Arlt & Haimerl, 2016; Kumar et al., 2019; Lopate & Foster, 2010; McEntee, 2002). The frequency of ovarian tumours may be underestimated since many dogs are gonadectomised at a young age and histopathology of excised organs is not routinely done (McEntee, 2002). Similarly, the distribution of tumour categories according to cells of origin varies; however, in most studies, epithelial tumours predominate (Table 3) (Arlt & Haimerl, 2016).

The incidence of granulosa cell tumours can be up to 50% among all ovarian tumours; these tumours produce and secrete oestrogens in approximately 50% of cases, which may cause hyperoestrogenism and life-threatening diseases as described above (Nielsen et al., 1976). Frequency of metastatic disease in adenocarcinomas, granulosa cell tumours and germ cell tumours is 48% (Patnaik & Greenlee, 1987), 20 to 50% (Jergens & Shaw, 1987; Nielsen et al., 1976) and 20 to 30% (Greenlee & Patnaik, 1985; Jergens & Shaw, 1987), respectively.

These data highlight the importance to consider OHE in older female dogs.

**Table 3. Findings of histopathological studies on specific canine ovarian tumours**

Author, year	No of specimens	Epithelial tumours			Sex cord-stromal tumours			Germ cell tumours	
		Adenoma	Adenocarcinoma	Other	Granulosa cell T	Sertoli-Leydig T	Other	Dysgerminoma	Teratoma
Dow, 1960	25	10	1	1	13	–	–	–	–
Norris et al., 1970	78	20*	3*	6	15	6	5	11	2
Hayes & Young, 1978	94	23	29	3	22	–	1	2	5
Patnaik & Greenlee, 1987	71	12	21	–	12	12	–	7	7
Diez-Bru et al., 1998	10	1	3	–	3	–	1	1	1
Sforna et al., 2003	49	21	7	–	14	–	–	2	1
Bertazzolo et al., 2004	19	–	7	–	8	–	1	1	2

T Tumour

Adapted from Arlt and Heimerl, 2016

\*And in addition, 10 intermediate tumours between adenoma and adenocarcinoma

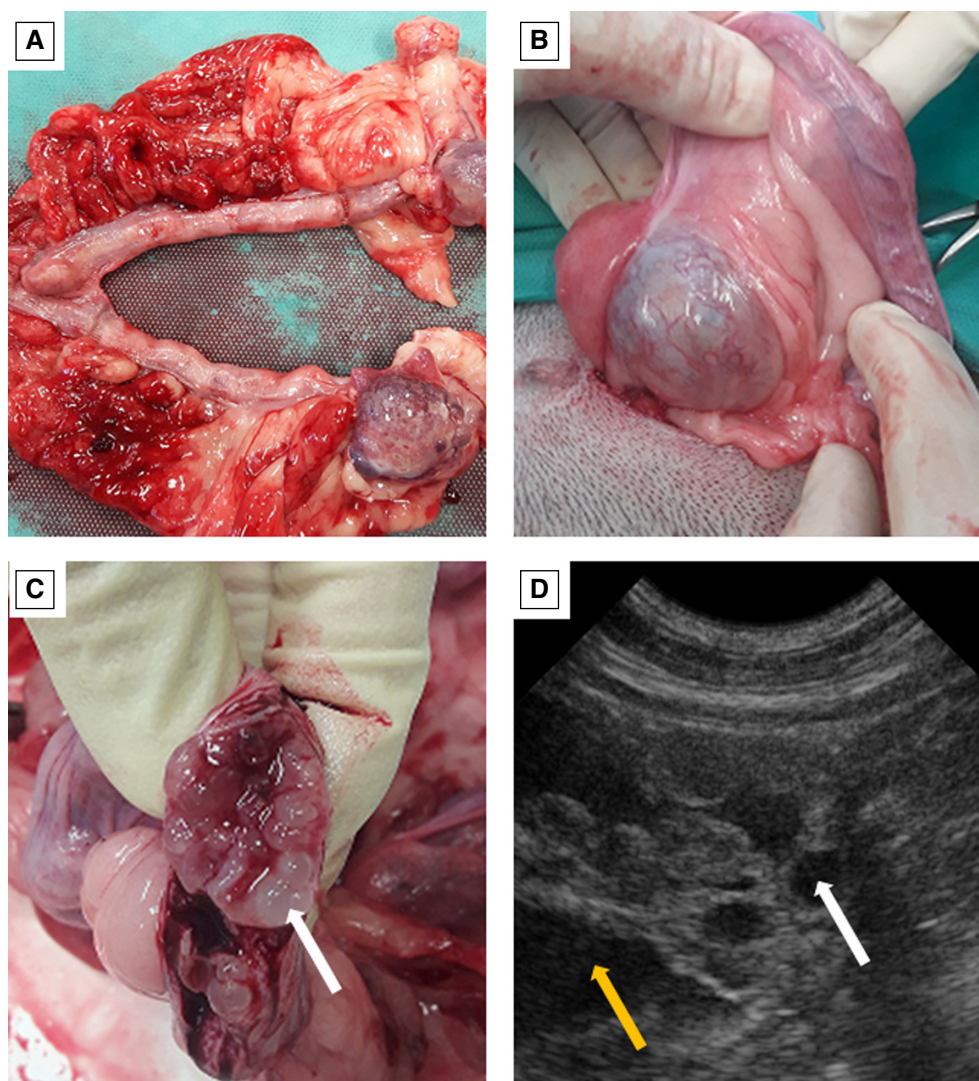
**4.1.1.2 | Uterine diseases and unwanted pregnancies:** OHE in female dogs clearly cures and prevents the occurrence of uterine diseases including tumours, pyometra and pathological pregnancies (infectious and non-infectious). Gonadectomy prevents pregnancies and the cyclic influence of steroid hormones on the ageing endometrium predisposing to degenerative diseases like CEH (Noakes et al., 2001; Schlafer & Gifford, 2008). This chronic, non-regenerative disease mainly occurs in female dogs that never carried a pregnancy to term or had non-pregnant cycles for more than 3 to 4 years (Fig 63). Prevalence of CEH increases with age (Moxon et al., 2016). CEH among other factors predisposes to uterine infection and most cases of pyometra (pus-filled uterus) occur because of bacterial infection of the chronically degenerated endometrium (for review: Hagman, 2018, 2022, 2023). Pyometra is a life-threatening disease with an increasing frequency of occurrence with increasing age (Hagman, 2018, 2022, 2023; Jitpean et al., 2012; Reichler, 2009; Urfer & Kaerberlein, 2019). In countries where gonadectomy is only allowed for therapeutic reasons, incidence varies between >20 and 54% in female dogs up to 10 years old depending on age, breed and geographic location (Arendt et al., 2021; Egenvall et al., 2001; Hagman, 2018; Hart et al., 2014; Jitpean et al., 2012; Reichler, 2009; Urfer & Kaerberlein, 2019). Exogenous oestrogen and progesterone administration or its endogenous secretion (in case of ovarian remnant) may cause uterine disease in ovariectomised female dogs or ovariohysterectomised female dogs with a uterine remnant (Ball et al., 2010; Ehrhardt et al., 2023; Parker & Snead, 2014; Sterman et al., 2019).

Complete removal of the uterine tissue including the cervix prevents pregnancies and prevents or cures uterine diseases.

**4.1.1.3 | Reproductive tubular tract neoplasia:** Vaginal tumours account for 1.9 to 3% of all tumours in the female dog (Brodey & Roszel, 1967; Thacher & Bradley, 1983; Weissman et al., 2013), originating mostly from smooth muscle or fibrous tissue (Devereaux & Schoolmeester, 2019; Soderberg, 1986) and occurring more often in intact than in gonadectomised female dogs since many tumours express steroid hormone receptors and are steroid hormone responsive (Ferré-Dolcet et al. 2020b). Up to 73 to 94% are benign (Brodey & Roszel, 1967; Kydd & Burnie, 1986; Thacher & Bradley, 1983). The most common vaginal tumour is the leiomyoma which is reproductive steroid hormone dependent and most often occurs in intact, primiparous dogs between the age of 5 to 16 years (Brodey & Roszel, 1967; Ferré-Dolcet et al. 2020b; Sathya & Linn, 2014). The tumour is considered non-invasive and does not cause metastases (Devereaux & Schoolmeester, 2019). Recurrence after surgical removal is significantly decreased after gonadectomy (Herron, 1983; Kydd & Burnie, 1986; Thacher & Bradley, 1983). Leiomyomas may spontaneously regress after OHE (Kydd & Burnie, 1986; Sathya & Linn, 2014; Ferré-Dolcet et al. 2020b). Benign vaginal tumours are not likely to develop after gonadectomy (Kydd & Burnie, 1986).

Uterine tumours are very rare, the incidence was reported to be 0.03 to 0.4% of all canine tumours and mostly leiomyomas are diagnosed (>90% of all uterine tumours; Brodey & Roszel, 1967; Kunar et al., 1995; Pena et al., 2006). Less common tumours include angiolipoleiomyomas (Boisclair & Doré, 2001), lipoleiomyomas (Percival et al., 2018), adenomas, fibromas, fibroleiomyomas, fibromyomas, adenomas, lipomas and endometrial polyps (Gelberg & McEntee, 1984; Marino et al., 2007; Nueangphuet et al., 2022). Malignant uterine tumours are rare with a calculated incidence of 0.003% (Van Goethem et al., 2006); mostly adenocarcinomas, leiomyosarcomas and transmissible venereal tumours (TVTts) are diagnosed (see Chapter 5.1.1.), haemangiosarcomas are rarely found (Murakami et al., 2001). They usually occur in geriatric bitches (Pena et al., 2006; Pires et al., 2010) although uterine carcinomas were diagnosed in intact females as young as 10 months and 2 years of age, and a relationship with progestogen therapy was hypothesised (Cave et al., 2002; Payne-Johnson et al., 1986). Carcinomas may metastasize which may lead to death when diagnosed too late (Pena et al., 2006). A haemangiosarcoma was diagnosed in the uterine stump of an 11-year-old ovariectomised and subtotally hysterectomised female dog (Wenzlow et al., 2009). Uterine neoplasia has not been reported in dogs ovariec-



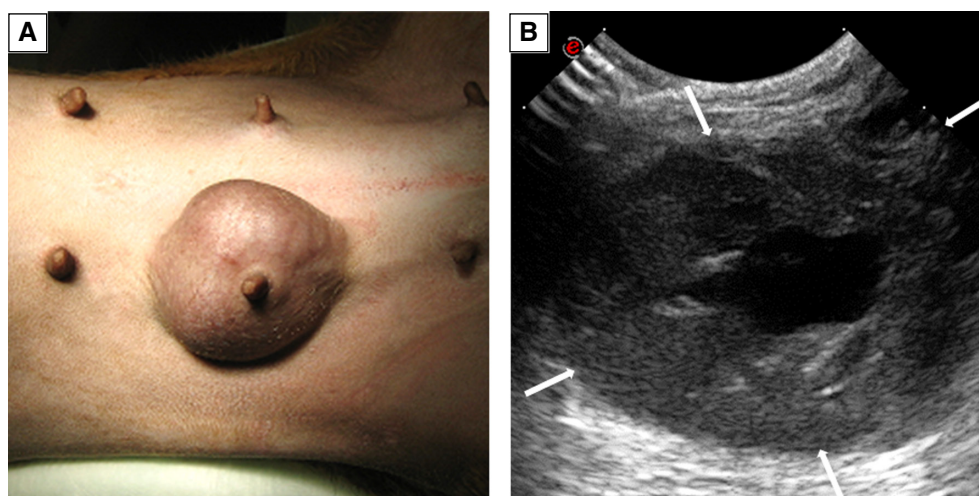


**FIG 63. Uterine disease.** (A) CEH combined with bacterial endometritis. (B) This female dog in addition had large ovarian cysts. (C) Multiple cysts in the endometrium (arrow). (D) Sonographical image: note the large endometrial cysts (white arrow) and the intrauterine accumulation of fluids (yellow arrow)

tomised before 2 years of age (DeTora & McCarthy, 2011). The incidence of uterine neoplasia in dogs ovariectomised after 2 years of age is unknown.

Gonadectomy is believed to reduce the frequency of occurrence of neoplasia in the vagina. However, prophylactic paediatric or prepubertal gonadectomy is not recommended. The decision whether or not to gonadectomise a dog should not be made solely to prevent reproductive tubular tract neoplasia but consider more factors (see Chapter health detriments in female dogs 5.1.). In case of existing vaginal tumours, surgical removal of the tumour in combination with gonadectomy or any hormonal downregulation is recommended. A properly performed (ovario)hysterectomy (with absence of any uterine stump) will also prevent the development of any uterine neoplasia in gonadectomised female dogs.

**4.1.1.4 | Mammary tumours:** Mammary tumours are the most commonly diagnosed tumours in intact female dogs, developing as single or multiple masses affecting one or more glands (Fig 64). The frequency of occurrence in intact female dogs was described to range between 8.4 and 52% (Anderson & Jarrett, 1966; Brodey, 1970; Brodey et al., 1983; Cohen et al., 1974; Jitpean et al., 2012), but can be lower dependant on the evaluated population (26/792; 3.2%; Zink et al., 2023). The prevalence in gonadectomised females was 1.8% (42/2281) in one retrospective study (Zink et al., 2023), although age at gonadectomy is an important factor to consider as prevalence was 4.9 to 5.3% in female dogs gonadectomised at >2 years of age (Beaudu-Lange et al., 2021; Gedon et al. 2021a; Hart et al., 2016) About 50% of mammary tumours in female dogs are malignant (Sorenmo, 2003). The development of mammary tumours is complex and multifactorial. Age is one of the most relevant factors as the incidence of mam-



**FIG 64. Mammary tumour. (A) Solid and well circumscribed mammary tumour in the next to last mammary complex on the right side, and (B) sonographical appearance (arrows). Note the heterogenous structure – in this case, cysts were present in the middle**

mary tumours clearly increases with age; most female dogs with mammary tumours are >8 years old (Donnay et al., 1994; Egenvall et al., 2005; Richards et al., 2001; Salas et al., 2015; Taylor et al., 1976; Varney et al., 2023; Zatloukal et al., 2005). Furthermore, breed (springer spaniel, cocker spaniel, boxer, poodle, dachshund; large breeds >small breeds), obesity at 1 year of age, hormone treatment and repeated pseudopregnancies (Dobson, 2013; Donnay et al., 1994; Egenvall et al., 2005; Gupta, 2012; Jitpean et al., 2012; Oliveira et al., 2022; Pastor et al., 2018; Pérez Alenza et al., 1998; Sonnenschein et al., 1991; Varney et al., 2023) and even alterations in gene expression by epigenetic mechanisms are reported predisposing factors (Borges, 2022). Intact female dogs were reported to have a threefold to fourfold or higher increased risk to develop a mammary tumour and more frequently have multiple tumours in comparison to gonadectomised dogs, whereas gonadectomy decreased the odds of developing mammary tumour as well as mortality rate due to mammary tumour about threefold (Beaudu-Lange et al., 2021; Gedon et al. 2021b; Grüntzig et al., 2016; Misdorp, 1988; Priester, 1979; Schneider et al., 1969; Taylor et al., 1976; Varney et al., 2023). However, failure to consider age at gonadectomy was identified as a limiting factor in a recent large-scale retrospective study (Varney et al., 2023). For a reliable calculation of incidences, denominators should obligatorily feature a population at risk and any study should be evaluated to that effect (Moulton et al., 1970).

Many authors suggest that gonadectomy at an early age and especially before puberty decreases the relative risk of mammary tumours in bitches (Hart et al., 2014, 2016; Schneider et al., 1969; Torres de la Riva et al., 2013; Zink et al., 2014). In two studies, no female dog that was gonadectomised before puberty (Singer et al., 2021) and in another, no female German shepherd dog gonadectomised at <6 months (0/46) developed a mammary tumour (Hart et al., 2016). This is because of the effect of progesterone and oestrogens on mammary gland stem cells and epithelial cells, which occur during the first oestrous cycle. In some cases, the first exposure to progesterone causes stem cell mutations predisposing to mammary tumours during later life (Timmermans-Sprang et al., 2017). Furthermore, binding of oestrogens to nuclear receptors initiates an increase in the expression of positive proliferation regulators and down-regulation of anti-proliferative and pro-apoptotic genes, thereby promoting growth and spontaneous mutations (Haakensen et al., 2011). In a relevant epidemiological study from 1969, the relative risk of mammary canine carcinoma was calculated as 0.5% in prepubertal gonadectomised female dogs, and 8 and 26% if gonadectomy was performed between the first and second cycle or between the second and third cycle, respectively, while no sparing effect was observed in female dogs spayed after the third cycle (Schneider et al., 1969). The sparing effect of gonadectomy on the relative risk of mammary neoplasia has been challenged by work from Beauvais and coworkers (Beauvais et al., 2012a) whose meta-analysis found only weak evidence that gonadectomy reduces the risk of mammary tumour. The four studies (out of 11,149 data sets) found suitable, were still classified as having a moderate risk of bias (Bruenger et al., 1994; Pérez Alenza et al., 1998; Richards et al., 2001; Schneider et al., 1969). In one of these studies, authors admit that case numbers were too low to allow for a sound conclusion on the relation between OE and mammary tumour development (Pérez Alenza et al., 1998). In another study, age at time of spay was not known for the gonadectomised females (Richards et al., 2001). The weakness of such evidence can be explained with the low number of cases that were evaluated in the above studies, the heterogeneity of the patients (breed, age, age at castration, benign/malignant tumours) and study designs, and finally the multifactorial aetiology of mammary tumours. Furthermore, it must be emphasised that in some studies, puberty was not excluded properly; age of <6 months does not necessarily mean prepubertal. Some studies indicate that the probability of tumour development is still decreased if the female dogs is gonadectomised after completing the second oestrous cycle (Beauvais et al., 2012a; Grüntzig et al., 2016; Schneider et al., 1969; Sonnenschein et al., 1991; Sorenmo, 2003). In one retrospec-

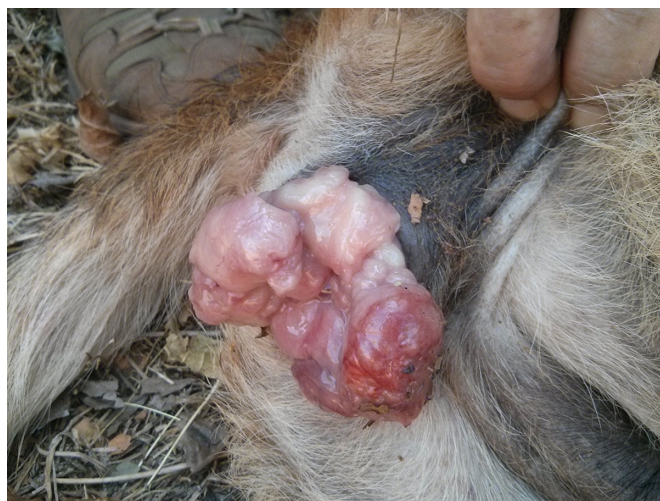

tive study, gonadectomy at a later age revealed no protective effect on the development of malignant tumours and more malignant tumours were found in gonadectomised than in intact female dogs (Gedon et al. 2021a). However, any benign tumour will become malignant because of a proven histological continuum from benign to early malignant to finally invasive carcinoma (Sorenmo et al., 2009) and thus explaining the observation that with age benign tumours transform to malignant (Gedon, Wehrend, Failing, & Kesler, 2021a; Gedon et al. 2021b; Kristiansen et al., 2013; Misdorp, 1988; Mohammed et al., 2020; Philibert et al., 2003; Schneider et al., 1969; Taylor et al., 1976).

Mammary tumours express gonadal hormone receptors except those showing advanced dedifferentiation (Mohr et al., 2016). Therefore, in intact female dogs with mammary tumour, OHE has been recommended at the time of tumour removal to increase mammary disease-free survival time and to eliminate risk for uterine diseases or to remove an already diseased uterus (Banchi et al., 2022; Gedon et al. 2021b). However, this issue is complicated by the observation that the risk of new mammary tumour was reduced in female dogs with increased expression of oestrogen receptors in the mammary tissue and increased oestrogen serum concentration before gonadectomy (Kristiansen et al., 2013, 2016; Sorenmo et al., 2019). Oestrogen is believed to act as a procarcinogen and the serum oestrogen concentration was found to be higher in dogs with mammary carcinomas than without mammary carcinomas (Sorenmo et al., 2019). More research is needed on the role of oestrogens in the development of mammary tumours in the bitch.

The decision whether to gonadectomise a female dog and at what age this should be done, should not only rest upon the consideration of preventing mammary tumours and consider many more factors (see Chapter health detriments in female dogs 5.1.). Prophylactic gonadectomy may be recommended for breeds at risk as well as for female dogs whose owners are particularly concerned about the threat of mammary tumours in their dogs. The age at which such gonadectomy should be done will depend on the inherent risk of the specific breed to develop other conditions due to gonadectomy. While paediatric gonadectomy (6 to 16 weeks) is known to reduce the prevalence of mammary carcinoma, this reduction is likely smaller than was previously believed and therefore the practice of paediatric gonadectomy can no longer be routinely recommended in most cases. OHE at the time of tumour removal is recommended except in case of dedifferentiated tumours.

**4.1.1.5 | Transmissible venereal tumour:** TVT or Sticker's Sarcoma is a highly contagious, round cell tumour of clonal origin. The main route of transmission is mating (Ganguly et al., 2016; Strakova & Murchison, 2015); although transmission of living cancer cells by licking or sniffing was also demonstrated (Strakova & Murchison, 2015). Therefore, animals of reproductive age are more commonly affected (80%) (Ganguly et al., 2016). The mutated tumour cell is the contagious agent, infesting the host like a parasite. The tumour mainly affects the genital region of dogs (Fig 65), although it may less frequently occur in other regions like oral cavity, face and the perineal area. The tumour can quickly spread among wild or stray dogs, wolves, coyotes and jackals, when mating is not prevented (Ganguly et al., 2016). Metastases are rare (<1%) but can be found in lymph nodes, lung, heart and abdominal organs (Bendas et al., 2022). Multiorgan metastasis leading to euthanasia of a dog was reported (Park et al., 2006). Even though TVT is malignant, the success rate after chemotherapy with vincristine sulphate is good; the tumour may regress without surgery. The estimated incidence is <1%; however, the estimated number of unreported cases may be high and the incidence much higher in regions with many stray dogs (Faro & Oliveira, 2023).



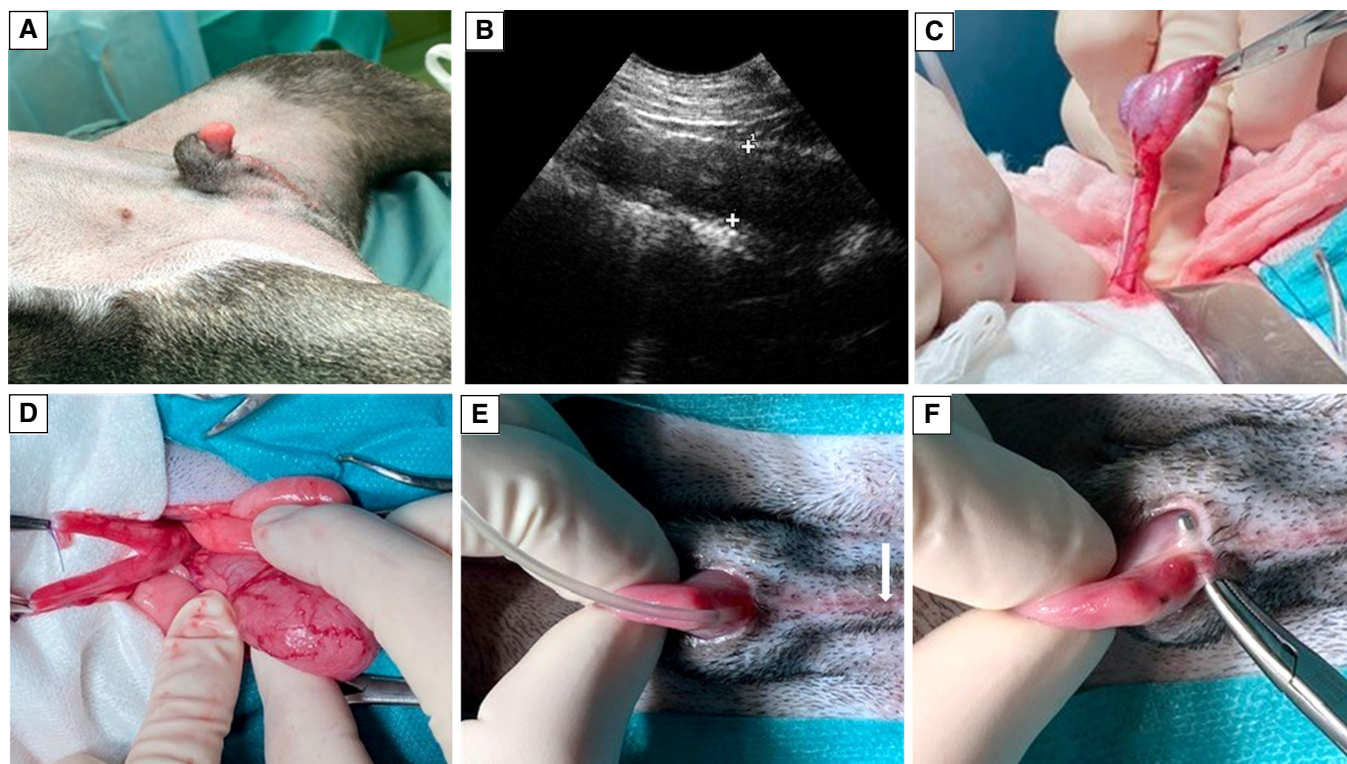
**FIG 65. Transmissible venereal tumour (TVT).** TVT protruding out of the vagina of a shelter dog. Note the irregular, cauliflower-like surface



In countries/areas where the problem is endemic, gonadectomy will reduce the risk of TVT, probably by reducing the frequency of mating.

**4.1.1.6 | Vaginal hyperplasia and vaginal prolapse:** In female dogs, vaginal hyperplasia and vaginal fold prolapse (synonym: vaginal hypertrophy, vaginal eversion, vaginal protrusion) mainly occurs during the follicular phase of young female dogs during their first to third heat (73 to 86%), when serum oestrogen concentration is at its maximum (Johnston, 1989; Johnston, Kustritz, & Olson, 2001b; Post et al., 1991; Schutte, 1967; Soderberg, 1986; Sontas et al., 2010); it occurs more rarely in dioestrus and as so called true vaginal prolapse during pregnancy (8 to 12%) (Alan et al., 2007; Gouletsou et al., 2009; Johnston, Kustritz, & Olson, 2001b; Memon et al., 1993). This lesion starts as a focal oedema of the submucosa and hyperplasia of the vaginal mucosa and the stratified squamous epithelium, and finally a small eversion in the vaginal floor cranial to the urethral opening (grade I, Fig 66A); the eversion may progress to an incomplete (grade II, Fig 66B) or complete (grade III, Fig 66C) prolapse of vaginal tissue (Anya et al., 2020; Manothaiudom & Johnston, 1991; Schutte, 1967). Complications include lesions and inflammation of the prolapsed tissue as well as secondary infections. A retroflexion of the urinary bladder has been reported in a female dog concomitant with a vaginal prolapse occurring during oestrus (Beretta et al., 2023). Oestrogen concentration is not higher in affected *versus* healthy female dogs and hyperoestrogenism was not reported in clinical cases (Schutte, 1967). However, the fact that this condition occurs only during the follicular phase clearly points to a relationship with oestradiol secretion, perhaps modulated by an abnormal concentration of oestradiol receptors in prolapsed vaginal tissues. In one reported case, the prolapse was induced after treatment with 0.3 mg/kg oestradiol benzoate i.m. for oestrus induction (Sarrafzadeh-Rezaei et al., 2008). The disease has anecdotally been reported more frequently in young female dogs of boxer, boxer cross and brachycephalic breeds as well as in large breed dogs, but a breed predisposition has not been proven in case control studies (Anya et al., 2020; Manothaiudom & Johnston, 1991; Schutte, 1967; Sontas et al., 2010). Since familial clustering is observed and a genetic predisposition is suspected, affected dogs should not be used for breeding. Spontaneous remission because of decreasing oestrogen concentrations is possible in grade I (eversion) and grade II (partial protrusion, incomplete prolapse, includes areas from the lateral wall) cases. Recurrence rate after spontaneous regression is anecdotally reported to be >66% (Johnston, 1989).

Gonadectomy leads to remission of vaginal hyperplasia/prolapse within 7 to 10 days and prevents possible recurrence of the problem (Johnston, 1989; Johnston, Kustritz, & Olson, 2001a; Schutte, 1967; Slatter, 2003). In grade III cases (complete protrusion of



**FIG 66. Different grades of vaginal hyperplasia. (A) Grade I. (B) Incomplete prolapse, grade II. (C) Complete prolapse, grade III**

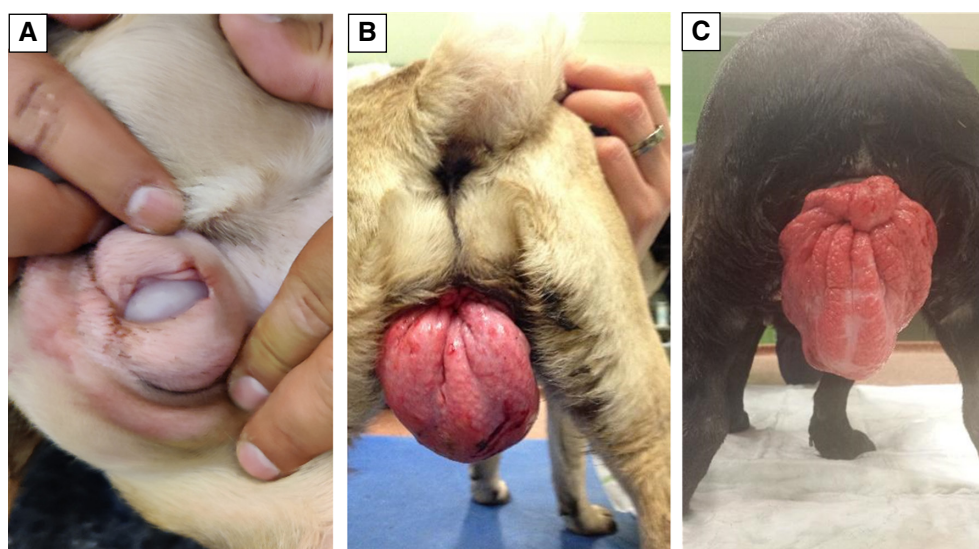
the entire circumference of the vagina), surgical removal of the protruded mass should be performed jointly with gonadectomy (Ganz et al., 2020; Schutte, 1967).

**4.1.1.7 | Disorders of sexual development:** Disorders of sexual development (DSD) are anatomical abnormalities that occur because of a failure of development of the female or male reproductive systems (for review: Romagnoli & Schlafer, 2006). Former terms were intersexes, pseudohermaphrodites or hermaphrodites. Affected dogs typically show characteristics of both sexes. Pseudohermaphrodites possess the gonads of one sex but the secondary sexual organs and external genitalia of the other (Fig 67). Female pseudohermaphrodites have ovaries but the phenotype is masculine. Male pseudohermaphrodites have testes and mixed or female external genitalia. In case of true hermaphroditism, both testicular and ovarian tissue is present. A testis on one side and an ovary on the other side, or an ovotestis (both tissues in one gonad) may be present, or an ovotestis on one side and testis or ovary on the other (Howard & Bjorling, 1989). Testicular (or ovotesticular) DSD – XX DSD (78, XX and *SRY*-negative) has been diagnosed in >30 dog breeds. These animals have a female phenotype with an enlarged clitoris, uterus, ductus deferentes and testes or ovotestes (Sumner et al., 2018; Switonski, 2014). Other described karyotypes are X trisomy in a mosaic form (79,XXX/78,XX); Robertsonian translocation in a mosaic form (77,XX,rob/78,XX); nonmosaic X/autosome translocation [78,X,t(X;A)]; X/autosome translocation in a mosaic form [78,X,t(X;A)/78,XX]; and leukocyte chimerism (78,XX/78,XY) (Szczerbal et al., 2021). DSD occurs with variable incidence at any stage of normal sexual development and therefore coincides with various genital tract malformations. Most individuals are sterile; however, some retain fertility (Meyers-Wallen, 2012; Meyers-Wallen & Patterson, 1989). Causes include spontaneous mutations, hormonal treatments during early pregnancy or genetic conditions; in Miniature Schnauzers, male pseudohermaphroditism inheritance was reported to be autosomal recessive (Sumner et al., 2018). Problems that may occur in DSD animals start with puberty and are associated with the changing endocrine situation, as there can be normal steroid hormone receptor expression in the uterus that may be fully responsive to hormone stimulation, even in true hermaphrodites (Bartel et al., 2015). Problems may deteriorate, when a blind ending uterus starts to fill with fluids during and after puberty, or when infections of the urogenital tract or autonomous growth of the gonadal tissue occur (Bartel et al., 2015; Newman, 1979; Norrdin & Baum, 1970; Salkin, 1978). Other problems are mostly associated with other malformations like hypospadias, hypoplasia of the prepuce, phimosis or a connection between the urinary bladder and the uterus, cryptorchidism or with abnormal behaviour associated with the unclear endocrine situation when both gonads are present. An enlarged clitoris with or without penile bone may become chronically inflamed because of mechanical irritation or may cause urinary tract infections (Bartel et al., 2015; Meyers-Wallen, 2012; Meyers-Wallen & Patterson, 1989; Sumner et al., 2018; Wernham & Jerram, 2006).

Early diagnosis, gonadectomy, hysterectomy and surgical correction of any malformation will be beneficial in any case of DSD.

#### 4.1.2 | Progestogen dependent diabetes mellitus

In some female dogs, elevated progesterone concentrations during dioestrus, pregnancy or gestagen therapy can cause a temporary reduction in insulin sensitivity. This is additionally triggered by growth hormones secreted by the mammary gland, probably contrib-



**FIG 67. Disorders of sexual development in a postpubertal dog. (A) Enlarged clitoris. (B) Sonographical image of the uterus. Note the fluid filled, blind ending uterus (crosses). (C) Removal of the gonads (testes). (D) Removal of the blind ending uterus. (E) The enlarged clitoris was removed afterwards because of constant mechanical irritation of the tissue. The urethra opening was between the vestibule and the blind ending vagina (arrow). (F) For removal of the enlarged clitoris, large vessels must be carefully sutured**



uting to the even more pronounced insulin resistance in pregnant compared to dioestrus female dogs. This condition is referred to as progestogen dependent diabetes mellitus (Eigenmann et al., 1983) and resembles human gestational diabetes, defined as any degree of glucose intolerance during pregnancy (Rand et al., 2004). Progestogen dependent diabetes mellitus is assumed to occur relatively infrequently. A breed predisposition exists; in Norwegian and Swedish Elkhounds, mostly intact females are affected, and diabetes mellitus frequently occurs during dioestrus and pregnancy (Fall et al., 2007, 2010). In one study, in 22 female Elkhound dogs and 18 non-Elkhound dogs, insulin concentrations were higher during dioestrus than during anoestrus (Mared et al., 2012). Also increased body condition score and age were shown to be predisposing factors (Fall et al., 2007; Wejdmark et al., 2011). In cycling female dogs, clinical signs decrease during late dioestrus and anoestrus but can recur in subsequent cycles. In pregnant dogs, the condition may persist after parturition, in which case it would be re-classified as either type 1 or another type of diabetes. In one study, insulin treatment became effective again 11 days after gonadectomy and blood-glucose levels were under control within 2 months (Kim et al., 2019).

Gonadectomy will cure progestogen dependent diabetes mellitus, regardless of time after diagnosis (Pöppel et al., 2013, 2024).

### 4.1.3 | Behavioural issues

The impact of gonadectomy on behaviour is controversial. Behaviour is highly dependent on breed and other issues such as housing, living conditions, degree of socialisation, stimuli, experiences etc; therefore, behavioural abnormalities can have multiple causes and, in some cases, gonadectomy may not solve the clinical problem. Retrospective studies investigating the effect of gonadectomy on behaviour are often confounded since important factors like age at gonadectomy, environmental and management factors, husbandry, contact with other dogs and history of the individual dogs are sometimes not considered, and a control group is often missing (Arlt et al., 2017). Furthermore, in many cases, the term behavioural abnormality is not properly defined. Problematic behaviour, like aggression and anxiety- or fear-based behaviours, must be differentiated from nuisance behaviours like urine marking and mounting behaviour, which is normal but unwanted behaviour by dog owners (Zink et al., 2023) as well as during the special training for working and service dogs (Zlotnick et al., 2019). At present there is not enough literature to clarify in how many cases of aggressive or nuisance behaviour in female dogs, gonadectomy improved the situation. In Table 4, some studies were thoroughly reviewed.

In selected behavioural conditions, gonadectomy will be beneficial. In the female dog, overt pseudopregnancy or pseudocyesis may manifest itself along with increased or reduced activity, aggression, depression, nesting behaviour, anorexia and lactation, the latter increasing the risk for mastitis (Johnston, 1986; Root et al., 2018). Some cases of pseudopregnancy thus coincide with clinical problems and require treatment (Gobello, 2021; Gobello et al., 2001). The recurrence rate in affected dogs in subsequent cycles is anecdotally reported as high (Johnston, 1986). Besides the adoption of improved nutritional strategies and/or, medical treatment, gonadectomy will eliminate the problem in these cases (Gobello et al., 2001; Johnston, 1986; Lawler et al., 1999). Some female dogs show a negative change in behaviour during the follicular phase and these signs will resolve with gonadectomy. Another clear indication to gonadectomise a female dog is repeated aggressiveness of the mother towards her pups or towards people getting close to her litters (Kuhne, 2012). A systematic review of the literature found evidence that gonadectomy reduces the risk of dog bites but conceded that all reviewed studies were observational case control studies, and the effect of size could not be estimated (D'Onise et al., 2017). Therefore, a dog with a history of being a biter should better be seen by a specialist in behaviour to look for the underlying reasons before irreversible gonadectomy is performed (Overall & Love, 2001); reversible methods like chemical castration using a GnRH agonist seem preferable although the endocrine flare-up caused by long-acting GnRH implants (irrespective of the cycle stage at implantation) may actually cause a temporary worsening of the problem. Furthermore, behavioural changes may occur in case of long-acting GnRH-induced ovulation and subsequent pseudopregnancy. These issues will vanish after successful down-regulation (Fontaine & Fontbonne, 2011; Körber et al., 2013; Maenhoudt et al., 2014; Palm & Reichler, 2012; Trigg et al., 2006).

Gonadectomy will be beneficial in selected cases of behavioural problems in female dogs with overt pseudocyesis and in female dogs with maternal aggression. All other behavioural concerns must be analysed by veterinary behavioural experts before irreversible gonadectomy is performed. A trial with long-acting GnRH agonists is an option.

### 4.1.4 | Life expectancy

Gonadectomy is reported to increase life expectancy, in both male and female dogs (Bronson, 1982; Greer et al., 2007; Hoffman et al., 2013; Michell, 1999; Moore et al., 2001; O'Neill et al., 2013; Banfield Pet Hospital Report, 2013). A retrospective evaluation of electronic medical data of 2.2 million dogs revealed that gonadectomised female dogs lived on average 23% longer than intact female dogs (Banfield Pet Hospital Report, 2013). Unfortunately, results of referral caseloads, questionnaire surveys and pet insurance data are often biased (O'Neill et al., 2013); many ignore the possible impact of sex, age at gonadectomy, body condition score and breed size, cancer, immunological diseases, environmental factors and inbreeding on life expectancy (Arlt et al., 2017; Cooley et al., 2003; Greer et al., 2007; Montoya et al., 2023; Salt et al., 2019; Yordy et al., 2020). As a result, the topic of life expectancy following gonadectomy has been a source of controversy particularly since the publication of a number of studies focussed on the Rottweiler breed, in which the effect of gonadectomy was studied in female dogs of exceptional longevity. In one of the first such studies, a large retrospective analysis of medical histories of 345 Rottweilers, there was no difference in percentage life expectancy



**Table 4. Literature review on changes in behaviour after gonadectomy – female dogs**

Authors	Method	Number of female dogs	Breeds	Husbandry utilization	Age at gonadectomy (n)	Time between gonadectomy and study	Behavioural problem	Improvement (n)	No change (n)	Deterioration (n)
Balogh et al., 2018	Contacting owners (email, telephone)	132	Labrador retriever	–	–	–	Fear reaction to <ul style="list-style-type: none"> <li>• Loud noises</li> <li>• Unfamiliar objects</li> <li>• Jumping, barking, growling dogs</li> </ul>	–	–	All spayed bitches had higher numerical rating scores than intact bitches
Borchelt, 1983	Interviews with family members	372	Breeds and mongrels	–	–	–	Aggression, mostly fear and possessive and female–female	–	–	68% of spayed versus 32% of intact
Brinkmann, 2015	Survey (cross-sectional)	217 PPN 1828 controls (after first oestrus)	420 of different breeds and 105 mongrels	–	<6months (217) 6 to 15months (745) 16 to 30months (365) 2.5 to 8 years (488) >8 (83) Unknown (147)	–	Excitability Insecurity Aggression Separation anxiety	–	–	Anxiety score in PPN group sign. higher than in controls
Heidenberger & Unshelm, 1990	Survey (cross-sectional)	382 spayed (47 with aggression, 41 with anxiety, 32 with nervousness)	24% mongrels, 98 breeds	90% indoors 20% guard dogs	–	–	<ul style="list-style-type: none"> <li>• Aggression towards other dogs</li> <li>• Anxiety</li> <li>• Restlessness, nervousness</li> </ul>	53% (25/47) 3.1% (12/382)	21 (10/47) –	21% (10/47) 7% (28/382)
Johnston, 1986	Retrospective	59	Many different	–	Variable	–	Overt pseudopregnancy	100%	0	0
Kim et al., 2006	Prospective cohort study	14	German shepherd dogs	Kennel, Air Force Dogs	5 to 10 months	5 months	Approach of an unfamiliar human with a dog unknown	–	–	Offensive reactivity scores higher than in intact dogs
Lehner & von Reinhardt, 2013	Surveys	625	–	–	–	–	Aggression towards other dogs Aggression towards persons	55.2% (from 58) 55.9% (from 39)	–	–
Moxon et al., 2022	Prospective cohort study (1- and 3-year behaviour C-BARQ questionnaires, telephone interview)	134 140 (134 PPN and 140 controls after 1year, 102 PPN and 91 controls after 3years)	Golden retriever and Labradors and crosses	Assistance dogs from one organisation (good husbandry and health care)	6 months (PPN), controls: after first oestrus (mean age=387.8 ±3.2days)	1 and 3years, respectively	Escaping Aggression Fear and anxiety Excitability Attachment and attention seeking Social behaviour	Decrease in aggression scores between 1 and 3years in 8 PPN and 8 controls	No sign. differences between groups	Increase in aggression score between 1 and 3years in 20 PPN and 9 controls (more likely for golden retriever cross Labradors)
O'Farrell & 'acheay, 1990	Prospective cohort study (surveys)	150 spayed 150 intact	–	–	<12 months >12 months	0 days and 6 months	Aggressive dominance towards owners	8.9% 11.9%	62.2% 73.8	28.9% 14.3% ⇒Detrimental mainly when aggression was present before gonadectomy in bitches <12 months (50%)

Table 4. (Continued)

Authors	Method	Number of female dogs	Breeds	Husbandry utilization	Age at gonadectomy (n)	Time between gonadectomy and study	Behavioural problem	Improvement (n)	No change (n)	Deterioration (n)
Ryce et al., 2013	Survey	–	–	Roaming dogs	–	–	Maternal aggression	Bites to protect pups significantly reduced	–	–
Reisner et al., 2005	Survey – email	1053 questionnaires 219/559 females were intact	English springer spaniels	Private, kennel	–	–	Aggression towards owner	–	–	Gonadectomised females were more owner-aggressive than intact dogs
Spain et al., 2004b	Retrospective cohort study (survey+ veterinary records)	499 484	Different breeds	Stray, owner surrender	<5.5 months ≥5.5 to 12 months	3 months to 11 years	Aggression and nuisance behaviour*	–	M+f: Barking 34.2% Noise phobia 52.6% (not sign. when analysis restricted to serious problems) Separation anxiety <5.5 m: 14.2% (OR 0.72), ≥5.5 18.7% (OR 1) In total: no sign. effect on aggression, noise phobia, separation anxiety	–
Wright & Nesselrode, 1987	Interviews with owners	42 (29 spayed, 13 intact)	Mongrels, German shepherd dog, English springer spaniel, Doberman, golden retriever, Dachshund	Sporting, mixed, working, terrier, non-sporting ground, toy	–	–	Aggression Stimulus reactivity	–	–	Spayed versus intact (n=) 19 versus 3 16 versus 8
Zink et al., 2014	Retrospective cohort study (cross-sectional)	209 157 459	Magyar Vizsla	–	≤6 months 7 to 12 months >12 months	–	Behavioural problems† (mostly fear of storms)	–	–	Odds 1.8-fold higher than in intact dogs Fear of storms: odds sign increased in all age groups compared to intact dogs
Zink et al., 2023	Surveys (cross-sectional)	2281 spayed 792 intact	–	–	–	–	Problematic and nuisance‡	Odds decreased with increasing time gonads were present and size (OR 0.91)	–	Spayed females were more likely to develop problematic behaviour than intact dogs (939/2281: 41% versus (221/792; 28%) Dismissed: 51.9% (40/110) 47.2% M+F in the group >7 months
Zlotnick et al., 2019	Retrospective data evaluation	245	Golden retrievers, Labrador, other breeds	Service dog candidates	<7 months 7 to 11 months >11 months	–	Behavioural problems during training	–	Graduated: 37.7% (29/99)	–

M Male, f Female, PPN Prepubertal neuter OR Odds ratio, OSS Ovary-sparing-surgery

\*Aggression towards animals, destructive behaviours that persisted past 1 year of age, digging holes in the yard, escaping while owner was home, excessive barking, excitement around visitors, excessive jumping, excessive licking or chewing of skin, noise phobias, separation anxiety, sexual behaviours, shyness and urination in the house when frightened or excited

†Fear of storms, separation anxiety, fear of noises, fear of gunfire, timidity, excitability, submissive urination, aggression, hyperactivity and fear biting

‡Problematic: aggression, anxiety-based behaviour, extreme fears; nuisance: urine marking, mounting; normal behaviour but unwanted

following gonadectomy between extreme aged dogs and dogs with normal longevity (Cooley et al., 2003). In this study, resistance to cancer disease was found to be a major factor for exceptional longevity, with life-threatening diseases occurring at a later stage of life in these dogs regardless of their neuter status (Cooley et al., 2003). In a later series of studies on long-lived Rottweilers, the number of years lived as intact were found to be associated with significantly greater longevity, with female dogs living at least 4.3 years as intact having a duration of life 17 months longer than those living less than 4.3 years as intact (Waters et al., 2009). Also, female Rottweilers spayed before 1 year of age had an expected lifespan 1.5 years shorter than their intact counterparts (Joonè & Konovalov, 2023). On the other hand, other studies on Golden Retrievers (Kent et al., 2018) or Vizlas (Zink et al., 2014) show contrasting data or no difference in life expectancy. Female dogs living longer have a higher risk of developing diseases such as mammary neoplasia or pyometra, but the fatality risk was moderate (mammary neoplasia) or low (pyometra) resulting in increased longevity (Kengeri et al., 2013; Waters et al., 2017) (Table 5).

This topic is very complex and the literature still controversial; controlled studies in breeds other than Rottweiler are lacking. Life expectancy is multifactorial and not only dependent on gonadal steroids.

## 4.2 | Male dogs

### 4.2.1 | Reproductive tract diseases

**4.2.1.1 | Testicular diseases:** Gonadectomy prevents the dog from developing testicular diseases such as tumours and non-infectious and infectious diseases, leading to testicular degeneration, fibrosis or inflammation. Although uncommon, some testicular tumours are malignant and can be life threatening. According to cells of origin these tumours may be divided in sex cord stromal tumours (Leydig- or Sertoli-cell derived) and germ cell tumours (seminoma, teratoma) or mixed tumours. Testicular tumours account for 94.1% of male genital tumours (Liao et al., 2009) and 16 to 27% of all tumours in male dogs (Dow, 1962; Grieco et al., 2008; Liao et al., 2009). Leydig cell tumours are most common in dogs with a frequency of occurrence of  $\geq 50\%$  dependent on study population (Gazin et al., 2022; Grieco et al., 2008). Leydig tumours are only rarely malignant or secrete hormones (Kudo et al., 2019). Sertoli cell tumours are less frequent among testicular tumours (7.4 to 8%; Gazin et al., 2022; Grieco et al., 2008) but they produce oestrogens in  $>50\%$  of cases. Approximately 70% of abdominal Sertoli cell tumours are endocrinologically active resulting in hyperoestrogenism (Quartuccio et al., 2012). Alopecia, anaemia and myelotoxicity may occur in up to 15% of dogs with oestrogen secreting Sertoli cell tumour (Fig 68) (Quartuccio et al., 2012; Sontas et al., 2009) and even the development of mammary tumours maybe triggered in dogs with this condition (DeForge, 2020; Pulley, 1979; Quartuccio et al., 2012; Walker, 1968; Warland et al., 2011). Metastases of testicular tumours in dogs are considered rare but the frequency of occurrence is higher in malignant and endocrinologically active tumours (Pulley, 1979). Testicular tumours frequently occur in elderly dogs particularly in those older than 10 years; however, occurrence in much younger dogs is possible and is frequently related to cryptorchidism (Liao et al., 2009). More than 50% of all testicular tumours arise from retained testes; Sertoli cell tumours, seminomas and mixed germ cell-stromal cell tumours were reported to occur in cryptorchid dogs (Liao et al., 2009). The frequency of occurrence of testicular tumours may be increasing and some authors suggest the environment as a contributing factor (Grieco et al., 2008).

Gonadectomy prevents testicular diseases and is recommended in case of testicular tumours and treatment resistant diseases of the testes. In case of retained testes and hormone-secreting tumours, gonadectomy is obligatory to prevent hyperoestrogenism and metastases. Ipsilateral orchiectomy may be performed if fertility of the affected dogs should be prolonged and provided that the con-

**Table 5. Health benefits of sterilisation with loss of gonadal steroid hormones in male dogs**

Condition	Occurrence (%)	Substantial morbidity*	Breed at risk†	Influencing factors
Testicular tumours	16 to 27% among all tumours	Yes	No	Age, cryptorchidism, environmental factors
Benign prostate gland hyperplasia (BPH)	32.8% in dogs aged 7 to 10 years, 50% of all canine diseases	Yes	Yes‡	Age
Prostatitis	Dependent on population	Yes	No	Other prostatic diseases
Perianal gland adenomas	–	No	Yes§	Androgens, oestrogens
Transmissible venereal tumour (TVT)	<1	Yes	No	Demography, mating
Perineal hernia	–	Yes	No	Age, enlarged and dislocated prostate gland

\*Can be life-threatening

†According to literature

‡Large breeds; Doberman, Rottweiler, German shepherd dog, Rhodesian ridgeback and Labrador retriever

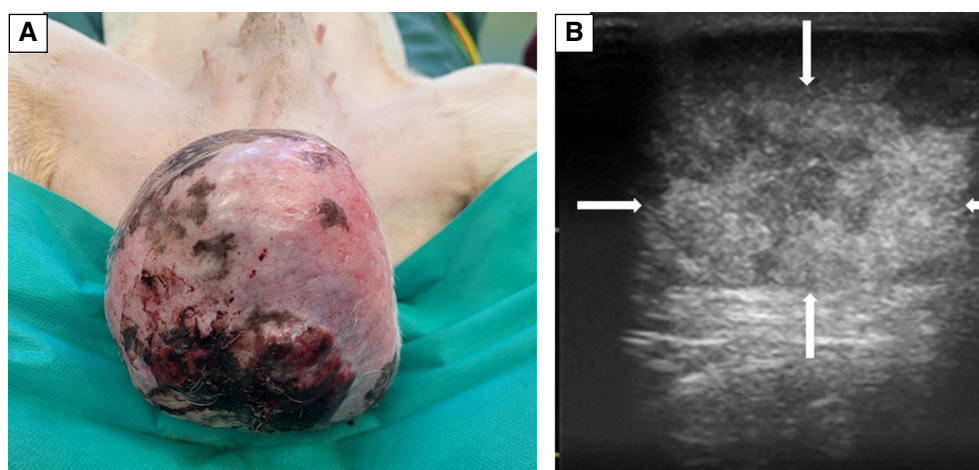
§Cocker spaniels



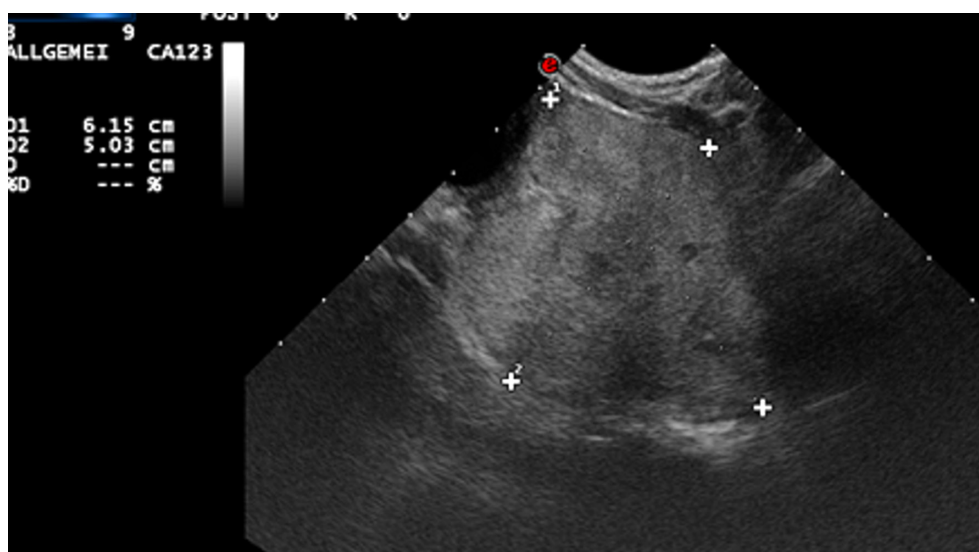
tralateral testis is macroscopically normal. However, anecdotal information indicates that the same type of tumour may subsequently develop in the contralateral testicle, therefore clients should be warned about this potential risk.

#### 4.2.1.2 | Prostate gland diseases

**4.2.1.2.1 | Benign prostatic hyperplasia:** The growth of the canine prostate gland until puberty or shortly thereafter is androgen dependent but the subsequent development of benign prostatic hyperplasia (BPH) is multifactorial with age, weight and breed being considered risk factors. An increase in production and uptake of dihydrotestosterone (DHT) and perhaps a shift in the ratio between testicular production of (lowering) androgens and (rising) oestrogens are the most important triggers for the outward, hyperplastic growth of the gland (Fig 69) (Holst & Nilsson, 2023). BPH is the most frequent prostatic condition in intact, ageing male dogs; occurring in 80% of intact males >5 years and in >95% of males >9 years (Berry et al., 1986; Krawiec & Heflin, 1992; Lévy et al., 2014; Polisca et al., 2016; Sirinarumitr et al., 2001). Clinical BPH accounts for 6.2% of diseases in male dogs aged <4 years, for 17.5% in those aged 4 to 7 years, for 32.8% in those aged 7 to 10 years and for 43.5% in dogs aged ≥10 years; also, it accounts for 50% of all canine prostatic diseases (Krawiec & Heflin, 1992). BPH may be observed in dogs as young as 2 years of age



**FIG 68. Testicular tumour. (A) Large testicular tumour and (B) its sonographical appearance (arrows). Tumour size and appearance may be highly variable. Alopecia, a pendulous prepuce, mammary enlargement and dark colour of the skin are clinical signs highly suspicious of hyperestrogenism**

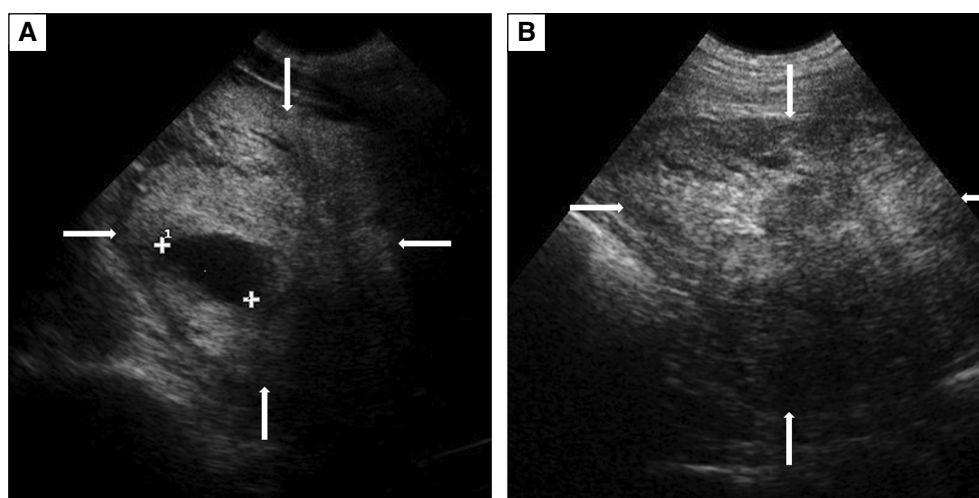


**FIG 69. Benign prostate gland hyperplasia (BPH), sonographical image. Sonographical image of a prostate gland with BPH (crosses). The gland is enlarged, the parenchyma hyperechoic but homogenous. These sonographical signs for BPH only require treatment in connection with clinical signs of the disease**

(Berry et al., 1986) but becomes more common with increasing age with >60% incidence after the age of 5 years and reaching values close to 100% in elderly dogs (Brendler et al., 1983; Cunto et al., 2022). Large breeds like Doberman, Rottweiler, German shepherd dog, Rhodesian ridgeback and Labrador retriever seem to be predisposed (Das et al., 2017; Polisca et al., 2016; Werhahn Beining et al., 2020; Wolf et al., 2012). The first clinical sign is often a serosanguineous preputial discharge; as the outward growth proceeds, defecation problems may occur while urination problems are reportedly uncommon in dogs with BPH. A frequent complication of BPH is ascending infection (Cunto et al., 2022; Read & Bryden, 1995; Ruetten et al., 2021; Smith, 2008). Any method of sterilisation that eliminates gonadal steroid hormone secretion or reduces the effects of DHT (e.g. gonadectomy, hormonal down-regulation) will prevent or resolve BPH (Johnston et al. 2001c; Nizański et al., 2014; Polisca et al., 2013; Angrimani et al., 2020; Schäfer-Somi, 2022). A rapid decrease in testosterone takes place in the first week following gonadectomy and prostatic volume starts to decrease within days, reaching up to 50% reduction within 2 to 3 weeks (Barsanti & Finco, 1986; Cazzuli et al., 2022). A decrease in size can already be felt on digital rectal palpation after 1 to 2 weeks (Cunto et al., 2019) and bloody preputial discharge in most cases will cease within 4 weeks after gonadectomy (Read & Bryden, 1995). Following off-label application of long-term GnRH-agonists like deslorelin, involution takes place over a 4-12-week period (Junaidi et al. 2009b; Nizański et al., 2014, 2020; Polisca et al., 2013) and reaches a decrease of >50% within 6 weeks with a 4.7 mg implant. Use of long-term GnRH-agonists sometimes requires initial treatment with short acting anti-androgens for 1 to 2 weeks for suppression of flare-up signs depending on prostatic size at the time of treatment (Masson et al., 2021).

Medical therapy to decrease prostate gland volume including anti-androgens and long-term GnRH agonists (if available), or gonadectomy will be curative in dogs with signs of BPH. Gonadectomy or chemical castration will also prevent development of BPH. Whether or not to opt for gonadectomy as a treatment for dogs with BPH is a difficult decision which should be taken considering all potential health detriments including also the risk of prostatic neoplasia in adult to elderly dogs (see Chapter 5.2.1.1).

**4.2.1.2.2 | Prostatitis:** Inflammatory diseases of the prostatic parenchyma occur independent of age and are frequently caused by bacterial infections ascending via the urethra or spreading via the blood circulation. Causative organisms are mainly *E. coli*, *Staphylococcus* spp., *Streptococcus canis*, *Proteus vulgaris*, *Pseudomonas* spp., *Klebsiella* spp., *Brucella canis*, *Mycoplasma canis*, *Leishmania* spp. and anaerobic bacteria; viruses, blastomyces and cryptococci are rare (Barsanti & Finco, 1986; Dorfmann & Barsanti, 1995; Krawiec & Heflin, 1992; L'Abée-Lund et al., 2003; Lea et al., 2022; Lévy et al., 2014; Nizański et al., 2014; Reed et al., 2010; Slaviero et al., 2023). In many cases, an underlying prostatic disease is present (e.g. BPH, squamous metaplasia, neoplasia) (Fig 70) (Johnston et al. 2001c). Prostatitis can affect both gonadectomised and intact dogs but most commonly occurs in intact dogs secondary to BPH (Nizański et al., 2014; Ruetten et al., 2021). Acute prostatitis causes serosanguineous preputial discharge, acute abdominal pain, fever, urination and/or defecation problems, sometimes vomiting and diarrhoea. Diagnosis should include bacterial culture from prostatic secretion, semen or urine. Treatment should include intravenous fluid therapy, pain management and antimicrobials according to sensitivity testing and tissue penetration. In case of chronic prostatitis, acute signs are lacking; instead, recurring signs of BPH are evident together with weight loss and a poor coat condition (Cunto et al., 2019; Johnston et al. 2001c). Administration of anti-androgens such as cyproterone acetate, delmadinone acetate or osaterone acetate to reduce prostate gland volume is considered an important measure in both acute and chronic cases (Lea et al., 2022; Ruetten et al., 2021); the effect of deslorelin in case of chronic



**FIG 70. Prostatitis, sonographical images.** Sonographical images of (A) acute prostatitis (arrows) and (B) chronic prostatitis (arrows). Note the irregular structure and the cyst on image (A) (crosses) and the even more irregular structure with more hyperechoic regions on image (B). It is not possible to differentiate between chronic prostatitis and prostate gland neoplasia by sonography

prostatitis has not been investigated yet. The effect of anti-androgen treatment may help in reaching a decision on gonadectomy; the option of gonadectomy should be discussed in case of recurrence. In dogs with experimentally induced *E. coli* prostatitis, gonadectomy significantly shortened the interval from infection to recovery (Cowan et al., 1991). The use of long-acting GnRH agonists may potentially have a similar effect although there is as yet no evidence for their advantage over gonadectomy.

Anti-androgens may be recommended to decrease the gland size quickly. Gonadectomy is a useful, accompanying measure to resolve and prevent prostatitis.

**4.2.1.2.3 | Prostatic neoplasia:** As the canine prostate quickly shrinks following orchiectomy (Barsanti & Finco, 1986), orchiectomy has historically been regarded as a good way to prevent prostatic neoplasia. However, this is a very controversial area as prostatic neoplasia is actually more common in gonadectomised than intact dogs (Sorenmo et al., 2003; Teske et al., 2002). For a full discussion on the relationships between gonadectomy and risk of prostatic neoplasia in dogs, see Chapter 5.2.1.1.

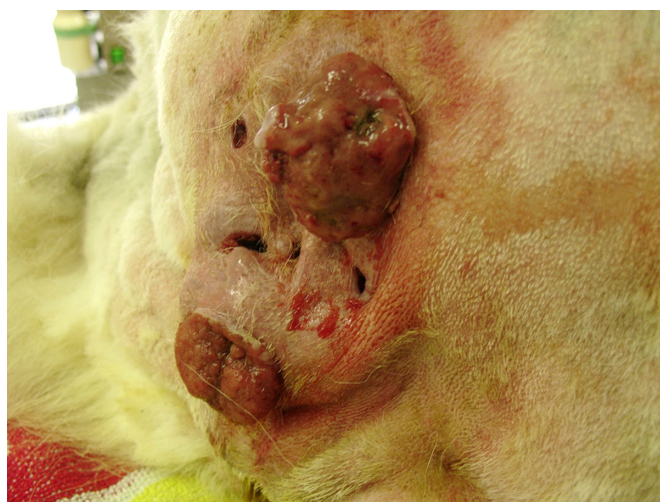## 4.2.2 | Perianal gland tumours

Perianal gland tumours (Fig 71) are tumours of modified sebaceous glands in the skin of the perianal region; they are the third most common tumours in intact, middle-aged to >9-year-old male dogs (Brodzki et al., 2021). Most tumours are perianal gland adenomas (for review: Repasy et al., 2022). Since androgen and oestrogen receptors are expressed in the glands as well as in both benign and malignant tumours (Brodzki et al., 2021; Pisani et al., 2006), steroid hormones may trigger tumour growth, especially androgens (Hayes & Wilson, 1977; Isitor & Weinman, 1979; Pisani et al., 2006). A breed predisposition for cocker spaniels is described (Hayes et al., 1981; Hayes & Wilson, 1977). The tumours are mostly benign (adenoma, epithelioma) but about 12 to 17% are malignant (adenocarcinoma) and may metastasize to the nervous system and vertebrae. In case of adenomas, testosterone removal through gonadectomy leads to remission in 95% of cases (Wilson & Hayes Jr, 1979). The expression of androgen and oestrogen receptors is significantly higher in canine adenomas than in carcinomas (Brodzki et al., 2021). Recently, combined treatment of perianal gland tumours in male dogs with the anti-oestrogen tamoxifen and the anti-androgen cyproterone acetate was effective in tumours with high expression of androgen and oestrogen receptors (Brodzki et al., 2021). In case of adenocarcinomas, surgical removal combined with chemotherapy or radiation therapy is recommended (Williams et al., 2003).

Gonadectomy is an effective treatment for adenomas and epitheliomas. Anti-hormonal therapy is beneficial in case of adenomas. Anecdotal evidence indicates that GnRH agonists may be an effective way of treating perianal gland adenomas and epitheliomas.

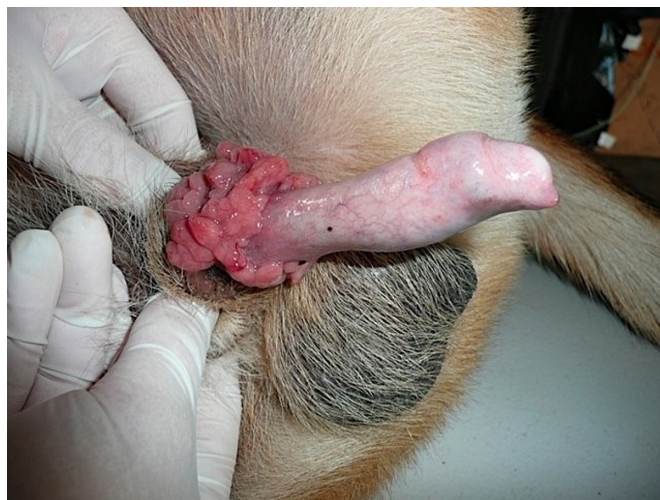
## 4.2.3 | Transmissible venereal tumour

As in female dogs, gonadectomy reduces the risk of TVTs (Fig 72), probably by reducing libido and therefore, the frequency of mating (Strakova & Murchison, 2014) – see Chapter 4.1.1.5.



**FIG 71. Perianal gland tumour. Large perianal gland tumours. Histopathology revealed adenocarcinoma**



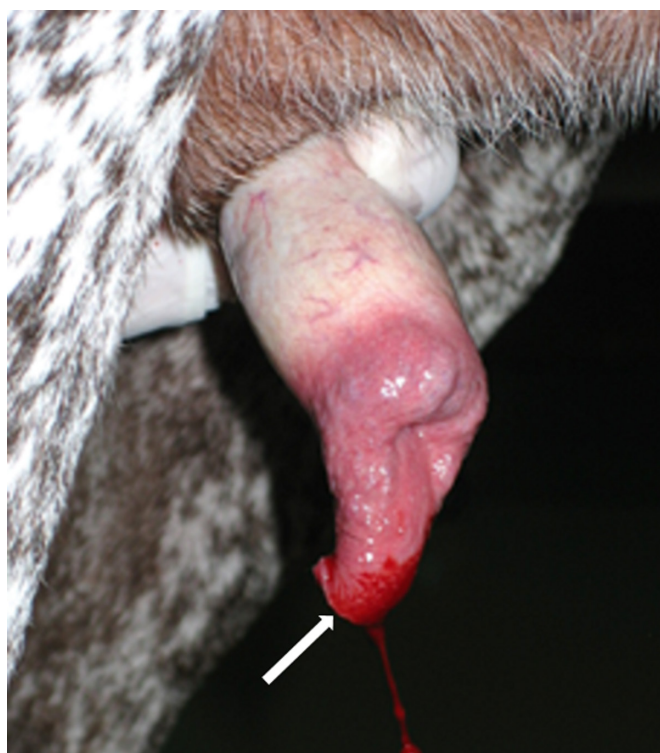


**FIG 72. Transmissible venereal tumour in a male dog. The tumour originated from the mucous membranes of the bulb of penis**

#### 4.2.4 | Urethral prolapse

Urethral prolapse (urethral mucosa protrusion beyond the tip of the penis) occurs most commonly in young, male, intact brachycephalic breeds, mostly English bulldogs and Yorkshire terriers (Fig 73). A genetic predisposition has been suggested (Carr et al., 2014; McDonald, 1989; Ragni, 2007; Sinibaldi & Greene, 1973). Furthermore, concomitant diseases that increase intra-abdominal pressure, such as urocystoliths, brachycephalic syndrome or congenital abnormality of the urethra may contribute to the problem. The prolapse was reported to be more severe in sexually active dogs (Osborne & Sanderson, 1995). Therefore, it has been suggested that urethral prolapse may recur if testosterone concentration is not reduced although this has not been confirmed (Carr et al., 2014). There is no information on the effect of hormonal-downregulation as an adjunct treatment of urethral prolapse.

Combination of urethral prolapse repair with gonadectomy may be beneficial in individual cases.



**FIG 73. Urethral prolapse. Urethral prolapse in a dog, the protruded mucous membranes started to bleed due to irritation (arrow)**

#### 4.2.5 | Perineal hernia

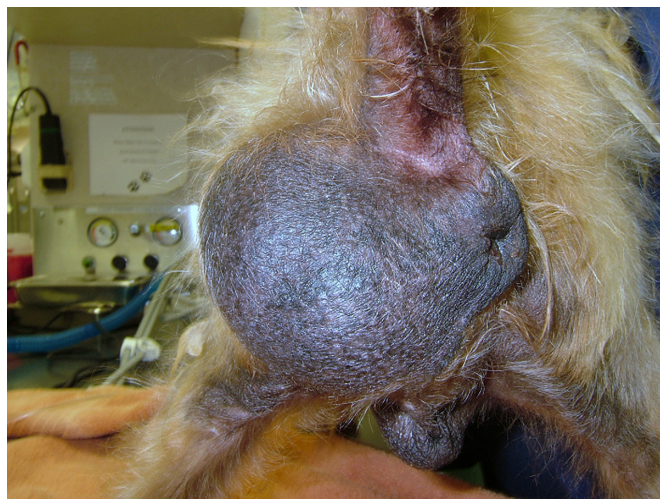In cases of prostate gland diseases in ageing male dogs, an increase in prostate gland size and dislocation may cause among other problems (see chapter on BPH) difficult defecation (tenesmus) and breakdown of the pelvic diaphragm (Fig 74) (Gill & Barstad, 2018). In a recent prospective case–control study (Åhlberg et al., 2022), dogs with perineal hernia (n=46) were examined by CT imaging and the prostate glands compared to those of intact dogs of similar age (n=23). The dogs with perineal hernia had significantly larger prostate glands with more intraprostatic and paraprostatic cysts, and more often showed heterogeneous parenchyma and focal mineralisation than the control group. Furthermore, the authors found dislocations and rotations of the gland inside the abdomen of dogs with perineal hernia (Åhlberg et al., 2022). A thorough andrological examination including ultrasonography/and or CT of the prostate gland is recommended in all cases of perineal hernia, since many dogs with perineal hernia suffer from severe prostate gland diseases (Åhlberg et al., 2022; Bellenger, 1980; Brissot et al., 2004; Hosgood et al., 1995).

Gonadectomy or hormonal treatment to decrease the prostate gland size will be beneficial when a perineal hernia is diagnosed in combination with prostate gland disease. However, as perineal hernia is a disease more common in adult to elderly animals, the health detriments of gonadectomy should be considered when advising the owner, especially with reference to the risk of development of prostate gland cancer.

#### 4.2.6 | Behavioural concerns

The impact of gonadectomy on reproductive behaviour is usually reported to be more pronounced in males (Heidenberger & Unshelm, 1990; Zink et al., 2023), but male behaviour is a complex issue. Problematic/nuisance behavioural concerns can have multiple causes and are rarely solved by gonadectomy alone. As in females, retrospective studies investigating the effect of gonadectomy on behaviour are often inconclusive since important factors like age at gonadectomy, environmental factors, husbandry, contact with other dogs and history of the individual dogs are sometimes not considered, and a control group is often missing (Arlt et al., 2017; Maarschalkerweerd et al., 1997). Furthermore, in many cases, the term behavioural abnormality is not adequately defined. Problematic behaviour, like aggression and anxiety or fear-based behaviours, must be differentiated from nuisance behaviours like urine marking and mounting behaviour, which are normal but unwanted by dog owners (Zink et al., 2023). Some normal aspects of behaviours may be considered as undesired during the special training for working and service dogs (Zlotnick et al., 2019). As in female dogs, at present there is insufficient literature to clarify in how many cases of male dogs with behavioural problems, gonadectomy improved the situation (see Table 6).

It is well established that gonadectomy or hormonal down-regulation in male dogs will decrease libido and associated behaviour and improve unwanted testosterone-dependant behaviour like urine marking in the house, roaming and hypersexuality (Goericke-Pesch et al. 2010b; Hopkins et al., 1976; Knol & Egberink-Alink, 1989; Maarschalkerweerd et al., 1997). In one study, hypersexuality towards people and roaming induced by female dogs in heat decreased in 57% and 64% of dogs, respectively (Maarschalkerweerd et al., 1997). In most studies, urine marking behaviour (especially in the house) decreased after gonadectomy regardless of age (Heidenberger & Unshelm, 1990; Hopkins et al., 1976; Knol & Egberink-Alink, 1989; Kuhne, 2012; Maarschalkerweerd et al., 1997). Unlike urine marking, the effect of gonadectomy on mounting behaviour is age-dependent: it is eliminated when gonadectomy is performed in prepubertal or very young dogs, while it often may persist when gonadectomy is performed in experienced dogs (Beach, 1970).



**FIG 74. Perineal hernia. Huge perineal hernia in a male dog, the anus is dislocated to the right side**

Table 6. Literature review on changes in behaviour after gonadectomy – male dogs										
Authors	Method	Number of male dogs	Breeds	Husbandry, utilisation	Age at gonadectomy	Time between gonadectomy and study	Behavioural problem (examples)	Improvement	No change	Deterioration
Borchelt, 1983	Interviews with family members	174	Breeds and mongrels	–	–	–	Aggression, mostly fear, possessive and male to male	86% of intact male dogs <i>versus</i> 14%	–	–
Heidenberger & Unshelm, 1990	Survey (cross-sectional)	209 (158 with changes in behaviour after neuter)	24% mongrels, 98 breeds	90% indoors, 20% guard dogs	–	–	<ul style="list-style-type: none"><li>• Aggression</li><li>• Hypersexuality</li><li>• Roaming</li><li>• Restlessness, nervousness</li><li>• Anxiety</li><li>• Owner-directed aggression</li></ul>	61.2% (49/80) 93.8% (76/81) 86.1% (37/43) 82.7% (43/52)	27.5% (22/80) 4.9% (4/81) 13.9 (6/43) 15.4% (8/52)	11.3* (9/80) 1.3%† (1/81) 0% (0/43) 1.9%‡ (1/52)
Farhoooy et al., 2018	Canine Behavioural Assessment Research Questionnaire (C-BARQ)	13,795 (~half=male) of which approximately 25% were controls	Purebred and mixed breeds	Outdoor, indoor and mixed	<6months 7 to 12months 11 to 18months >18months	–		30% (3/10)	70% (7/10) No sign. differences between groups	0% (0/10)
Farhoooy et al., 2018	Canine Behavioural Assessment Research Questionnaire (C-BARQ)	13,498 (~half=male) of which approximately 25% were controls	Purebred and mixed breeds	Outdoor, indoor and mixed	<6months 7 to 12months 11 to 18months >18months	–	Stranger-directed aggression Stranger-directed aggression Stranger-directed aggression Stranger-directed aggression	–	No sign. diff. between groups No sign. differences between groups	Odds of aggression (OR=1.219, P=0.014)
Jacobs et al., 2018a	Interviews	1428 neutered males and 329 intact control males	All breeds and mixed breeds	Indoor and outdoor dogs included	Age at gonadectomy not given	Not known	Resource guarding in presence of people	–	–	Neutered males were more likely to be aggressive compared to intact dogs (P<0.01)
Jacobs et al., 2018b	Interviews	1428 neutered males and 329 intact control males	All breeds and mixed breeds	Indoor and outdoor dogs included	Age at gonadectomy not given	Not known	Resource guarding in presence of dogs	–	–	Neutered males were more likely to be aggressive compared to dogs of other sexes and neuter statuses (P<0.01)
Neilson et al., 1997	Interviews	52	Breed not considered	–	>2years	–	Aggression towards unfamiliar people Urine marking, mounting and roaming	<1/3 of dogs (Not significant)	–	Improvement of ≥50% in ≥60% of dogs; of ≥90% in 25 to 40% of dogs
Reisner et al., 2005	Survey – email	1053 questionnaires (history of owner-directed aggression in 510 dogs) 327/494 males were intact	English Springer Spaniels	Private, kennel	–	–	Aggression towards owner [n=29, i.e. 17% of males had been castrated because of aggression to humans and n=10 (6%) because of aggression to other dogs]	m sign. > than f, >3years old dogs and >gonadectomised than intact dogs	–	–
Zink et al., 2014	Retrospective cohort study (cross-sectional)	153 141 312	Magyar Vizsla	–	≤6 months 7 to 12 months >12 months	–	Behavioural problems* (mostly fear of storms)	–	–	Odds 1.8fold higher than in intact dogs (m and f) Fear of storms: odds sign. increased in all age groups compared to intact dogs, and in f>m (1.4-fold)
Zlotnick et al., 2019	Retrospective data evaluation	245	Golden and Labrador retriever and other breeds	Service dog candidates	<7 months 7 to 11 months >11 months	–	Behavioural problems during training	–	Graduated: 37.7% (29/99)	Dismissed 51.9% (40/110) 47.2% male and female in the group <7 months
M Male, f Female, PPN Prepubertal neuter *In n=2 dogs, aggression only occurred after gonadectomy †In n=1 dog ‡In n=5 dogs										



The same was observed when GnRH-agonists were used for chemical castration. In younger dogs, unwanted behaviour like aggression towards other dogs improved more than when the same treatment was applied to older dogs (Goericke-Pesch et al. 2010a; Goericke-Pesch et al. 2010b). The effect may be variable as, *e.g.* mounting behaviour can also occur because of stress or anxiety despite basal testosterone concentration (Goericke-Pesch, 2017; Urfer & Kaerberlein, 2019) and aggression towards humans was not improved after hormonal downregulation in one study (Goericke-Pesch et al. 2010b).

The effect of gonadectomy on boldness-related and aggressive behaviour directed at humans or other dogs is also contradictory. As with human bite injury risk, data are not sufficient for a definitive conclusion. Most authors found that gonadectomy reduces the risk but such conclusions are often based on insufficient data. Furthermore, gonadectomised dogs often enjoy better husbandry (D'Onise et al., 2017). However, most authors agree on a decrease in inter-male aggression (Borchelt, 1983; Maarschalkerweerd et al., 1997; Urfer & Kaerberlein, 2019). In one questionnaire-based study, orchiectomy reduced inter-male aggression by 57%; however, in 4% of dogs, an increase in aggressiveness was observed. The results of behavioural studies based on questionnaires are often difficult to evaluate as owners may be unable to distinguish between different types of aggression (Maarschalkerweerd et al., 1997). Further confounding factors may be subjective interpretation of behaviour, lack of experience and lack of knowledge of dog behaviour and body language (Moxon et al., 2022). Age at gonadectomy might be important in certain cases of aggressive behaviour, with earlier operation preventing an increase in learned unwanted behaviour that cannot be influenced by later gonadectomy or hormonal therapy (Heidenberger & Unshelm, 1990).

A trial to improve aggressive or nuisance behaviour by using a GnRH-agonist implant for chemical castration (if available) is always recommended, since a positive effect should be shown in case of unwanted testosterone-dependant behaviour and the downregulation is fully reversible. The treatment can be discontinued if undesirable/flare-up induced effects are observed or the awaited effect fails to appear (Goericke-Pesch, 2017; Goericke-Pesch et al. 2010a). A recent report on 6 clinical cases (4 males, 2 females) states that the repeated use of deslorelin for years may be regarded as safe (Romagnoli et al., 2023) although more studies are necessary to confirm safety. Severe behavioural concerns should be analysed by a veterinary behavioural expert before irreversible gonadectomy is performed.

#### 4.2.7 | Life expectancy

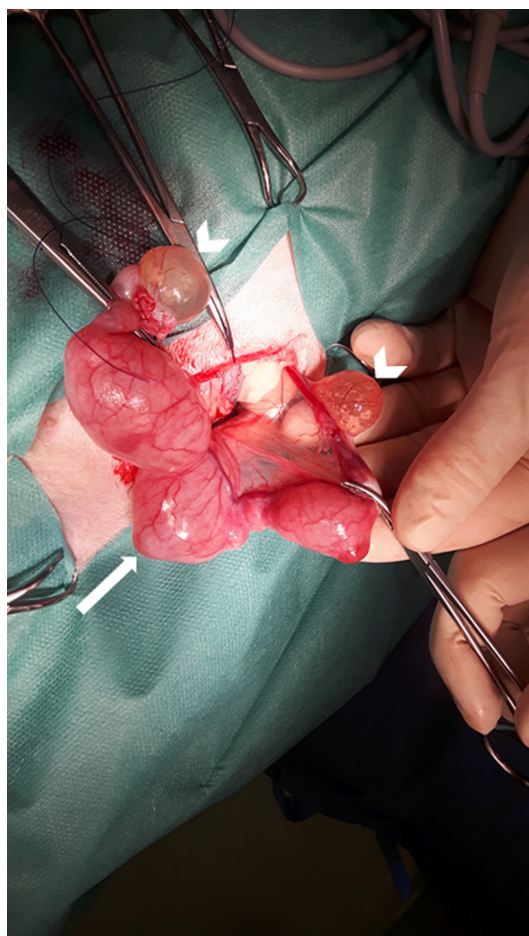
The effect of lifetime exposure to sex hormones on lifespan in male dogs is inconsistent and thorough large-scale studies are lacking. As in female dogs, in many studies, gonadectomy is reported to increase life expectancy (Bronson, 1982; Greer et al., 2007; Hoffman et al., 2013; Michell, 1999; Moore et al., 2001; O'Neill et al., 2013). Unfortunately, results of referral caseloads, questionnaire surveys and pet insurance data are often inconclusive (O'Neill et al., 2013); and in many cases the impact of sex, age at castration, body score index, development of cancer, immunological diseases, breed size and further factors on life expectancy is not considered (Arlt et al., 2017; Cooley et al., 2003; Greer et al., 2007; Salt et al., 2019). A recent retrospective study, evaluating 6018 questionnaires on the relation between life expectancy and reproductive status, revealed that intact male dogs had shorter lifespan compared to gonadectomised individuals; however, longer duration of gonad exposure coincided with longer life expectancy (Zink et al., 2023). On the other hand, in a large retrospective analysis of medical histories of 345 male and female Rottweilers, there was no difference in the percentage of dogs that underwent gonadectomy between extremely old dogs and dogs with normal longevity (Cooley et al., 2003). This also points towards the large impact of age at castration. In the latter study, resistance to cancer disease was found to be a major factor for exceptional longevity and was not related to gonadectomy (Cooley et al., 2003). Literature on this subject is controversial and controlled-scientific studies are lacking. Therefore, at present, no definitive conclusion can be made on the relationship between gonadectomy and life expectancy in male dogs (Urfer et al., 2019).

This topic is very complex and the literature still controversial. Life expectancy is multifactorial and not only dependent on gonadal steroid hormones.

### 4.3 | Cats

#### 4.3.1 | Reproductive tract diseases

Gonadectomy in female and male cats will successfully prevent diseases in the removed tissue. In female cats, ovarian cysts (defined as persistent fluid filled structures in the ovarian parenchyma (Davidson & Baker, 2009) causing persistent oestrus, ovarian cancer as well as uterine diseases like CEH, pyometra and neoplasia, may be avoided by gonadectomy or hormonal down-regulation (Reichler, 2010). Cystic ovaries (Fig 75) can cause hormonal irregularities including hyperoestrogenism, persistent oestrus and/or interoestrus. As in dogs, non-regenerative anaemia due to oestrogen-induced bone marrow toxicity, uterine disease (CEH) and increased susceptibility to infections, among others pyometra, may occur in female cats (Axner, 2010). Ovarian neoplasms are rare in cats and mostly occur in cats >10 years of age (McEntee, 2002; Norris et al., 1969); however, a granulosa cell tumour (GCT) was diagnosed in a 5-year-old female cat (Elbahi et al., 2022). Tumour types are the same in dogs and cats (Gelberg & McEntee, 1985; Nielsen et al., 1976; Norris et al., 1970). In cats, GCT is the most frequently occurring tumour; approximately 50% of GCT are malignant



**FIG 75. Cystic ovaries and pathological uterus in a cat. Large thin-walled cysts are present on both ovaries (arrowheads), the uterus is thin-walled and fluid-filled, with an ampullary shape (arrow). Histopathology revealed follicular cysts and mucometra**

and can metastasize, some produce oestrogens and frequently occur with CEH (McEntee, 2002; Norris et al., 1969). As in dogs, feline CEH is a progressive, degenerative disease of the endometrium leading to proliferative and sometimes inflammatory endometrial changes in older cats. In female cats, this disease is mainly triggered by oestrogens and frequently occurs with ovarian cysts or GCT; bacterial infection and pyometra are a frequent complication (for review: Agudelo, 2005; Hollinshead & Krekeler, 2016). The pathogenesis of pyometra is similar in dogs and cats with progesterone predisposing the uterus to bacterial infections, mostly caused by *E. coli*. However, the condition is less common in cats than in dogs and an incidence of 2.2% by the age of 13 years was reported (Hagman et al., 2014). Pyometra generally occurs in older cats >4 years of age with an increase in occurrence at >7 years in one study; a breed predisposition for Sphynx, Siberian cat, Ocicat, Korat, Siamese, Ragdoll, Maine coon and Bengal was reported (Hagman et al., 2014). Pyometra is a life-threatening disease with an overall case fatality rate of 5.9% (19/335 cats died) reported in one study (Hagman et al., 2014). Uterine tumours were reported with an incidence of 0.29% of all feline tumours over a period of 9.6 years; endometrial (adenosarcomas, adenocarcinomas) and myometrial (leiomyomas, leiomyosarcomas) tumours were diagnosed (Miller et al., 2003) and some malignant tumours like leiomyosarcomas and adenocarcinomas were reported to metastasize (Anderson & Pratschke, 2011; Cooper et al., 2006). Ovarian or uterine diseases may occur also in ovariectomised/ovariohysterectomised female cats in case of an ovarian or uterine remnant. Ovarian remnants may cause recurrent oestrus behaviour or persistent oestrus resulting sometimes in hyperoestrogenism and can be associated with life-threatening stump pyometra (Demirel & Acar, 2012). An oestrogen-secreting teratoma was diagnosed in the ovarian remnant of a 10-month old spayed queen with behavioural signs of heat and a cornified vaginal epithelium (Kustritz & Rudolph, 2001). Adenocarcinomas were diagnosed in the uterine stump of two ovariohysterectomised cats (Anderson & Pratschke, 2011; Miller et al., 2003).

In female cats, gonadectomy or OHE will cure and prevent ovarian and uterine diseases (Table 7).

In male cats, removal of testes will prevent occurrence of lesions and inflammatory diseases in these organs. Orchitis rarely occurs in cats; mostly a bite or another trauma will be causative (Foster et al., 1996) and two reported cases with severe pyogranulomatous and necrotic changes were associated with coronavirus infection (Foster et al., 1996; Sigurdardóttir et al., 2001). Testicular tumours are extremely rare and are mostly associated with cryptorchidism. As in dogs, retained testes should be removed surgically since malignant

tumours like interstitial and Sertoli cell tumours are likely to develop and in one case this was associated with prostatitis and prostatic squamous metaplasia due to an oestrogenic effect (Tucker & Smith, 2008). Other possible tumours are teratomas and seminomas (Miller et al., 2007; Tucker & Smith, 2008). During orchiectomy, care must be taken to fully remove the neoplastic testis and avoid transplantation of cancer tissue as this was reported to have occurred in 5 cases of Sertoli cell tumour developing after orchiectomy at the site of incision (Doxsee et al., 2006).

There are three case reports of a prostatic carcinoma (a condition which is extremely rare also in intact male cats) developing in gonadectomised male cats (Lapshin & Kondratova, 2015; LeRoy & Lech, 2004; Oliveira et al., 2019). Predisposing factors of feline prostatic carcinoma are not described (Palmieri et al., 2022). Prostatic hyperplasia, fibroadenoma and paraprostatic cysts have also been described; however, prostatic adenocarcinoma is most frequently diagnosed (Caney et al., 1998; Newell et al., 1992).

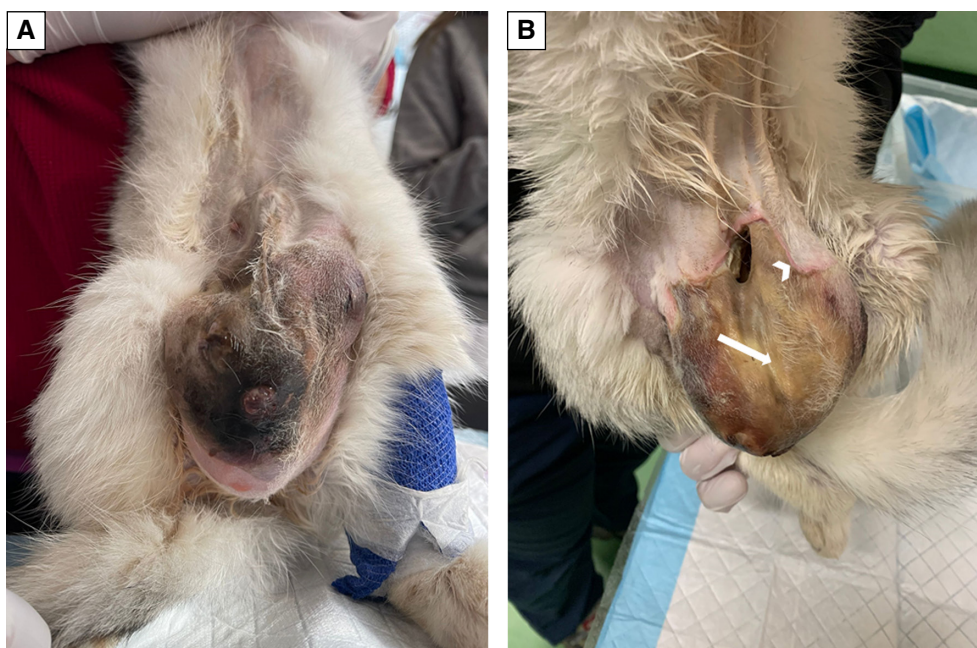
In male cats, gonadectomy will cure and prevent testicular diseases but not adenocarcinomas of the prostate gland (Table 7).

**4.3.1.1 | Inflammatory mammary diseases in female cats:** Mastitis mainly occurs in lactating cats either after parturition, trauma or rarely during pseudopregnancy (Holst, 2022; Wiebe & Howard, 2009). Bacterial infections ascending via the teats or developing after haematogenous spread are the most common cause; even gangrenous mastitis may occur (Fig 76) (Wilson, 2013). Some authors described the occurrence of mastitis secondary to fibroepithelial hyperplasia (Burstyn, 2010; Chisholm, 1993; MacDougall, 2003; Payan-Carreira, 2013). Diseased cats show variable clinical signs like swelling of one or more teats, painful and warm skin, lameness, pathological secretions from diseased teats and fever (Akgül & Kaya, 2016). Local necrosis and sepsis are potentially severe complications. Abscesses and nodules can be present, and in some cases, require surgical intervention (Demirel & Ergin, 2014). Acute mastitis and sepsis can be a life-threatening condition (Demirel & Ergin, 2014; Holst, 2022; Wiebe & Howard, 2009).

Gonadectomy or hormonal down-regulation prevents (pseudo)pregnancy and is therefore a measure to prevent galactostasis and mastitis.

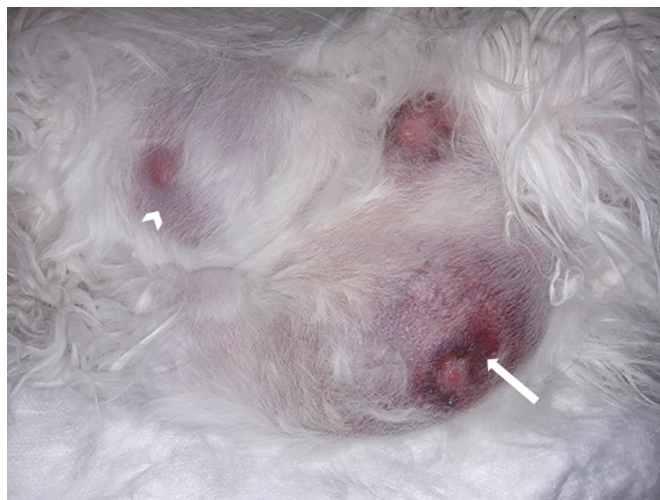#### 4.3.1.2 | Proliferative diseases of the mammary gland in cats

**4.3.1.2.1 | Mammary fibroadenomatosis in cats:** Fibroadenomatosis or fibroepithelial hyperplasia is a proliferative disease of the mammary gland, characterised by rapid, benign hyperplastic/dysplastic growth of the mammary stroma and duct epithelium (Fig 77). Young, intact cats are generally affected and mostly during periods of increased progesterone levels (metestrus, pseudopregnancy, pregnancy) (Jurka & Max, 2009). In older as well as in male cats, the condition is often related to presence of excessively high exogenous administration of progestogens or normal/high secretion of endogenous progesterone (Bethlehem



**FIG 76.** Gangrenous mastitis in a cat. (A) Advanced tissue necrosis. (B) Note the necrotic, yellowish tissue in the middle (arrow) and the demarcation line at the margin (arrowhead); the necrotic tissue detaches from the healthy tissue. The wound was left open, the cat received antibiotics and local treatment



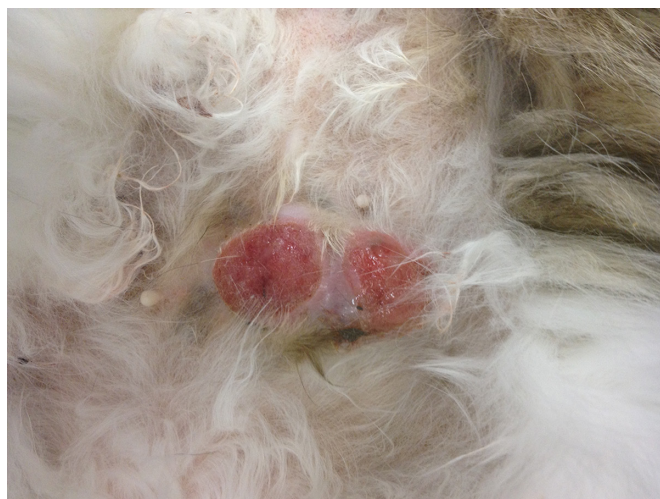

**FIG 77. Mammary fibroadenomatosis in a cat. All teats appeared enlarged, warm on palpation but not painful; in one teat, fluctuation was noticed. Note the reddish-blue colour around the teats (arrow) and the bluish colour of the skin at some sites (arrowhead). The condition resolved after anti-progesterone treatment**

& van der Luer, 1993; Leidinger et al., 2011; Loretto et al., 2005; MacDougall, 2003) coupled with an abnormal concentration of progesterone receptors at the level of the mammary gland (Millanta et al., 2005). However, the cause for the condition is not yet known. The effect of progesterone on growth hormone secretion and the local mitogenic effect of insulin-like growth factor probably contribute to the pathogenesis (Mol et al., 1996) but cannot explain why this condition occurs in some cats and not in others. A few glands or sometimes the whole chain appear enlarged, can be painful upon palpation with multiple fluid filled cysts sonographically visible. Ischemic necrosis and thrombosis are possible complications (Burstyn, 2010; Chisholm, 1993; Holst, 2022; Jurka & Max, 2009; MacDougall, 2003; Payan-Carreira, 2013). Treatment with an anti-progesterone or gonadectomy will cure the condition; however, especially when excessively high dosages of long-acting gestagens were applied and caused the condition, duration of treatment and resolution may take several weeks (Jurka & Max, 2009; Mayayo et al., 2018; Meisl et al., 2003; Sontas et al., 2008; Wehrend et al., 2001).

In male and female cats with mammary fibroadenomatosis, treatment with anti-progesterone (male and female cats) or gonadectomy (female cats) is curative.

**4.3.1.2.2 | Mammary tumours:** The incidence of mammary tumours in female cats varies between reports but was calculated as 0.104% (104 per 100,000 cats) in one retrospective study, and increases with age (Pickard Price et al., 2023). Mammary tumours (Fig 78) comprise 17% of all tumours and 12% of all malignant tumours in female cats. Only skin tumours and lymphosarcomas



**FIG 78. Mammary tumour in a cat. The tumour was exulcerated and irritated by licking. Histopathology revealed adenocarcinoma**

occur more often (Hayes & Mooney, 1985). Mammary tumours mainly occur in intact cats. In one report, the prevalence of mammary carcinoma was 19.1% and of benign mammary tumours was 4.3% in gonadectomised cats, and in intact cats, the prevalence of mammary carcinoma was 28.5% and that of benign mammary tumours 6.4% (Misdorp et al., 1991). In another study, 41% of female cats with mammary tumours had been gonadectomised before tumour development; and 17% of the gonadectomised cats had been operated between 8 and 11 months of age, probably after puberty (Dorn et al., 1968). Most mammary tumours (>80%) are malignant and adenocarcinomas are predominant (Hayes & Mooney, 1985; Hayes et al., 1981). Lymph node metastases were detected in 35% of 37 female cats with malignant mammary tumour (DeCampos et al., 2016). Feline mammary adenocarcinomas resemble human carcinomas in that the tumour mainly occurs in aged cats (>10 years), the incidence is relatively high and histopathologic features, biological behaviour and pattern of metastasis are similar. In both species, mammary neoplasia is among the leading causes of cancer-related death (Hassan et al., 2017; Nascimento & Ferreira, 2021). The impact of endogenous steroid hormones on the pathogenesis is proven (Hassan et al., 2017; Hernandez et al., 1975; Modiano et al., 1991; Nascimento & Ferreira, 2021; Pérez-Alenza et al., 2004). Furthermore, some gestagens like megestrol acetate and MPA trigger hyperplastic /neoplastic changings in male (Jacobs et al., 2010) and female cats (Keskin et al., 2009), when given regularly for years and at high dosages (Misdorp et al., 1991; Romagnoli, 2015). A breed disposition is supposed but not proven; Siamese and Oriental breeds were reported to bear twice the risk in comparison to other breeds (Egenvall et al., 2010; Hayes et al., 1981). Gonadectomy or hormonal down-regulation before puberty is a preventive measure (Reichler, 2010); a reduction of the incidence by 91% was described with gonadectomy under 6 months of age (Overley et al., 2005). Gonadectomy after 8 or 24 months, respectively, was described to exert no preventive effect (Hayes & Mooney, 1985; Overley et al., 2005); only in one study, a protective effect of OE against mammary carcinomas but not against benign tumours was found (Misdorp et al., 1991). There is yet no information on the effect of chronic administration of GnRH-agonists on the prevention of development of feline mammary tumours.

Prepubertal gonadectomy in female cats significantly reduces mammary carcinoma formation.

### 4.3.2 | Infections and diseases of the immune system

Gonadectomy has been claimed to reduce the risk for infection with feline infectious virus (FIV), feline infectious leukaemia virus (FeLV) and coronavirus (feline infectious peritonitis, FIP) (Pesteanu-Somogyi et al., 2006; Rohrbach et al., 2001); the reduction in case of FIV is due to less fighting and reduced risk of bite wounds. However, most gonadectomised cats live indoors while most free roaming cats are intact. Therefore, gonadectomised cats might have a lower risk of getting infected. In one study, the incidence of asthma and gingivitis was reduced in female cats gonadectomised at <5.5 months of age compared to those gonadectomised later in life. In male cats, the occurrence of abscesses was reduced, probably due to less inter-male aggression (Spain et al., 2004b).

There is no evidence that gonadectomy by itself reduces infections and diseases of the immune system.

### 4.3.3 | Behavioural issues

Gonadectomy or hormonal down-regulation of male and female cats increases the devotedness of the cats to their owners as well as decreases aggressiveness towards other cats; irrespective of the age at gonadectomy (Stubbs et al., 1996). Gonadectomy will eliminate persistent behavioural oestrus in female cats. Since reproductive hormones are just one of the triggers of urine marking, gonadectomy or hormonal down-regulation decreases but may not eliminate urine marking in both male and female cats (Cafazzo et al., 2019; Goericke-Pesch et al., 2011; Goericke-Pesch, 2017; Horwitz, 2019; Spain et al., 2004b). Following prepubertal gonadectomy, urine marking was observed in 10% of male and 5% of female cats (Hart & Cooper, 1984).

Gonadectomy can be recommended to decrease aggressiveness towards other cats and to eliminate persistent behavioural oestrus; urine marking will not be improved in all cases.

### 4.3.4 | Life expectancy

Gonadectomised female and male cats are reported to live on average 1 to 4 years longer than intact cats, respectively (Kraft, 1998). Since owned cats are mostly gonadectomised and live indoors, longer life expectancy may be caused by better medical care and safer standards of living of owned cats than what is provided for intact free-roaming cats.

## 5 | HEALTH DETRIMENTS OF STERILISATION WITH LOSS OF REPRODUCTIVE HORMONES

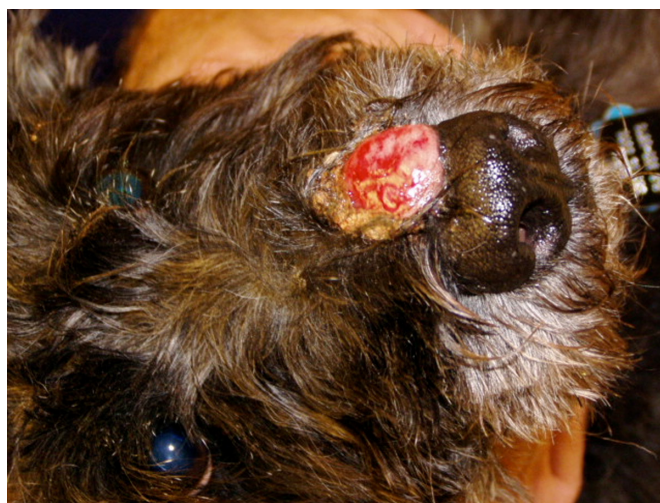Gonadectomy leads to the irreversible loss of reproductive hormones, which coincides with a loss of the negative feedback of gonadal steroids on the HPA. The latter causes permanently increased blood concentrations of LH and FSH (Beijerink et al. 2007b). The

impact of these facts on the development of certain diseases in gonadectomised dogs is currently under investigation (Ettinger et al., 2019; Kiefel & Kutzler, 2020; Kutzler, 2020a, 2023; Zwida & Kutzler, 2022) and may vary between individuals. However, other detrimental effects of gonadectomy are proven and referenced in the current document (Tables 8–10). Concluding statements on detriments of gonadectomy for each condition should not be regarded as final but should be considered in view of corresponding benefits of gonadectomy for the same or connected condition/s. Furthermore, new evidence in this field is continually emerging and may shift the risk/ benefit assessment over time. The effect of age at gonadectomy on incidence of pathological conditions and longevity needs to be addressed in research. Some older studies, veterinary medical and animal hospital associations as well as the American College of Theriogenologists claimed that paediatric gonadectomy (at 6 to 16 weeks of age) is necessary to prevent unwanted pregnancies and to increase adoption rates in shelters by preventing reproductive behaviour (Hoad, 2018; Kustritz, 1999, 2002). Their main argument was that long-term effects of gonadectomy before the age of 16 weeks or until the age of 7 months do not differ significantly (Kustritz, 2002) and even if present, far outweigh the risk of pregnancy. However, the assumption was that shelter dogs and cats generally benefit from gonadectomy. While the quest for sterility as well as arresting reproductive behaviours in shelter dogs are plausible motives in favour of gonadectomy, alternative methods may be an option for that proportion of the adoptee large and giant breed population at increased risk of gonadectomy associated health concerns, particularly when adopted by responsible pet owner.

## 5.1 | Female dogs

### 5.1.1 | Tumours

**5.1.1.1 | Mast cell tumours:** Mast cell tumours (MCT) mainly occur in the dermis and subcutaneous tissue (Fig 79). Different degrees of malignancy are known and those of high grade are extremely malignant and tend to metastasize. They are frequent in dogs; in one study, evaluating data from 168,636 dogs, an incidence of 0.24 to 0.29% was calculated (Shoop et al., 2015; Zink et al., 2014). The incidence among all skin tumours accounts for 10 to 21% (Dorn et al., 1968; Villamil et al., 2011). A breed predisposition was reported for Rhodesian ridgebacks, golden retrievers, Labrador retrievers, Boxers, Pugs, Magyar vizslas and German shepherd dogs (Grüntzig et al., 2016; White et al., 2011). However, when specific breeds were compared to crossbreds without testing for individual breed effects in a multivariable model, no difference in tumour predisposition was observed, whereas bodyweight made a difference with dogs of 20 to 30 kg bodyweight (BW) having 2.6 times the odds ratio of MCT in comparison to dogs <10 kg BW (Shoop et al., 2015). Another factor contributing to tumour incidence is age; a significant increase in incidence in dogs >7 years of age was found in different studies (Misdorp, 2004; O'Connell & Thomson, 2013; Shoop et al., 2015; Villamil et al., 2011). A role of reproductive hormones in the pathogenesis of this condition has been claimed but the issue is controversial with odds ratio and incidence of MCT being higher in owned and intact than in gonadectomised dogs in some studies (Shoop et al., 2015) and higher in gonadectomised than intact dogs in others (Hoffman et al., 2013; White et al., 2011; Zink et al., 2014). A relation between sexual status and tumour occurrence has been reported with gonadectomised female dogs having a higher risk of developing a MCT than gonadectomised males (Grüntzig et al., 2016; Torres de la Riva et al., 2013; White et al., 2011). In female dogs, a higher incidence of MCT has been reported to be associated with gonadectomy at >12 months *versus* gonadectomy at <12 months (Torres de la Riva



**FIG 79. Nasal mast cell tumour.** The tumours can develop at different sites and have different sizes



et al., 2013). Recently, the effect of increasing serum-LH concentrations after gonadectomy on MCT development was questioned. In a recent study, the expression of LH receptors (LHR) in tumour cells was investigated; all MCT (11 specimens, all Patnaik grade II and Kiupel low grade) expressed LHR and the expression was higher in MCT from gonadectomised than in those of intact dogs (Kutzler et al., 2022). All these facts point towards a multifactorial pathogenesis and an increased risk for older and heavier dogs, and specific breeds, with deprivation of sex hormones being another factor. However, the effect of LHR signalling on MCT development remains to be clarified.

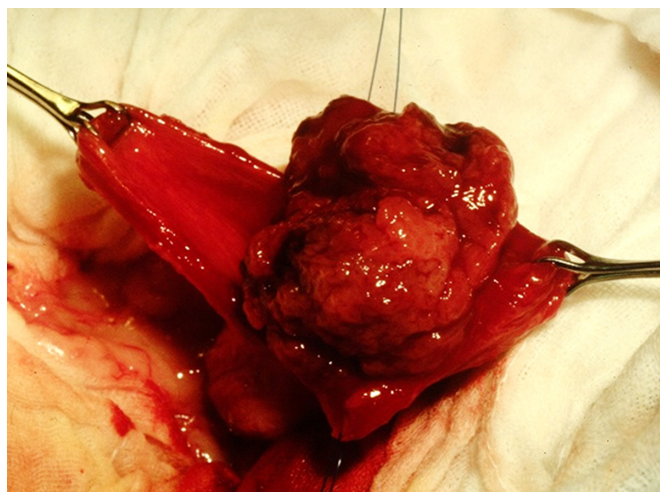
The possibility of a MCT to develop after gonadectomy should be mentioned, when possible, side effects of gonadectomy are explained to owners of dogs at risk.

**5.1.1.2 | Transitional cell carcinomas:** Transitional cell carcinomas (TCC) (Fig 80) are epithelial and malignant, and the most common tumours of the lower urinary tract in dogs (for review: Mutsaers et al., 2003). In dogs, they account for 1.5 to 2% of all canine cancers (Norris et al., 1992; Strafuss & Dean, 1975; Tarvin et al., 1978). They mostly develop at >6 years of age with a median age of 11 years at diagnosis in one study (Knapp et al., 2000; Reed et al., 2013). Further factors probably contributing to the development of TCC are topical insecticides, obesity, cyclophosphamide, female sex and breed (Scottish terrier) (Glickman et al., 1989; Knapp et al., 2000; Macy et al., 1983; Mutsaers et al., 2003; Weller et al., 1979). In case of invasive growth, the urethra (56%) and prostate gland (29%) can be involved (Mutsaers et al., 2003). Lymph node involvement and distant metastases (lung, liver, kidney, spleen, uterus, intestines, vertebrae) are already present at the time of diagnosis in 10 to 20% of cases and at the time of necropsy in up to 49% (Mutsaers et al., 2003).

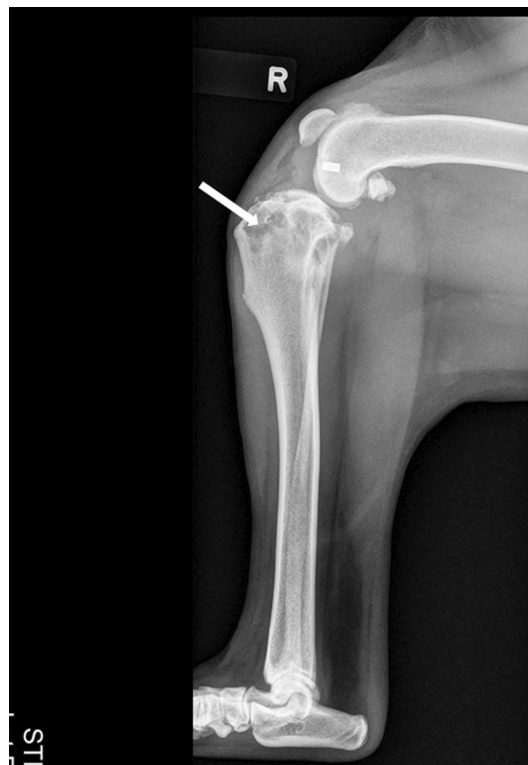Gonadectomy increases the risk of tumour development (Norris et al., 1992). A higher risk for gonadectomised than intact female dogs to develop a bladder TCC was reported (Knapp et al., 2000; Norris et al., 1992). However, the impact of sex is not yet clarified; more females than males were reported to develop this cancer in one study in which the female: male ratio was 1.7:1 (Knapp et al., 2000).

The development of TCC is probably multifactorial; however, the possibility of a TCC to develop after gonadectomy should be mentioned when side effects of gonadectomy are explained to owners of dogs of high risk breeds.

**5.1.1.3 | Osteosarcoma:** Osteosarcoma is a malignant tumour originating from primitive transformed mesenchymal cells (Fig 81). Breed, size, bodyweight and sexual steroids seem to have a very high impact on the occurrence of osteosarcomas in dogs. These tumours mostly occur in large and giant breeds with variable incidences from 0.2% in Labrador retrievers to 8.9% in Irish wolfhounds (Anfinson et al., 2011). Irish wolfhounds, Saint Bernards, Rottweilers, Great Danes, Rhodesian Ridgeback and Leonbergers are most frequently affected (Anfinson et al., 2011; Edmunds et al., 2021; Egenvall et al., 2007; Williams et al., 2023) with male dogs experiencing a higher risk than females (Egenvall et al., 2007; Zink et al., 2023). The risk of osteosarcomas seems to increase with age, breed weight and height (Ru et al., 1998). There is some evidence that gonadectomy increases the risk for osteosarcomas in both female and male dogs of large size breeds (Cooley et al., 2002; Grüntzig et al., 2015, 2016; Hoffman et al., 2013; Ru et al., 1998; Zink et al., 2023). The relative risk to develop an osteosarcoma was described to be twofold among gonadectomised compared to intact dogs (Ru et al., 1998). In Rottweilers, age at gonadectomy was shown to influence the frequency of occurrence of osteosarcoma; the shortest lifetime exposure to reproductive steroid hormones coincided with



**FIG 80. Transitional cell carcinoma in the urinary bladder of a female dog. Note the irregular, cauliflower-like structure**



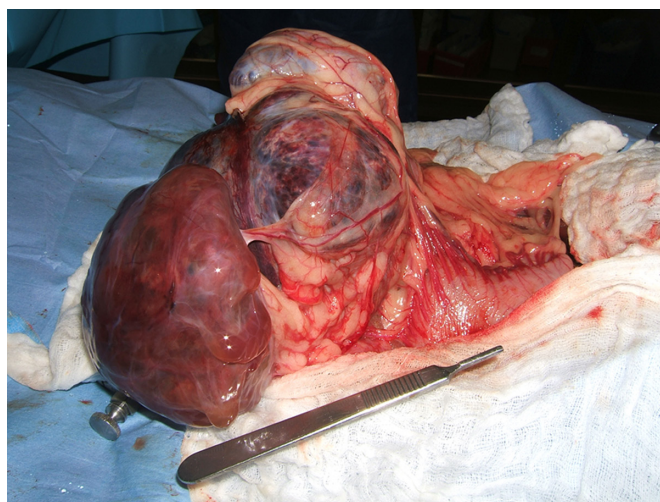
**FIG 81. Osteosarcoma in a female dog. The irregular structure at the head of the bone indicates severe tissue destruction (arrow)**

the highest incidence of osteosarcoma; male and female dogs gonadectomised before 1 year of age had a significantly higher risk to develop an osteosarcoma (Cooley et al., 2002). The effect of age at the time of gonadectomy has not been sufficiently investigated in other breeds but was not related to cancer incidence in one retrospective study with both pure breeds and mongrels (Zink et al., 2023).

The possibility of an osteosarcoma to develop after gonadectomy should be mentioned when possible side effects of gonadectomy are explained to dog owners.

**5.1.1.4 | Lymphomas:** Lymphomas are tumours of the lymphatic system which includes both blood and lymph tumours. The reported prevalence in dogs is variable between studies and also among breeds and is reported as 0.02 to 0.1% (Dobson et al., 2002; Dorn et al., 1967). Australian shepherds and golden Retrievers are supposed to bear an increased risk (Cheng et al., 2019; Hart et al., 2014). In one retrospective study, 30 breeds were shown to have an increased risk for lymphoma and gonadectomy increased the risk, especially in female dogs (Bennett et al., 2018). Similarly in Magyar vizslas, the relative risk to develop lymphoma was 4.3 times higher in gonadectomised female than in intact dogs (Zink et al., 2014). Gonadectomised female dogs were found to have higher odds ratios to develop lymphomas than intact counterparts (Grüntzig et al., 2016; Hoffman et al., 2013; Villamil et al., 2009; Zink et al., 2023). However, in Labradors and German shepherd dogs, gonadectomy does not appear to have the same effect on the development of cancers including lymphomas as in golden retrievers and Magyar vizslas (Hart et al., 2014, 2016). As to the effect of gonadectomy on the pathogenesis of lymphomas, the impact of the long-lasting increase in serum-LH concentration after gonadectomy is currently under investigation. In one study, LH receptor expression was found in lymph nodes, circulating lymphocytes and t-cell lymphoma cell lines. Lymph nodes with lymphomas had significantly higher expression of LH receptor than not-affected lymph nodes; and LH receptor-positive T-lymphocytes were more frequently detected in gonadectomised than intact dogs. Stimulation with LH increased proliferation of lymphoma cells significantly (Ettinger et al., 2019; Kutzler, 2020a, 2023). In golden retrievers, an additional effect of age at gonadectomy was hypothesised as lymphosarcoma was the main cancer in females gonadectomised at <6 months and until 11 months, and the risk was reported to be significantly higher than in intact females (Hart et al., 2014, 2020).

Lymphoma is most common in certain breeds, and likelihood of occurrence may be increased when dogs are gonadectomised, especially female dogs sterilised at an early age. The possibility of a lymphoma to develop after gonadectomy should be mentioned when possible side effects of gonadectomy are explained to dog owners.



**FIG 82. Haemangiosarcoma in the spleen. The spleen was surgically removed, which revealed several large tumours**

**5.1.1.5 | Haemangiosarcomas:** Haemangiosarcomas are malignant tumours originating from pluripotent bone marrow progenitor cells; visceral and non-visceral sites of development can be differentiated (Griffin et al., 2021; Kim et al., 2015) (Fig 82). In dogs, the reported incidence accounts for 5% of all non-dermal primary malignant tumours and approximately 50% of all splenic tumours (Dorn et al., 1968; MacVean et al., 1978; Spangler & Culbertson, 1992). Metastases are frequent in malignant, visceral tumours, rapidly spreading into liver, omentum, mesentery, lungs and brain (Brown et al., 1985; Prymak et al., 1988; Waters et al., 1989). German shepherd dogs, golden and Labrador retrievers and Poodles are frequently concerned, even though the tumour may occur in any breed (Brown et al., 1985; Kent et al., 2018; Prymak et al., 1988; Srebernik & Appleby, 1991; Ware & Hopper, 1999). In one study, genotype-based breed grouping revealed a high occurrence rate in German shepherd dogs, emphasising the impact of genetics at least in some cases (Davies & Taylor, 2020). The tumour is most frequently diagnosed in dogs aged >7 years (Griffin et al., 2021; Ware & Hopper, 1999), and an increased frequency of occurrence was found in dogs with light skin and short hair (Hart et al., 2014, 2016; Torres de la Riva et al., 2013; Zink et al., 2014). In most studies, haemangiosarcomas occur more frequently in gonadectomised than in intact female dogs, although the pathogenesis has not been sufficiently studied (Carnio et al., 2020; Hart et al., 2014, 2016; Grüntzig et al., 2016; Prymak et al., 1988; Su et al., 2015; Torres de la Riva et al., 2013; Ware & Hopper, 1999; Zink et al., 2014, 2023). In one study, gonadectomised female dogs had a fivefold higher relative risk (Ware & Hopper, 1999), and in another study, gonadectomised female Magyar vizslas had a 9.2-fold higher relative risk to develop haemangiosarcoma in comparison to intact bitches (Zink et al., 2014). One group of researchers found expression of LH receptors in commercially available canine splenic haemangiosarcoma cell lines and after stimulation with LH, the proliferation rate increased significantly in two of three cell lines (Zwida & Kutzler, 2022). Thus, the increase in LH after gonadectomy might contribute to the pathogenesis of canine haemangiosarcomas (Zwida & Kutzler, 2022). The age at castration and the time of oestrogen exposure might have an impact since female dogs gonadectomised at >12 months of age had a higher incidence than intact dogs or those gonadectomised at <12 months (Torres de la Riva et al., 2013). In one study, the impact of age on the risk of cancer was found to be significantly larger than the reproductive status (Kent et al., 2018).

Haemangiosarcoma development is probably associated with gonadectomy in female dogs; even though the pathogenesis of this condition is probably multifactorial, the risk of its development following gonadectomy should be explained to dog owners.

## 5.1.2 | Urethral sphincter mechanism incompetence

While there are contributing factors, the loss of gonadal steroid hormones with gonadectomy changes urethral wall composition and pressure profile (Augsburger & Cruz-Orive, 1995). Such morphological alterations cause a reduced function of the canine urethral sphincter, a condition referred to as urinary sphincter mechanism incompetence (USMI) which occurs in 3 to 20% of female dogs any time after gonadectomy (O'Neill et al., 2017; Reichler & Hubler, 2014; Thrusfield et al., 1998). An increase in LH receptor expression in the urinary bladder together with an increase in LH serum concentration has been reported in gonadectomised female dogs; however, the role of such increase in LH receptors in the pathogenesis of USMI has not yet been clarified (Coit et al., 2009; Kutzler, 2023; Kutzler et al., 2022; Reichler et al., 2005). Furthermore, dogs with a bodyweight >20 kg (Stöcklin-Gautschi et al., 2001), aged bitches (Bleser et al., 2011) and individuals with a short urethra (Gregory et al., 1992) are reported to be predisposed. Reported breed predispositions for USMI vary between studies, demography and populations and include among others German shepherd



dog, Dalmatian, Bearded collie, rough Collie, boxer, Rottweiler, Doberman, Old English sheepdog, springer spaniel, Weimaraner and Irish setter (Arnold et al., 1989; Holt, 1990; Holt & Thrusfield, 1993; O'Neill et al., 2017; Stöcklin-Gautschi et al., 2001). The type of surgical technique (OE, laparoscopic OE, OHE) does not influence the incidence of USMI (Lutz et al., 2020; Van Goethem et al., 2006). A younger age at the time of gonadectomy has been claimed to increase the risk of development of USMI with age <3 to 6 months being a threshold below which the risk increases significantly (Pegram et al., 2019; Spain et al., 2004a) although the evidence in favour of such results has been defined as weak (Beauvais et al., 2012b). This is sometimes due to low case numbers or additional factors. In one study, 33 prepubertal gonadectomised female dogs developed USMI (21.2%), but 15/33 dogs had been gonadectomised after puberty (Singer et al., 2021). In spite of all the above, risk factors and potential mechanism, the pathogenesis of USMI is complex; *e.g.* both expected bodyweight and age at gonadectomy were shown to influence the risk of USMI; an increased hazard ratio of USMI with higher adult bodyweight and earlier gonadectomy was found, which was significant at an adult bodyweight of  $\geq 25$  kg (Byron et al., 2010). USMI can be a significant health detriment as ascending and recurrent infections of the urogenital tract and reduction in the human-animal bond may occur. Multiple surgical and non-surgical interventions have been attempted to control this condition, but results are variable (Table 6 to 10).

The risk of USMI development after gonadectomy should be explained to owners, especially in predisposed breeds and individuals.

**Table 7. Health benefits of sterilisation with loss of gonadal steroid hormones in cats**

Condition	Occurrence (%)	Substantial morbidity*	Breed at risk†	Influencing factors
Ovarian diseases incl. granulosa cell tumour (GCT)	Variable	Yes	No	Age
Pyometra	2.2% at 13 years of age	Yes	Yes‡	Age
Uterine tumours	29% of all tumours	Yes	No	Age
Testicular tumours	Extremely seldom	Low	No	Cryptorchidism
Mammary tumours	17% of all tumours, 12% of all malignant tumours	Yes	Yes§	Age, gestagens

\*Can be life-threatening  
†According to literature (see chapter 4. health benefits of gonadectomy)  
‡Sphynx, Siberian cat, Ocicat, Korat, Siamese, Ragdoll, Maine coon and Bengal  
§Siamese and Oriental breeds

**Table 8. Health detriments of sterilisation with loss of gonadal steroid hormones in female dogs**

Condition	Occurrence (%)	Further influencing factors	Breeds at risk*
Mast cell tumour	0.24 to 0.29	BW, age, age at gonadectomy	Yes†
TCC	1	Age	No
Osteosarcoma	0.2 to 8.9	BW, age, size, sex, age at gonadectomy	Yes‡
Lymphoma	0.02 to 0.1	Age at gonadectomy	Yes§
Haemangiosarcoma	5% of all non-dermal primary malignant tumours	Age at gonadectomy	Yes¶
Urinary sphincter mechanism incompetence	5 to 20	BW, age, size, sex, age at gonadectomy, short urethra	Yes
Orthopaedic diseases	0 to 22; dependent on disease and influencing factors	BW, age, age at gonadectomy	Yes††
Hypothyroidism	2.05	Environment, age	Yes‡‡
Hypoadrenocorticism	0.4	Age	Yes§§
Obesity	Increasing with age	Feeding, physical activity, sexual status, age and breed size	Yes¶¶
Behaviour: Increased reactivity in some breeds, increasing fear/shyness depending on age at gonadectomy	Dependent on influencing factors	Age at gonadectomy, housing, training, experiences...	Not proven
Life expectancy: questionable, some indication in female Rottweilers	Dependent on influencing factors	Diseases, especially cancer	Not proven

BW Bodyweight, TCC Transitional cell carcinoma  
\*According to literature (see chapter 5. health detriments of gonadectomy)  
†Rhodesian ridgeback, golden retriever, Labrador retriever, boxer, Pug, Magyar vizsla, German shepherd dog  
‡Irish wolfhound, Saint bernard, Leonberger  
§Australian shepherd, golden retriever  
¶German shepherd dog, Golden and Labrador retriever, dogs with light skin and short hair  
||German shepherd dog, boxer, Rottweiler, Doberman, Old English sheepdog, springer spaniel, Weimaraner, Irish setter  
¶¶Golden retriever, Labrador retriever, German shepherd dog, Magyar vizsla, large breeds>small and miniature breeds  
‡‡Dobermann, golden retriever  
§§Nova Scotia Duck tolling retriever, standard poodle, Bearded Collie, Portuguese Water Dog, Great Dane, West Highland White terrier, Saint Bernard, Wheaten terrier, Leonberger and Rottweiler  
¶¶Small and toy breeds <10 kg

**Table 9. Health detriments of sterilisation with loss of gonadal steroid hormones in male dogs**

Condition	Occurrence (%)	Further influencing factors	Breeds at risk*
Prostate gland tumour	<1	Age, chronic inflammations	Yes†
Mast cell tumour	0.24 to 0.29 (10 to 21% among all skin tumours)	Age, BW (>20 kg)	Yes‡
TCC	<1 (less in males than in females)	Age, sexual status	No
Osteosarcoma	0.2 to 8.9 (more in males than in females)	Age, BW, sexual status, age at gonadectomy	Yes§
Lymphoma	0.02 to 0.1 (less in males than in females)	Age at gonadectomy, sexual status	Yes¶
Haemangiosarcoma	5% of all non-dermal primary malignant tumours, 50% of all splenic tumours	Age, age at gonadectomy, light skin and short hair	Yes
Urinary sphincter mechanism incompetence (USMI)	0.94	Age, short urethral length, caudal bladder position	Not proven
Orthopaedic diseases	0 to 22; dependent on disease and influencing factors	BW, age, age at gonadectomy	Yes††
Obesity	Increasing with age	Feeding, physical activity, sexual status, age and breed size	Yes‡‡
Hypothyroidism	2.05 (less in males than in females)	Environment, age	Yes§§
Hypoadrenocorticism	0.4 (less in males than in females)	Age, sexual status	Yes¶¶
Immune disorders	Less in males than in females	Age, sexual status	No
Behaviour: Increase in aggression in some cases, also dependent on age at gonadectomy	Dependent on influencing factors	Age at gonadectomy, housing, training, experiences...	Not proven

BW Bodyweight, TCC Transitional cell carcinoma  
 \*According to literature (see chapter 5, health detriments of gonadectomy)  
 †Medium sized to large breeds; Shetland sheepdog, Scottish terrier, Bouvier des Flanders, Doberman and mongrels  
 ‡Rhodesian ridgebacks, Golden retrievers, Labrador retrievers, Boxers, Pugs, Magyar vizslas and German shepherd dogs  
 §Irish wolfhounds, Saint Bernards and Leonbergers  
 ¶Australian shepherds and golden retrievers (and 30 further breeds)  
 ||German shepherd dogs, Golden and Labrador retrievers and poodles  
 ††Golden retriever, Labrador retriever, German shepherd dog, Magyar vizsla, large breeds>small and miniature breeds  
 ‡‡Small and toy breeds <10 kg  
 §§Doberman and golden retrievers  
 ¶¶Nova Scotia Duck tolling retriever, standard poodle, Bearded Collie, Portuguese Water Dog, Great Dane, West Highland White terrier, Saint Bernard, Wheaten terrier, Leonberger and Rottweiler

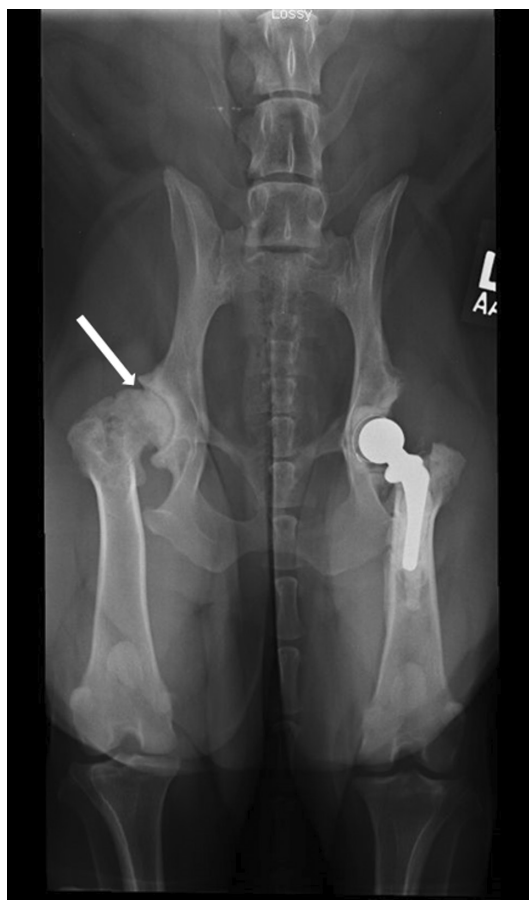**Table 10. Health detriments of sterilisation with loss of gonadal steroid hormones in cats**

Condition	Occurrence (%)	Substantial morbidity*	Breeds at risk†	Influencing factors
Obesity and diabetes mellitus	Frequent	Yes	No	Sexual status (male>female), feeding
Epiphyseal fractures	Frequent	No	No	Sexual status (male>female), prepubertal age at gonadectomy
Tumours	4.43- to 6.47-fold odds compared to intact cats	Yes	No	Age at gonadectomy
Lower urinary tract disease	–	Yes	Yes‡	Overweight

\*Can be life-threatening  
 †According to literature  
 ‡Persian, Manx, Himalayan cats

### 5.1.3 | Orthopaedic diseases

In one large-scale retrospective study, the odds of developing an orthopaedic problem [hip dysplasia (HD), elbow dysplasia, cranial cruciate ligament (CCL) insufficiency, osteochondrosis dissecans, panosteitis, intervertebral disc disease] increased with gonadectomy in both male and females (Dorn & Seath, 2018). Gonadectomy in dogs younger than 12 months was reported to coincide with a higher rate of HD (Fig 83) and cranial CCL injury than gonadectomy after 12 months of age or in comparison to intact dogs (Dorn & Seath, 2018; Hart et al., 2014, 2016, 2020; Torres de la Riva et al., 2013). Service dog candidates (n=245) gonadectomised at <7 months of age had more than twice the risk to develop orthopaedic problems than dogs gonadectomised at >7 months of age, irrespective of sex and Labradors were more affected than golden retrievers (Zlotnick et al., 2019). The negative effect of gonadectomy at <6 months of age or <12 months of age on joint health has been reported in large populations of certain breeds (Hart et al., 2014; Spain et al., 2004a; Torres de la Riva et al., 2013; van Hagen et al., 2005). In golden retrievers, Labrador retrievers and German shepherd dogs gonadectomised at the age of <6 months, the incidence of joint diseases was 2 to 5 times higher in comparison to intact female dogs (Hart et al., 2014; Spain et al., 2004a; Torres de la Riva et al., 2013; van Hagen et al., 2005). In Dachshunds, the risk of intervertebral disc disease was increased when gonadectomised under 12 months of age (Dorn & Seath, 2018). A delayed closure of the epiphyseal plate was thought to contribute to an epiphyseal fracture in a female Rottweiler gonadectomised at the age



**FIG 83. Severe hip dysplasia in female dog. While one side was already surgically corrected, the degree of incongruence and tissue damage of the other hip joint is well visible (arrow)**

of 10 weeks (May, 1998). Rupture of the CCL in dogs is a multifactorial degenerative condition in which many etiologic factors have been considered, including conformation, tibial plateau angle, trochlear notch width, fitness and obesity but none of these has proven singularly causative (Aertsens et al., 2015; Su et al., 2015; Kowaleski et al., 2018). Multiple studies suggest that gonadectomy is an important risk factor, as a higher incidence of CCL rupture is consistently reported in gonadectomised compared to intact dogs (Canapp, 2007; Duerr et al., 2007; Duval et al., 1999; Hart et al., 2020; Zink et al., 2023). The mechanism by which gonadectomy increases the risk for developing a CCL injury is under investigation. An increased expression of LH receptors was detected in the CCL and round ligament as well as structural support tissue of the hip and femorotibial joint of dogs after gonadectomy (Kiefel & Kutzler, 2020; Kutzler, 2020a, 2023). Large breed and increased body condition score, as well as ageing also have a negative effect on the joints (Duval et al., 1999; Hart et al., 2020; Zink et al., 2023).

Occurrence of orthopaedic problems is a possible side effect of gonadectomy, especially when performed at <6 months of age and in large and heavy breeds/individuals. Recommendations about gonadectomy relative to orthopaedic health should be made on an individual basis, considering breed, age and mature bodyweight of the dog. However, in small breed dogs (dachshunds), intervertebral disc disease is also recognised as being at higher risk in gonadectomised dogs (Dorn & Seath, 2018).

#### 5.1.4 | Metabolic and endocrine disorders

Gonadectomised bitches have a reduced metabolic rate and reduced satiety (Bermingham et al., 2014; Houpt et al., 1979; Spain et al., 2004a). Offsetting the consequences of such metabolic changes would require an increased level of physical activity, which is difficult in general for owners of most types of dogs as overweight dogs are less active, and particularly small size dogs (Banfield Pet Hospital Report, 2013). Therefore, many gonadectomised dogs increase their bodyweight (BW) and often develop some degree of obesity (Kustritz, 2007; Lefebvre et al., 2013; Lund et al., 2006; Pegram et al., 2021; Simpson et al., 2019). Gonadectomised female dogs were shown to have a hazard ratio of 1.53 to develop obesity when compared to intact dogs (Benka et al., 2023). Despite sex and gonadectomy, breed size is another influencing factor as small and toy breed (mature BW of <10 kg) were shown to have a



higher hazard ratio for obesity than larger dogs (Banfield Pet Hospital Report, 2020; Benka et al., 2023; Bermingham et al., 2014). Obesity predisposes dogs to many diseases, behavioural abnormalities and reduced longevity (German, 2006; German et al., 2017; Lund et al., 2006; Yam et al., 2016), but not to diabetes mellitus (Guptill et al., 2003; Rand et al., 2004). The incidence of obesity furthermore increased with age (Guptill et al., 2003; Rand et al., 2004; Banfield Pet Hospital Report, 2020). Thus, the effect of gonadectomy on obesity is further influenced by factors like feeding, physical activity, sex, age and breed size (Benka et al., 2023; Banfield Pet Hospital Report, 2020) and can be reversible; however, in one large-scale retrospective study of those overweight dogs that had lost  $\geq 10\%$  of bodyweight, approximately 40% regained weight within the following 6 to 12 months. This was related to a drop in owner engagement, unwillingness to pay for the diet, stress and weather; however, not to gonadectomy (Banfield Pet Hospital Report, 2020). The effect of age at gonadectomy on the risk of developing metabolic disease requires further investigation; in one study, the prevalence of obesity was decreased in male and female dogs gonadectomised at  $<5.5$  months in comparison to gonadectomy occurring between 5.5 and 12 months (Spain et al., 2004a). In another large-scale retrospective study, female dogs gonadectomised before 1 year of age had a significantly lower relative risk to become overweight or obese than those gonadectomised at later ages; however, the hazard ratio stabilised or decreased on average at 2.5 to 3.5 years of age at gonadectomy (Benka et al., 2023). The relationship between age at gonadectomy and the risk of developing metabolic diseases still has several grey areas and require further investigation.

Gonadectomy is also a reported risk factor for both hypothyroidism and hyperadrenocorticism (Belanger et al., 2017; Dixon & Mooney, 1999; Dixon et al., 1999; Panciera, 1994). Canine hypothyroidism develops most commonly as a primary condition and is either idiopathic or caused by an autoimmune disease with probably underlying genetic and environmental factors (Bianchi et al., 2015, 2020; Kemppainen & Clark, 1994). A breed predisposition was reported for Dobermans and golden retrievers (Panciera, 1994). However, there is some evidence that gonadectomy increases the risk for hypothyroidism (Belanger et al., 2017; Dixon & Mooney, 1999; Dixon et al., 1999; Milne & Hayes, 1981; Panciera, 1994; Zink et al., 2023). A retrospective evaluation of a 90,090-patient data sets revealed a higher frequency of occurrence of hypothyroidism in gonadectomised than intact dogs with gonadectomised females being at highest risk. In both sexes, the disease was diagnosed on average 20 months after gonadectomy. Unfortunately, the impact of age at gonadectomy could not be calculated from the available data (Sundburg et al., 2016). This study is interesting since all diagnoses were thoroughly done, date of disease diagnosis and age at gonadectomy were recorded, and only for dogs undergoing surgery at the clinic (Sundburg et al., 2016). Furthermore, in gonadectomised dogs, the concentrations of thyroxine were significantly lower than in intact dogs (Krzyżewska-Młodawska et al., 2014). Recently, expression of LH receptors was detected in canine thyroid cells; the increase in serum-LH concentration following gonadectomy as a contributing factor is therefore currently under investigation (Zwida & Kutzler, 2019). The direct impact of steroid hormones is not yet clarified. Steroid hormones influence thyroid gland hormone secretion and function, and probably the development of thyroid gland disease in humans; expression of oestrogen receptor (ER) alpha and beta was detected, and expression of ER alpha was found to be higher in diseased than in healthy thyroid gland tissue (Kawabata et al., 2003). In dogs, the expression of mRNA of ER alpha was not higher in thyroid carcinoma in comparison to healthy gland tissue (Pessina et al., 2012).

Canine hyperadrenocorticism (Cushing's Syndrome) is a disease coinciding with chronic elevated endogenous cortisol levels (Hoffman et al., 2018). The cause can be either an adrenocorticotrophic hormone (ACTH) secreting pituitary tumour, or a cortisol secreting tumour in the adrenal cortex. A weak but significant relation between gonadectomy and hyperadrenocorticism was reported with a higher prevalence in gonadectomised dogs (Hoffman et al., 2018); however, in an earlier study considering 210,824 dogs with hyperadrenocorticism, no evidence could be proven when data were controlled for other risk factors like age (O'Neill et al., 2016).

Hypoadrenocorticism (Addison disease) is another endocrine disease caused by immune-mediated destruction of the adrenal glands. This leads to a massive decrease in mineralo- and glucocorticoid concentration causing variable symptoms affecting the gastrointestinal tract and causing weight loss and hypovolaemia. Some breeds like the Nova Scotia Duck Tolling retriever, Standard poodle, Bearded Collie, Portuguese Water Dog, Great Dane, West Highland White Terrier, Saint Bernard, Wheaten Terrier, Leonberger and Rottweiler, are reported to bear a genetic predisposition (Famula et al., 2003; Hughes et al., 2007; Oberbauer et al., 2002; Peterson et al., 1996; Thompson et al., 2007). Furthermore, young, middle-aged female dogs are predisposed (van Lanen & Sande, 2014). In one retrospective study, gonadectomised dogs were shown to be at greater risk to develop the disease when compared to intact dogs (Sundburg et al., 2016). A recent retrospective study found a strong association between increasing age and the occurrence of an endocrine disorder (Zink et al., 2023). See also Chapter 5.1.5.

Gonadectomy may trigger the development of metabolic and endocrine diseases; however, further factors may increase this risk.

### 5.1.5 | Immune disorders

The impact of gonadectomy on the immune system is under discussion. Even though sex steroid hormone receptors can be found on organs of the immune system (Farris & Benjamin, 1993; Staples et al., 1999), some authors doubt that gonadectomy increases the risk for immune disorders (Urfer & Kaerberlein, 2019). Nevertheless, an effect of gonadectomy cannot be excluded, which seems to

concern both sexes but, in some disorders, mainly female dogs. A large-scale retrospective analysis on the incidence of autoimmune diseases among 90,090 patients from one animal hospital revealed that gonadectomised dogs had a significantly greater relative risk to develop atopic dermatitis, autoimmune haemolytic anaemia, hypoadrenocorticism, hypothyroidism, immune-mediated thrombocytopenia and inflammatory bowel disease than intact dogs (Sundburg et al., 2016). Furthermore, gonadectomised females have a greater relative risk to develop all these diseases except autoimmune haemolytic anaemia and hypoadrenocorticism than neutered males. And gonadectomised females had a significantly greater relative risk of lupus erythematosus than intact females. In this study, all diagnoses were confirmed, and sex differences concerning the immune system as well as age at gonadectomy and age at diagnosis were considered. Average age at gonadectomy was  $28.6 \pm 0.5$  months for females; the diagnosis of disease was made >20 months thereafter. The abolished anti-inflammatory effect of oestrogens is hypothesised to be at least in part responsible for the increased risk of spayed females to develop the autoimmune disease (Sundburg et al., 2016). Another study found lower concentrations of antibodies in gonadectomised than in intact golden retrievers and Labradors, irrespective of the presence of atopic dermatitis (Lauber et al., 2012). In the same study, golden retrievers were found to have more frequently increased total and specific IgE levels than Labradors; therefore, an influence of genetic factors was suspected. Gonadectomised dogs have an increased percentage of T-lymphocytes in circulation expressing LH receptors compared to intact dogs (Ettinger et al., 2019), which could provide a mechanism for an increase in immune disorders in gonadectomised dogs.

At present, gonadectomy may be considered one of the many factors contributing to increasing the relative risk for an immune disorder, a fact that should be communicated to dog owners before a final decision on gonadectomy is made.

### 5.1.6 | Behavioural concerns

The impact of gonadectomy on behaviour is a complex issue and behaviour after gonadectomy is difficult to foresee (Heidenberger & Unshelm, 1990). Behavioural concerns can have multiple causes; they are rarely caused by gonadectomy alone. Retrospective studies investigating the effect of gonadectomy on behaviour are often confounded since important factors like age at gonadectomy, environmental factors and history of the individual dog are sometimes not considered, and a control group is frequently missing (Arlt et al., 2017). Confounding factors in questionnaire-based studies may be subjective interpretation of behaviour, lack of experience and ignorance of dog behaviour and body language (Moxon et al., 2022). This may contribute to the fact that some studies report no effect and others detrimental effects following gonadectomy (Kim et al., 2006; McGreevy et al., 2018; O'Farrell & Peachey, 1990; Spain et al., 2004a, 2004b). Spain et al. (2004b) reported no significant effect of gonadectomy of female dogs when performed at the age of <5.5 months – 12 months on aggressive behaviour, noise phobias and separation anxiety. Spain et al. (2004b) also stated that adoption at a young age might confound the interpretation of data since this may lead to temporary changes in behaviour and might not be a long-term effect of castration. Few studies report beneficial effects (Heidenberger & Unshelm, 1990; Reece et al., 2013). In Table 4, a literature review is provided – see Chapter 4.1.3.

In one study, ovariectomised female German shepherd dogs were more reactive to the presence of unfamiliar humans and dogs and barked more than intact females (Kim et al., 2005). In a later study of the same group, reactivity scores were assigned to intact and ovariectomised German shepherd dogs, when an unfamiliar human leading an unknown dog approached. Vocalisation, body posture or both were scored. Dogs were 5 to 10 months old at the time of surgery and 10 to 15 months at the time of scoring. Ovariectomised dogs showed more offensive reactivity and received a higher median reactivity score than intact dogs. However, the reactivity scores decreased within 2 months due to habituation; but the change occurred after gonadectomy (Kim et al., 2006). In another study, gonadectomised female dogs were described to be twice as aggressive as intact females (68% *versus* 32%); furthermore, owner-directed aggression increased in female dogs already aggressive before gonadectomy when the gonads were removed before 11 months of age (O'Farrell & Peachey, 1990). Similarly in English Springer Spaniels, gonadectomised females showed increased aggression towards their owners in comparison to intact females (Reisner et al., 2005). In a recent study using questionnaires, data from 792 intact females, 2281 gonadectomised females and 159 female dogs that had undergone ovary-sparing gonadectomy (hysterectomy) were evaluated (Zink et al., 2023). The questionnaire featured questions about problematic behaviour (including aggression, anxiety- and fear-based behaviours), and nuisance behaviour (normal canid behaviour that is objectionable to many dog owners such as urine marking and mounting behaviour). Even though the number of subgroups proved to be insufficient for calculation of a relative risk, a longer duration of gonadal presence reduced the likelihood of problematic and nuisance behaviours (Zink et al., 2023). These results point towards an impact of age at gonadectomy on behavioural changes. A relationship between prepubertal gonadectomy and anxiety/lack of confidence and a general increase in behavioural problems following gonadectomy have been described in female dogs in several studies (Brinkmann, 2015; Spain et al., 2004a; Zink et al., 2014). This was reported to be related to the development of the central nervous system during puberty; brain development is steroid hormone dependent, and during adolescence, a significant increase in nerve cell junctions takes place. The rising steroid hormone levels influence among others neurotransmitters and the benzodiazepine-GABA-receptor complex (Handa & Weiser, 2014; Sisk & Zehr, 2005). Prepubertal gonadectomy might negatively influence learning procedures (Brinkmann, 2015). This is supported by a study on 245 service dog candidates; significantly more (male and) female dogs gonadectomised at <7 months were dismissed for behaviour problems than in the

group of dogs gonadectomised at 7 to 11 months or >11 months (47.2% versus 34.5% versus 49.4%). However, this study focussed on all behavioural problems preventing a dog to become a reliable service dog including poor focus, unpredictability, inconsistency, lack of motivation, poor recall and other factors (Zlotnick et al., 2019). This underpins the fact that for an objective view on the impact of gonadectomy on unwanted behaviour, the kind of disturbance must be defined first. Furthermore, there was a breed effect; golden retrievers and Labradors were less likely to be dismissed for behaviour problems from the training programme than other breeds. In a recent prospective cohort study, prepubertally gonadectomised Labrador and golden retriever crossbreed female dogs were more likely to develop mild aggressive behaviour between 1 and 3 years of age than female dogs gonadectomised after puberty; however, this only occurred in 20/155 prepubertally gonadectomised female dogs and was not statistically significant (Moxon et al., 2022). A recent literature review found a lack of evidence between gonadectomy before and after puberty and behaviour problems (Moxon et al., 2023). Restriction to certain breeds is a frequent confounding factor.

The use of long-acting GnRH-agonists in adult female dogs may result in male-seeking behaviour during the flare-up period as well as in behavioural changes related to subsequent pseudocyesis (Körber et al., 2013). Occurrence of problematic behaviour was not yet reported following delay of puberty with a slow-release GnRH-agonist, provided a flare-up was avoided by treating at the age of 4 to 5 months (Concannon, 1993; Fontaine et al., 2012; Kaya et al., 2013, 2015; Lacoste et al., 1989; Rubion et al., 2006; Schäfer-Somi et al., 2014, 2022; Trigg et al., 2006).

The risk of behavioural changes following gonadectomy should be explained to dog owners. The decision whether a dog should be gonadectomised and at which age should be based on the individual dog, the household as well as the purpose for which the dog is kept (Zlotnick et al., 2019). The literature may help in predicting the possible effects of gonadectomy on behavioural aspects of most of the animals within a population of dogs and cats, but we currently have insufficient understanding and knowledge to accurately predict how gonadectomy would affect the behaviour of an individual animal belonging to either a specific breed or mixed breed.

### 5.1.7 | Paediatric gonadectomy

When puppies are gonadectomised at the age of 6 to 16 weeks (juvenile, paediatric or early spay-neuter), they are predisposed for infections after the operation, if they have a bad constitution and insufficient immunisation (Cardwell, 1993; Howe, 1997; Howe et al. 2000, 2001). During the operation, juvenile puppies are at higher risk for injuries than pre- or postpubertal animals, because the tissue is very fragile. In both male and female dog puppies, gonadectomy before puberty delays growth plate closure of the radius and ulna. This may contribute to the higher occurrence rate for orthopaedic diseases in dogs gonadectomised at <12 months of age in several studies (Hart et al., 2014, 2016, 2020; May, 1998; Spain et al., 2004a; Torres de la Riva et al., 2013; van Hagen et al., 2005; Zlotnick et al., 2019). In female dogs, juvenile and prepubertal gonadectomy may be the cause for a recessed vulva since due to the lack of sexual steroid hormones, the secondary sexual organs remain in a juvenile status. In some cases, this facilitates development of perivulvar dermatitis and recurring infections of the urogenital tract (Jagoe & Serpell, 1988; Joshua, 1965; Salmeri et al. 1991a, 1991b), even though the prevalence of lower urinary tract disease or perivulvar dermatitis was not different in dogs with or without recessed vulva in one study (Palermi et al., 2021). Many cases require operative measures (episioplasty). Furthermore, the occurrence of persistent juvenile vaginitis may be triggered. Juvenile vaginitis is an inflammatory condition that frequently concerns female dogs before their first oestrus. The vaginal epithelium only consists of very few layers of cells rendering the vagina susceptible for infections. The vaginitis resolves spontaneously with onset of puberty. However, when a prepubertal, female dog with juvenile vaginitis is gonadectomised, the condition may persist; even though spontaneous remissions are described (Johnston, Kustritz, & Olson, 2001b; Olson et al., 1986). Gonadectomy at <3 months of age may increase the risk for USMI (Pegram et al., 2019; Spain et al., 2004a) although the evidence in favour of such results has been defined as weak (Beauvais et al., 2012b). In one study, an increased hazard ratio of USMI with higher adult bodyweight and earlier gonadectomy was found, which was significant at an adult bodyweight of ≥25 kg (Byron et al., 2010).

Paediatric gonadectomy may be useful to prevent unwanted pregnancies in shelter and stray dogs and to increase adoption rate; however, in some individuals and especially in large breeds, alternatives should be considered. In owned pets, its use should be carefully evaluated when discussing this option with the owner considering breed, future living conditions and use of the dog.

## 5.2 | Male dogs

### 5.2.1 | Tumours

**5.2.1.1 | Prostate gland tumours:** The incidence of prostate gland neoplasia in the male dog population is reportedly low at <1% (Bell et al., 1991; Schrank & Romagnoli, 2020; Weaver, 1981). Although the type of tumour is sometimes not identified (LeRoy & Lech, 2004; Sorenmo et al., 2003), most cases are malignant adenocarcinomas, TCC or rarely lymphomas (Smith, 2008). According to literature they are more frequently diagnosed in gonadectomised than in intact dogs (Cavalca et al., 2022; Sorenmo et al., 2003; Teske et al., 2002) which has led some authors to state that androgens do not play an important role in pathogenesis

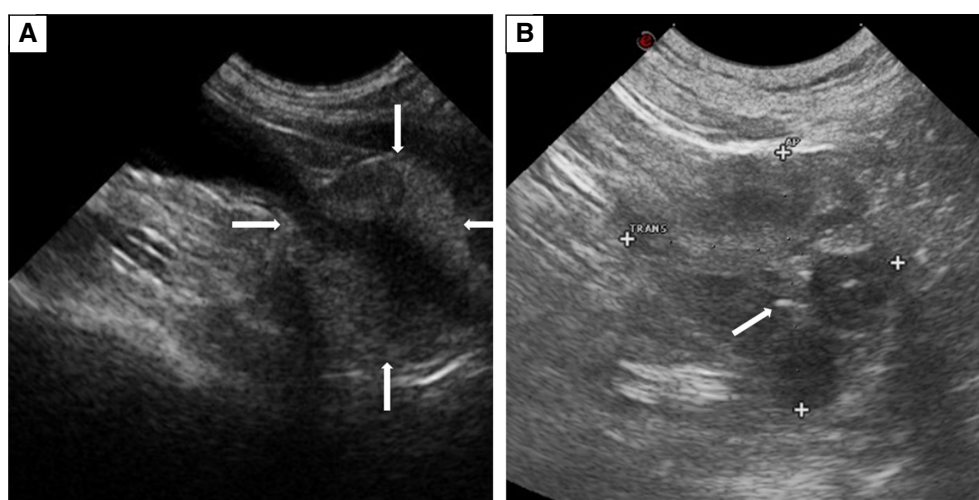


(Cavalca et al., 2022). Age is an important factor as canine prostatic tumours are mainly diagnosed at >8 years (Bell et al., 1991; Hornbuckle et al., 1978; Polisca et al., 2016). Medium sized to large breeds were reported to be more frequently concerned than smaller or toy breeds (Teske et al., 2002; Weaver, 1981). A breed predisposition is hypothesised; a higher risk was reported for Shetland sheepdog, Scottish terrier, Bouvier des Flandres, Doberman and mongrels (Bryan et al., 2007; Krawiec & Heflin, 1992; Teske et al., 2002). Chronic inflammations may trigger the change in precancerous cells causing DNA and epigenetic damages (Schlein & Thamm, 2022). Canine prostates affected with neoplasia very frequently feature areas of BPH, cysts with clear fluid or pus and lymphoplasmacytic inflammation (Fig 84) (Barsanti & Finco, 1986). The growth is aggressive, and the incidence of metastases is 16 to 80%, dependent on age of the dog (Bell et al., 1991; Cornell et al., 2000). Metastases occur in the lumbar vertebral bodies and pelvic bones, bladder, lungs, long bones, scapula, ribs and digits; they are frequently already present at the time of diagnosis (Johnston et al. 2001c).

The discussion concerning the effect of gonadectomy and the role of androgen stimulation *versus* androgen deprivation in the development of canine prostatic neoplasia is controversial. Canine prostatic neoplasms are thought to derive from prostatic ductal cells and have classically been defined as androgen-independent. However, this is probably an oversimplification of a fairly complex relationship between prostatic (ductal, epithelial and neuroendocrine) cells and androgens.

Due to the stimulus provided by androgens at puberty, canine prostatic epithelial ductal cells start differentiating into epithelial secretory cells, thereby forming the secretory acinar tissue. The androgen-independent neuroendocrine (NE) cells form a minor part of the total epithelial population but are widely distributed in all regions of the (human and) canine prostate showing irregular neurite-like processes which penetrate the prostatic parenchyma extending towards the lumen (Hanyu et al., 1987). Human prostatic NE cells secrete a variety of different growth stimulating substances, among others vascular endothelial growth factor, gastrin-releasing peptide, hormones and amines (such as serotonin). Because of their secretory products, human NE cells are involved in the homeostatic regulation of prostatic secretory process as well as in prostatic growth and differentiation (Di Sant'Agnese, 1992). Human NE cells have a potent stimulatory action on cultured human prostate cancer cells, are widely represented in human neoplastic prostate as well as in metastases of prostatic neoplasia (Ahlgren et al., 2000; Di Sant'Agnese, 1998; Krijnen et al., 1997) and therefore are thought to contribute to prostate cancer progression following androgen deprivation due to their increase in numbers in men treated with androgen ablative therapy before prostatectomy (Ahlgren et al., 2000; Cox et al., 1999). Canine prostatic NE cells show morphological resemblance and a similar pattern of distribution within the prostatic acini as human NE cells (Ismail et al., 2002).

The differentiation of ductal into secretory cells as well as further development and function of prostatic secretory tissue is under the control of androgens, which in the mice prostate are thought to have a protective role on prostatic epithelial cells by maintaining their homeostasis (Mirosevich et al., 1999). In dogs, such stimulatory, protective and homeostasis-inducing role of androgens on prostatic secretory tissue is indirectly confirmed by the observation that gonadectomy causes atresia of prostatic acinar cells but not of prostatic ducts and stromal compartment (Shidaifat et al., 2004) or prostatic NE cells (Ismail et al., 2002). Following orchiectomy; (1) canine prostatic ductal cells stop differentiating into epithelial cells but survive increase in number and diffuse around the atrophic prostatic acini and (2) stromal cells increase their mass and vimentin (a marker of poorly differentiated carcinoma) is expressed all over the fibromuscular compartment (Shidaifat et al., 2004). The prostatic ductal epithelium is currently regarded as



**FIG 84. Prostate gland tumour, sonographical image.** Normal prostate gland (arrows) with urethra in the middle; note the regular structure and hypo echogenicity. (B) Prostate gland carcinoma (crosses) with mineralisation (arrow) and intraprostatic cysts in a 14-year-old Labrador. The gland was not enlarged (2.9×3 cm). Note the highly irregular structure; the mineralisation can be a sign of cancer. The tentative diagnosis was confirmed cytologically

one of the most likely sources of canine prostatic neoplasia. Also, canine prostatic NE cells show a sharp increase following castration (Ismail et al., 2002).

Because of the key role of androgens in stimulating differentiation of canine prostatic ductal into epithelial cells, the prostatic acinar tissue of the dog has always been considered as an androgen-dependent tissue while the ductal system and stromal tissue have been considered as androgen-independent. The definition of “androgen independence” has led many authors to conclude that androgens do not play any role in the development of prostatic neoplasia, a belief which has been supported by (1) the increased incidence of prostate cancer in gonadectomised dogs, (2) the lack of expression of androgen receptors by canine prostatic carcinomas (Cavalca et al., 2022), (3) the fact that proliferative inflammatory atrophy-type lesions of the canine prostate may lead to prostatic cancer development in the absence of androgens (Cavalca et al., 2022). However, the fact that the canine prostatic ductal epithelium and prostatic stroma show marked changes following castration is an indirect proof that such tissues are somehow influenced by androgen secretion; therefore, rather than androgen-independent these cells should be probably regarded as “androgen-sensitive” (Sorenmo et al., 2003). The following mechanisms may be suggested to further characterise the concept of “androgen sensitivity” hypothesising a lower risk of intact dogs in developing prostatic cancer:

1. In young (24 to 30-month-old) beagle dogs, orchiectomy causes death of prostatic epithelial cells while basal (ductal) cells survive but lose their ability to differentiate into secretory epithelial cells and tend to form a continuous layer around the atrophic prostatic acini (Shidaifat et al., 2004). As early as 30 days after castration, the prostatic stromal component of the dogs of this study shifted from primarily actin-positive smooth muscle cells to vimentin-positive mesenchymal cells (Shidaifat et al., 2004). Vimentin is a marker of poorly differentiated prostatic carcinomas (Lang et al., 2002; Tuxhorn et al., 2002).
2. Canine prostatic carcinoma originates from prostatic ductal cells (Leav et al., 2001); gonadectomised dogs have a higher population of ductal cells in their prostates compared to intact dogs (Lai et al., 2008).
3. Orchiectomy increases expression of endothelin receptors by the canine prostate (Padley et al., 2002). Endothelins are growth factors produced by prostatic epithelial cells involved in the development of osteoblastic metastases in prostate cancer through a paracrine mechanism. Their increase following gonadectomy suggests that endothelins may stimulate growth of prostatic carcinoma cells through a paracrine mechanism.
4. Endothelin receptor antagonists reduce the capacity of normal canine prostates to stimulate osteoblasts and their clinical use has been suggested for the control of bone metastases in prostatic cancer patients (LeRoy et al., 2004).
5. Canine NE cells increase in numbers and actively differentiate following castration: such growth and differentiation in castrated dogs is inhibited by treatment with androgens (Ismail et al., 2002).
6. Androgen ablation in dogs causes the development of conditions (atresia of prostatic epithelial cells, development and dedifferentiation of ductal cells, development and differentiation of NE cells) which closely resemble what happens in men when the prostate tumour starts growing again following androgen ablation therapy performed before prostatic surgery. Therefore, androgens may have a protective role on the canine prostatic parenchyma as they exert an antiproliferative effect on ductal and neuroendocrine cells (Ismail et al., 2002; LeRoy & Northrup, 2009; Sorenmo et al., 2003).

Histological changes on prostatic secretory epithelium following treatment with GnRH agonists appear to be like those occurring following gonadectomy. Application of a 6 mg implant of the GnRH-agonist deslorelin caused complete atrophy of the prostatic tubular glandular structures; the tubules were still lined with non-secretory epithelium by day 41 after implant insertion. By day 100 after insertion, the tissue showed complete atrophy of the glandular epithelium and an increase in stromal connective tissue (Junaidi et al. 2009b). There is currently no information on the effect of chronic GnRH agonists administration on the canine prostate; therefore, no conclusion on the relation between androgen deprivation after hormonal down-regulation and the occurrence of prostate cancer is possible at present.

All above considerations make the decision as to whether or not to advise routine orchiectomy or long-term hormonal down-regulation (thereby allowing establishment of an androgen deprived environment) for healthy dogs very difficult. Because of failure of most previous studies in reporting intervals between orchiectomy and diagnosis of prostatic carcinoma, a clear connection between orchiectomy and development of prostatic neoplasia within a reasonably short amount of time (weeks or months) cannot be established (Schrank & Romagnoli, 2020). Canine prostatic adenocarcinoma is a disease of elderly dogs and it is possible that castration of adult to elderly dogs may increase the risk of its development. However, confirmation of this theory requires further epidemiological investigations to study potential breed related differences as well as the role of age at castration and the interval between castration and tumour development. Nevertheless, a role for gonadectomy in increasing the risk of developing the condition cannot be ruled in or out.

When advising clients, the very low (<1%) risk of developing a prostatic tumour should be weighed against the risk of developing large prostatic cysts or prostatic abscesses and their inherently high surgical risk if the dog is left intact. The need for a regular complete andrological exam (which should include rectal palpation, prostatic ultrasound and assay of serum CPSE) to be repeated at least once/year from when the dog has reached 40% of his life expectancy should be stressed with clients opting to keep their male dogs intact (Mantziaras et al., 2017).

**5.2.1.2 | Mast cell tumours:** For details on MCTs and the relation between gonadectomy and tumour development see also Chapter 5.1.1.1. As stated there, a relationship between sex and tumour occurrence has been reported with gonadectomised males having a lower risk of developing a MCT than gonadectomised females (Grüntzig et al., 2016; Torres de la Riva et al., 2013; White et al., 2011). In male dogs, the incidence of MCT has not been reported to increase when gonadectomy is performed at >12 months *versus* at <12 months unlike what happens in female dogs (Torres de la Riva et al., 2013). In a recent study, the expression of LH receptors (LHR) was investigated in MCT cell specimens of three male dogs; all three MCT specimens (all Patnaik grade II and Kiupel low grade) expressed LHR and the expression was higher in MCT from gonadectomised dogs than in those of intact dogs; however, the effect of LHR signalling on MCT development in male dogs remains to be clarified (Kutzler et al., 2022). All these facts point towards a multifactorial pathogenesis and an increased risk for older and heavier dogs, females and specific breeds, with deprivation of sex hormones being another factor.

The possibility of a MCT to develop after gonadectomy should be mentioned, when possible, side effects of gonadectomy are explained to owners of dogs at risk.

**5.2.1.3 | Transitional cell carcinomas:** For details on TCC see chapter 5.1.1.2. Gonadectomy in male and female dogs increases risk of development of tumours like TCC (Norris et al., 1992). Male dogs seem to have a lower risk than intact female dogs to develop a TCC following gonadectomy, as in one study the female: male ratio was 1.7:1 (Knapp et al., 2000; Norris et al., 1992). However, more research is needed to clarify the impact of sex on development of TCC in gonadectomised dogs.

The aetiology of TCC is probably multifactorial; however, the possibility of a TCC to develop after gonadectomy should be mentioned when side effects of gonadectomy are explained to owners of male dogs.

**5.2.1.4 | Osteosarcomas:** For more details on osteosarcomas, see chapter 5.1.1.3. Male dogs are more frequently concerned than females (Egenvall et al., 2007; Zink et al., 2023). The risk of osteosarcoma seems to increase with age, breed weight and height, and bodyweight (Ru et al., 1998; Zink et al., 2023). An increased risk for osteosarcoma following gonadectomy has been hypothesised in several studies (Cooley et al., 2002; Grüntzig et al., 2015, 2016; Hoffman et al., 2013; Ru et al., 1998). The relative risk to develop an osteosarcoma was described to be twofold among gonadectomised in comparison to intact dogs (Ru et al., 1998). In Rottweilers, age at gonadectomy was shown to exert an effect on the incidence of osteosarcoma as the shortest lifetime exposure to reproductive steroid hormones coincided with the highest incidence of osteosarcoma (Cooley et al., 2002). The effect of age at the time of gonadectomy has not been sufficiently investigated in other breeds but was not related to cancer incidence in one retrospective study with both pure breeds and mongrels (Zink et al., 2023).

The possibility of an osteosarcoma to develop after gonadectomy should be mentioned, when possible side effects of gonadectomy are explained to dog owners.

**5.2.1.5 | Lymphomas:** As mentioned in chapter 5.1.1.4., lymphomas are tumours of the lymphatic system which include both blood and lymph tumours. The reported incidence in dogs is variable between studies as well as among breeds and ranges between 0.02 and 0.1% (Dobson et al., 2002; Dorn et al., 1967). A breed disposition is supposed (Bennett et al., 2018; Cheng et al., 2019; Hart et al., 2014, 2026). The role of sexual status is unclear as both sexes are concerned (Zink et al., 2014); in one study, 10% of male golden retrievers gonadectomised at <12 months of age were diagnosed with lymphosarcoma, which was three times more than in intact males (Torres de la Riva et al., 2013). A negative impact of an earlier age at gonadectomy was also supposed by others (Hart et al., 2014, 2020). The impact of the long-lasting increase in serum-LH concentration after gonadectomy is currently under investigation (Ettinger et al., 2019; Kutzler, 2020a, 2023).

The pathogenesis is probably multifactorial but the possibility of a lymphoma to develop after gonadectomy should be mentioned, when possible side effects of gonadectomy are explained to owners of male dog.

**5.2.1.6 | Haemangiosarcomas:** For details on haemangiosarcomas see also Chapter 5.1.1.5. The impact of sexual status on development of hemangiosarcoma in gonadectomised male dogs is not yet clarified; in some studies, male dogs were more frequently affected than females (Brown et al., 1985; Gamlem et al., 2008; Ware & Hopper, 1999), while others found no sex predilection (Schultheiss, 2004).

In one study, gonadectomised male Magyar vizslas did not show any increase in relative risk to develop haemangiosarcoma in comparison to intact male dogs, unlike what was observed for female dogs of the same breed (Zink et al., 2014). But in another study, orchiectomised dogs were reported to bear a relative risk of 1.55 compared to intact males (Ware & Hopper, 1999). One group of researchers found expression of LH receptors in commercially available canine splenic haemangiosarcoma cell lines and, after stimulation with LH, the proliferation rate increased significantly in two of three cell lines. Thus, the increase in LH after gonadectomy might contribute to the pathogenesis of canine haemangiosarcomas in both sexes (Zwida & Kutzler, 2022). The age at castration and the role of duration of gonadal hormone exposure on the development of haemangiosarcomas in male and female dogs has not been sufficiently investigated (Torres de la Riva et al., 2013). In one study, the impact of age on the risk of cancer was found to be significantly larger than the reproductive status (Kent et al., 2018).



Haemangiosarcoma development can be triggered by gonadectomy; however, the pathogenesis of this condition is probably multifactorial and as such the role of gonadectomy in male dogs might be present but marginal. This should be explained to owners of male dogs.

### 5.2.2 | Urethral sphincter mechanism incompetence (USMI)

While in female dogs, gonadectomy results in urinary incontinence in 5 to 20% any time after surgery (Reichler & Hubler, 2014; Thrusfield et al., 1998), the reported incidence of this condition among 109,428 male dogs was 0.94% in one study (Hall et al., 2019). Such a low incidence has made it so far impossible to elucidate the pathogenesis of urinary incontinence in male dogs. Short urethral length, caudal bladder position and orchiectomy have been proposed as risk factors (Aaron et al., 1996; Coit et al., 2008; Power et al., 1998). Testosterone administration was successful in one case report (Barsanti et al., 1981) but was only successful in 3/8 cases in a subsequent study (Palerme et al., 2017). A large epidemiological study reported that the relative risk of incontinence in male dogs increased with age but there was no relation with gonadectomy or increasing BW, unlike in female dogs. Some breeds were at higher risk, which might be selection biased and must be further investigated (Hall et al., 2019).

There is no evidence that gonadectomy increases the risk for urinary incontinence in male dogs. However, since the administration of testosterone or testosterone products has proven successful in a few isolated cases of male dogs developing incontinence following gonadectomy, the possibility that this condition may develop in a few isolated dogs following gonadectomy cannot be ruled out. Therefore, although very low such risk should be explained to clients before gonadectomy of their male dogs is considered.

### 5.2.3 | Orthopaedic diseases

As discussed in chapter 5.1.3., the impact of gonadectomy on the occurrence of orthopaedic problems is unclear. Odds of an orthopaedic problem increased with gonadectomy in one retrospective study, but the genesis is multifactorial (Zink et al., 2023). Excessive weight gain (see next section) as well as ageing have a negative effect on the joints, irrespective of sexual status (Duval et al., 1999). Weight control is therefore an important prophylactic measure. In one retrospective study, a 615,999 data set was evaluated to determine the impact of gonadectomy on HD and CCL tear or rupture in male dogs. The relative risk to develop these diseases was significantly higher in gonadectomised than intact males (Witsberger et al., 2008). In case of rupture of the CCL, other causes play a role such as an increased tibial plateau slope (Aertsens et al., 2015; Su et al., 2015) or early degenerative changes in the ligament due to a proximodistal position of the tibial tuberosity, bodyweight or obesity. However, a higher incidence of CCL rupture was reported in gonadectomised when compared to intact dogs (Canapp, 2007; Duerr et al., 2007; Duval et al., 1999; Slauterbeck et al., 2004; Whitehair et al., 1993; Witsberger et al., 2008). In Dachshunds, the risk of intervertebral disc disease was increased when gonadectomised under 12 months of age (Dorn & Seath, 2018).

The age at gonadectomy clearly has an impact. In one study comprising 245 service dog candidates, those gonadectomised at <7 months of age had more than twice the risk to develop orthopaedic problems than dogs gonadectomised at an older age, irrespective of sex; however, there was an additional breed effect with Labradors being more frequently affected than golden retrievers (Zlotnick et al., 2019). The negative effect of gonadectomy at <6 months of age or gonadectomy at <12 months of age on joint health has repeatedly been reported in large populations of dogs of certain breeds (Hart et al., 2014; Spain et al., 2004a; Torres de la Riva et al., 2013; van Hagen et al., 2005). Gonadectomy in male golden retrievers younger than 6 months was reported to coincide with a five times higher rate of HD and CCL rupture than gonadectomy after the age of 2 years or in comparison to intact dogs (Hart et al., 2014). In male Labradors, this concerned mainly CCL rupture and elbow dysplasia (ED), the prevalence being significantly higher after castration at <6 months of age than after the age of 2 years or in comparison to intact dogs (Hart et al., 2014). The risk to develop at least one of these diseases was significantly higher in male German shepherd dogs, in which gonadectomy was performed at <6 months of age or at >12 months than in intact males (Hart et al., 2014, 2016; Torres de la Riva et al., 2013). In another population of golden retrievers, the incidence of dogs that developed HD when castrated at <12 months of age was double the incidence in intact dogs and CCL rupture was only diagnosed in male dogs neutered at <12 months (Torres de la Riva et al., 2013). Because of the predominance of certain breeds in these studies more research is needed to clarify whether a breed effect exists. However, a higher incidence of orthopaedic diseases was reported for gonadectomised than intact dogs (Canapp, 2007; Duerr et al., 2007; Duval et al., 1999; Slauterbeck et al., 2004; Whitehair et al., 1993; Witsberger et al., 2008). An increased expression of LH receptors was detected in the cranial cruciate and round ligament as well as structural support tissue of the hip and femorotibial joint of dogs after gonadectomy; the impact of this finding on the pathogenesis of CCL rupture and other orthopaedic diseases is currently under investigation (Kiefel & Kutzler, 2020; Kutzler, 2023; Kutzler et al., 2022).

Occurrence of orthopaedic problems is a possible side effect of gonadectomy, especially in case of gonadectomy <6 months of age and especially in certain breeds particularly of medium to large bodyweight. As in female dogs, recommendations pertaining to orthopaedic health and gonadectomy should be made on an individual basis, considering the breed, age and bodyweight of the dog. However, in small breed dogs (dachshunds), intervertebral disc disease is also recognised as being at higher risk in gonadectomised dogs (Dorn & Seath, 2018).

## 5.2.4 | Metabolic and endocrine disorders

As described in chapter 5.1.4., gonadectomised dogs have a reduced metabolic rate and satiety, independent from sex (Bermingham et al., 2014; Spain et al., 2004a). Since many owners do not consider this and do not adapt the feeding or physical activity of their dogs, many gonadectomised dogs increase their bodyweight (BW) and often develop overweight and obesity which in turn predisposes them to many diseases which may have an impact on longevity (Kustritz, 2007; Lefebvre et al., 2013; Lund et al., 2006; Pegram et al., 2021; Simpson et al., 2019). Gonadectomised male dogs were shown to have an increased hazard ratio of obesity (2.62) in comparison to intact male dogs (Benka et al., 2023). Breed size is another influencing factor for obesity as small and toy breeds <10 kg were shown to have a higher hazard ratio than larger dogs (Bermingham et al., 2014; Banfield Pet Hospital Report, 2020). Obesity predisposes dogs to many diseases, behavioural abnormalities and reduced longevity (German, 2006; German et al., 2017; Lund et al., 2006; Yam et al., 2016). Even though, in male and female dogs, obesity was shown to induce insulin-resistance leading to hyperinsulinemia and reduced glucose tolerance (Veiga et al., 2008), it does not cause diabetes mellitus (Guptill et al., 2003; Rand et al., 2004). The incidence of obesity increased with age (Banfield Pet Hospital Report, 2020; Guptill et al., 2003; Rand et al., 2004). Thus, as described for female dogs, the effect of gonadectomy on obesity is further influenced by factors like feeding, physical activity, sex, age and breed size (Benka et al., 2023; Banfield Pet Hospital Report, 2020) and can be reversible. The impact of age at gonadectomy on the risk of developing metabolic disease requires further investigation; in one study, the prevalence of obesity was decreased in male and female dogs with gonadectomy <5.5 months in comparison to gonadectomy between 5.5 and 12 months (Spain et al., 2004a). In another large-scale retrospective study, male dogs gonadectomised at 1 year of age had a significantly lower relative risk to develop overweight and obesity than those castrated at later ages; the hazard ratio increased until 3 to 4 years of age at gonadectomy and then declined (Benka et al., 2023). More research is needed to establish if and at what age gonadectomy increases the risk for metabolic and endocrine disorders in male dogs.

Gonadectomy is also a reported risk factor for both hypothyroidism and hyperadrenocorticism (Belanger et al., 2017; Dixon & Mooney, 1999; Dixon et al., 1999; Hoffman et al., 2018; Panciera, 1994). Canine hypothyroidism develops most commonly as a primary condition and is either idiopathic or caused by an autoimmune disease with probably underlying genetic and environmental factors (Bianchi et al., 2015, 2020; Kemppainen & Clark, 1994). A breed predisposition is described for Dobermans and golden retriever (Panciera, 1994). However, there is some evidence that gonadectomy increases the risk for hypothyroidism (Dixon & Mooney, 1999; Dixon et al., 1999; Panciera, 1994) as the relative risk to develop hypothyroidism was found to be higher in gonadectomised than in intact dogs (Milne & Hayes, 1981; Panciera, 1994). A retrospective evaluation of a 90,090 patient data sets revealed a higher incidence and risk of hypothyroidism in gonadectomised than in intact male and female dogs with gonadectomised females being at highest risk. In both sexes, the disease was diagnosed on average 20 months after gonadectomy. Unfortunately, the impact of age at gonadectomy could not be calculated from the available data (Sundburg et al., 2016). This study is interesting since all diagnoses were thoroughly done, date of disease diagnosis and age of neuter were recorded for dogs gonadectomised at the clinic. Furthermore, in gonadectomised dogs, the concentrations of thyroxine were significantly lower than in intact dogs (Krzyżewska-Młodawska et al., 2014). Recently, expression of LH receptors was detected in canine thyroid cells; the increase in serum-LH concentration following gonadectomy as a contributing factor is therefore currently under investigation (Zwida & Kutzler, 2019).

Canine hyperadrenocorticism (Cushing's Syndrome) is a disease coinciding with chronic elevated cortisol levels (Hoffman et al., 2018). The cause can be either an adrenocorticotrophic hormone (ACTH) secreting pituitary tumour, or a cortisol secreting tumour in the adrenal cortex. A weak but significant relationship between gonadectomy and hyperadrenocorticism was reported with a higher prevalence in gonadectomised dogs (Hoffman et al., 2018); however, in an earlier study considering 210,824 dogs with hyperadrenocorticism, no evidence could be proven when data were controlled for other risk factors like age (O'Neill et al., 2016).

Hypoadrenocorticism (Addison disease) is mostly immune-mediated with some breeds like the Nova scotia duck tolling retriever, Standard poodle, Bearded collie, Portuguese water dog, Great Dane, West highland white terrier, Saint Bernard, Wheaten terrier, Leonberger and Rottweiler bearing a genetic predisposition (Famula et al., 2003; Hughes et al., 2007; Oberbauer et al., 2002; Peterson et al., 1996; Thompson et al., 2007). Only one retrospective study reported that gonadectomised dogs bear a greater risk to develop the disease than intact dogs and a protective effect of testosterone is hypothesised in men and male dogs (Sundburg et al., 2016). Importantly, a recent study found a strong association between increasing age and the occurrence of endocrine disorders (Zink et al., 2023).

Gonadectomy may trigger the development of metabolic and endocrine diseases; however, it should be pointed out that each disease has probably a multifactorial origin.

## 5.2.5 | Immune disorders

As discussed in Chapter 5.1.5., the impact of gonadectomy on the immune system of male and female dogs is not clear. Even though sex steroid hormone receptors can be found in organs of the immune system (Farris & Benjamin, 1993; Staples et al., 1999), some authors doubt that gonadectomy increases the risk of immune disorders (Urfer et al., 2019). Nevertheless, an effect of gonadectomy cannot be excluded, which seems to concern both sexes although for some disorders female dogs appear to be more frequently

affected than male dogs. In a large-scale retrospective study, gonadectomised dogs had a greater incidence and a greater risk to develop some autoimmune diseases than intact dogs (Sundburg et al., 2016); this concerned atopic dermatitis, autoimmune haemolytic anaemia, hypoadrenocorticism, inflammatory bowel disease, immune-mediated thrombocytopenia and hypothyroidism. Only in case of hypoadrenocorticism, a higher incidence was shown in gonadectomised males than gonadectomised females. Average age at gonadectomy was  $32.3 \pm 0.7$  months in males and the diagnosis of disease was made >20 months thereafter (Sundburg et al., 2016). In another retrospective study including 151 dogs with immune-mediated haemolytic anaemia (IMHA), significantly more gonadectomised dogs (129/151, 85%) were present in the IMHA group than in the control group without IMHA (10,038/13266, 76%) and significantly less affected male dogs were intact (12/151 dogs, 8%) compared to the control population (1907/13266, 14%; Weinkle et al., 2005).

Autoimmune and immune-mediated conditions likely have a multifactorial origin. One of these triggering factors could be gonadectomy. However, there is currently only limited evidence that gonadectomy may be a risk factor for the development of hypoadrenocorticism and immune-mediated haemolytic anaemia in male dogs. More studies are needed to investigate the role of gonadectomy on the development of immune disorders in male dogs.

### 5.2.6 | Behavioural concerns

As discussed for female dogs in chapter 5.1.6, the impact of gonadectomy on behaviour is a complex issue. The effects of gonadectomy on dog's behaviour remains a subject of debate with conflicting evidence which may leave both veterinarians and owners confused (Palestrini et al., 2021). Behavioural conditions have multiple causes, and they are rarely, if ever, caused by gonadectomy only. The decision by owners to gonadectomise male dogs in particular is strongly influenced by the erroneous perceived expectation of improvement or prevention of unwanted aggression (offending biting towards dogs and defensive bites towards humans) after surgery (Da Costa et al., 2022; Downes et al., 2015; Notari et al., 2020). Also, despite evidence to the contrary, there is a commonly held erroneous notion that there is a consistent association between levels of serum testosterone concentrations and aggressive behaviour of all types in dogs (Garde et al., 2016). Studies retrospectively investigating the effect of gonadectomy on behaviour are often confounded since important factors like age at gonadectomy, reasons for gonadectomy, environmental factors, training and history of the individual dogs are sometimes not considered, and a control group is often missing (Arlt et al., 2017). Furthermore, the classification of aggression varies in the different studies making direct comparison between studies impossible. It is not known at what age the young dog's personality stabilises (Starling et al., 2013), but previous studies suggest behaviour in dogs under 9 months of age is not strongly indicative of adult dog behaviour in most cases (Goddard & Beilharz, 1986). Therefore, it is plausible that part of behaviour changes of dogs that were gonadectomised at a young age can be attributed to increase in age rather than gonadectomy only. Furthermore, in many cases, the term behavioural abnormality is not properly defined. Problematic behaviour, like aggression and anxiety- or fear-based behaviours, must be differentiated from nuisance behaviours such as urine marking and mounting behaviour which are normal behaviours but unwanted by dog owners (Zink et al., 2023). In addition, some behaviours are considered as undesired during specialised training for working and service dogs (Zlotnick et al., 2019). The most important question is in how many cases detrimental effects such as an increase in problematic behaviour occurred after gonadectomy and whether age at castration or individual genetics make a difference. Table 6 provides a literature review on changes in behaviour after gonadectomy in male dogs (see Chapter 5.2.6.)

In one retrospective study, male English springer spaniels aggressive to their owners in different contexts were more frequently male than female and neutered than intact and in addition in many of the cases the dogs had been gonadectomised due to a previous history of biting (Reisner et al., 2005). More complex pedigree analyses and controlled studies are required to provide evidence of the causal relationship between aggression and gonadectomy in this breed. Given that dogs have been bred for different tasks and display different breed-specific tendencies, a direction for future research would be to determine whether and how different breeds might respond differently to gonadectomy (Farhoody et al., 2018). Gonadectomy was reported to increase dominance aggression (Voith & Borchelt, 1982) and owner-directed aggression (Bálint et al., 2017). However, noteworthy is one study that comprehensively shows the complexity of this theme using a very large number of cases (15,370). Using the Canine Behaviour Assessment Research Questionnaire (C-BARQ), some authors detected no relation between gonadectomy, age at gonadectomy (6 months or less, 7 to 12 months, 11 to 18 months and >18 months) and aggression towards familiar people or dogs. However, gonadectomised dogs had higher odds of developing aggression towards strangers than intact dogs, but this only concerned the group gonadectomised at 7 to 12 months of age and authors rated the increase in aggression as minimal (Farhoody et al., 2018). This was confirmed by a recent questionnaire-based study; according to calculated odds ratios, the probability that orchietomised males will have an unwanted behaviour (aggression, anxiety-based behaviour, extreme fears) is higher in comparison to intact males, intact females, gonadectomised females or hysterectomised females (Zink et al., 2023). But the odds decreased with increasing time the gonads were present, probably pointing towards an advantage of gonadectomy at later ages (Zink et al., 2023).

Some studies agree on the presence of a causal relationship between prepubertal gonadectomy and anxiety/lack of confidence or an increase in behavioural problems (Brinkmann, 2015; McGreevy et al., 2018; Spain et al., 2004a; Zink et al., 2014). As



already mentioned in Chapter 5.1.6., this may be related to the development of the central nervous system during puberty; brain development is steroid hormone dependent and, during adolescence, a significant increase in nerve cell junctions takes place. The rising steroid hormone levels influence among others neurotransmitters and the benzodiazepine-GABA-receptor complex (Handa & Weiser, 2014; Sisk & Zehr, 2005). Prepubertal gonadectomy might negatively influence learning procedures (Brinkmann, 2015). Such a relationship is further confirmed by a study on 245 service dog candidates; significantly more male and female dogs gonadectomised at <7 months were dismissed for behaviour problems than in the group of dogs gonadectomised at 7 to 11 months (Zlotnick et al., 2019). However, this study dealt with all behavioural problems preventing the dog from becoming a reliable service dog, which included several factors like poor focus, unpredictability, inconsistency, lack of motivation, poor recall and further factors (Zlotnick et al., 2019). In the latter study, there was a breed effect; golden retrievers and Labradors were less likely to be dismissed from the training programme than other breeds, probably because behaviour is influenced by a multitude of factors. For an objective view on the impact of gonadectomy on unwanted behaviour, a preliminary assessment of aggressive behaviour and all its potential causes and confounding factors should be performed by a behavioural expert (Bálint et al., 2017).

There is no report about an increase in male aggression after application of long-lasting GnRH-agonists except for anecdotal observations of short-lasting worsening of some behavioural traits during the flare-up period in unstable dogs. In one study, an increase in anxiety and insecurity was observed by owners in 3/53 dogs (Goericke-Pesch et al. 2010b); however, this was not confirmed by a subsequent study (de Gier et al., 2012). Further studies with larger numbers and in a diversity of breeds are required to establish whether GnRH-agonists have advantages over gonadectomy with respect to display of unwanted behaviour following suppression of gonadotrophs or gonadectomy in male dogs, respectively.

Unwanted behaviour should be assessed by a veterinary behavioural expert before irreversible gonadectomy is recommended. Corrective behavioural training of aggressive dogs, and owner education and training is fundamental to responsible dog ownership. The decision on whether or not a dog should be gonadectomised and at which age this should be performed, must be based on an individual analysis which should consider also the intended use of the dog (Zlotnick et al., 2019). Finally, while the literature may help in predicting the possible effects of gonadectomy on behavioural aspects of most of the animals within a population of dogs and cats, we currently have insufficient understanding and knowledge to accurately predict how gonadectomy would affect the behaviour of an individual animal belonging to either a specific breed or mixed breed.

## 5.2.7 | Paediatric gonadectomy

As described in Chapter 5.1.7. for female dogs, paediatric gonadectomy of male puppies at the age of 6 to 16 weeks (juvenile, paediatric or early spay-neuter), may predispose to infections, if they have a bad constitution and insufficient immunisation (Cardwell, 1993; Howe, 1997; Howe et al. 2000, 2001). During the operation, the male puppies are at high risk for injuries, because the tissue is very fragile. Gonadectomy before puberty delays growth plate closure of the radius and ulna by four months, probably contributing to the high occurrence rate for orthopaedic diseases in dogs gonadectomised at <12 months of age (Hart et al., 2014, 2016, 2020; May, 1998; Spain et al., 2004a; Torres de la Riva et al., 2013; van Hagen et al., 2005; Zlotnick et al., 2019). In addition, gonadectomy of juvenile puppies causes hypoplasia of the penis and prepuce, even though no negative consequences are reported (Olson et al., 2001; Salmeri et al. 1991a).

Paediatric gonadectomy may be useful to prevent unwanted pregnancies in shelter and stray dogs and to increase adoption rate; however, in some individuals and especially in large breeds, alternatives should be considered. In owned pets, its use should be carefully evaluated when discussing this option with the owner considering breed, future living conditions and use of the dog.

## 5.3 | Cats

### 5.3.1 | Effects on metabolism

Gonadectomy increases the risk of obesity in cats and this is especially true for male cats. Obesity in gonadectomised cats is due to an increase in appetite and a decrease in metabolic rate and energy expenditure (Belsito et al., 2009; Chiang et al., 2022; Iwazaki et al., 2022; Martin et al., 2001; Panciera et al., 1990; Scarlett et al., 1994). Obese cats have an increased risk to develop insulin dependent type-2 diabetes mellitus which is characterised by insulin and leptin resistance (Feldhahn et al., 1999; Niaz et al., 2018) with neutered male cats bearing a particularly high risk (Appleton et al., 2001). In general, obese male cats have lower insulin sensitivity and a higher insulin concentration than females, explaining the higher incidence of diabetes in orchietomised obese male cats (Appleton et al., 2001; Martin et al., 2001). However, an increase in exercise and reduced food uptake can be an efficient preventive measure against obesity and diabetes mellitus in both male and female cats (Belsito et al., 2009; Nguyen et al., 2004). Obesity in gonadectomised cats may furthermore be prevented by feeding a low-fat diet (Backus et al., 2007; Kanchuk et al., 2002; Nguyen et al., 2004).

Gonadectomy increases the risk for obesity and diabetes mellitus in male cats, but this can be prevented by physical activity and the use of an appropriate low-fat diet.

### 5.3.2 | Orthopaedic diseases

In one study, the final radial length was increased in all gonadectomised cats of both sexes compared to intact controls; the age at gonadectomy (7 weeks compared to 7 months) had no effect on adult radial length measured at 24 months. No negative effect on health was observed (Root et al., 1997). These results were apparently contradicted by a study, in which female cats, gonadectomised at 3 months of age, were shown to have no difference in radial length when compared to sham-treated controls (Uçmak et al., 2015); although in this study, female cats were followed up only until 9 months of age. Epiphyseal fractures of the femur head are frequently observed in male gonadectomised and obese cats; it is believed, but not proven that the delayed epiphyseal closure from gonadectomy combined with being overweight are the major causes for this problem (Craig, 2001; Fischer et al., 2004; McNicholas et al., 2002). In female cats, prepubertal gonadectomy causes fewer problems than in female dogs (Howe, 2015).

Prepubertal gonadectomy and delayed epiphyseal closure may trigger epiphyseal fractures in male and female cats.

### 5.3.3 | Tumours

In a recent study the incidence of MCT, lymphoma, carcinoma and sarcoma was assessed in a population of 16,592 cats (divided in intact and neutered tom cats and intact and spayed queens) gonadectomised at various ages during the period 2000 to 2023 (Ferrè-Dolcet et al., 2023). The incidence of carcinoma was higher in cats gonadectomised early in life while the incidence of sarcoma, MCT and lymphoma were higher in cats gonadectomised later in life. When compared to intact cats, gonadectomised cats have 4.43, 6.24, 5.75 and 6.47 the odds of developing carcinoma, lymphoma, MCT and sarcoma, respectively (Ferrè-Dolcet et al., 2023). In another retrospective study, gonadectomised male and female cats had significantly increased odds of neoplasias of the lower urinary tract compared to intact cats (Lekcharoensuk et al., 2001).

These studies indicate that the risk of tumour development following gonadectomy in cats may have been under-evaluated in the past and deserves more attention from researchers, even though the impact of age and further factors must be considered.

### 5.3.4 | Lower urinary tract diseases

The term, lower urinary tract disease (LUTD), replaces the formerly used term feline urogenital syndrome and should ideally be used together with a description of the site, causes, underlying morphological changes and pathophysiologic mechanisms. Otherwise, the term idiopathic LUTD should be used. Gonadectomy at the age of 7 weeks or 7 months did not decrease urethra diameter in comparison to intact cats (Root et al., 1997) and in one study investigating the long-term outcome of early spay-neuter on the incidence of LUTD, no increased risk was found in comparison to intact cats (Howe et al., 2000). Furthermore, urethral pressure profiles and urethral function were not changed after gonadectomy (Stubbs et al., 1996). However, in one large-scale retrospective epidemiologic study, 22,908 medical records from cats (patients from veterinary teaching hospitals in the USA and Canada) with diseases of the urinary bladder, urethra and prostate gland were evaluated (Lekcharoensuk et al., 2001). Medical records from 263,168 cats without LUTD served as controls. Gonadectomised male and female cats had a significantly increased risk to develop LUTD, particularly uroliths and neoplasia, compared to intact cats of both sexes. Gonadectomised male cats had increased odds specifically for urethral obstruction, neurogenic causes, postsurgical iatrogenic injuries and idiopathic LUTD. Overweight ( $\geq 6.8$  kg) was an additional risk factor and some breeds (Persian, Manx, Himalayan cats) had higher odds than others; however, these odds were classified as weak associations. Prostate gland diseases were not part of the evaluation as the number of cases was too small. The results of the study were comparable to an earlier retrospective study (Willeberg & Priester, 1976).

Gonadectomy may contribute to the development of feline LUTD in individual cases.

### 5.3.5 | Paediatric gonadectomy

Gonadectomy at the age of 7 weeks or 7 months delayed epiphyseal closure in both male and female cats, which in male cats caused significantly longer radial bone length in comparison to intact cats (Root et al., 1997; Stubbs et al., 1996). An increased risk for epiphyseal fractures was postulated, especially in neutered males (Houlton & McGlennon, 1992; McNicholas et al., 2002); however, data on incidence are lacking. Juvenile gonadectomy may cause persistence of the penile frenulum, inhibiting protrusion of the penis (Herron, 1972; Root et al., 1996; Stubbs et al., 1996); however, a clinical impact is not proven yet.

Considering the high fertility of cats, the mostly early occurrence of puberty and the low incidence of problems, gonadectomy at the age of 3 to 4 months can be recommended. However, the cats should be in a good state of health and vaccinated.

## 6 | ETHICS OF REPRODUCTION CONTROL IN DOGS AND CATS

### 6.1 | Introduction

Gonadectomising companion animals have been routinely performed for decades in many parts of the world. Besides the benefits and risk for the individual animal that need to be considered, there is also the need to view this practice in the context of population control and shelter intake numbers. The detriments and benefits of gonadectomy are already described in detail in this document (Chapters 4 and 5). The efficacy of spaying and neutering on animal overpopulation is complex and needs to be viewed in context of responsible pet ownership. In recent years, the discussion about animal rights and the need for informed consent has been brought up and warrants discussion. Views on this topic may vary widely and are influenced by cultural and ethical diversity. This chapter aims to give an overview of the current stance of the literature and culminates in best practice depending on different settings.

### 6.2 | Overpopulation and shelter intake

Few robust studies exist that shed light on the effect spaying and neutering has on pet overpopulation and shelter intake. The data analysed is often incomplete, from various sources and of questionable reliability. The need for better “Animal Shelter Analytics” that allow data collection, maintenance and analysis has been highlighted as an important step to optimise shelter management and assess effectiveness (Yadhunath, 2021). It was estimated that 3.1 million dogs entered shelters in the USA in 2019, which equates to about 9.4 animals per 1000 residents of which about 1.2 dogs per 1000 residents were euthanized. (ASPCA, 2023). Numbers from a serial cross-sectional study in Colorado were higher with 20.1 dogs/1000 state residents entering shelters each year of which 1.4 dogs/1000 residents were euthanized. The numbers for cats were 11.6 and 1.2/1000 state residents for intake and euthanasia rates, respectively (Sloane et al., 2019). The estimated total number of dog and cat euthanasia in the USA each year varies according to different sources and ranges between 920,000 (ASPCA, 2023) to about three million (PETA, 2023). It is estimated that 9.3 dog admissions per 1000 residents occurred in Australian shelters in 2012 to 2013 for a total of 211,655 intakes (Chua et al., 2017). The number of all animals being reclaimed, rehomed and euthanased were 4.4, 29 and 1.9/1000 residents, respectively. The numbers in the UK are lower with 1.9/1000 residents being admitted to shelters and about 10% of these being euthanased (Clark et al., 2012; Stavisky et al., 2012). However, it has to be noted that the data collection methods were not standardised therefore published numbers are hard to compare (Rodriguez et al., 2022). Animals that end up in shelters and may originate from feral, stray populations or originate from owners that relinquish them. Animals at shelters may be of mixed breed or purebred heritage (Gunter et al., 2018). According to the Humane Society of the USA, around 25% of the dog population still roamed the street in 1973, which equated to about 13.5 million dogs on the streets (Rowan & Williams, 1987). It has been speculated that the drastic decrease over the last decades can be attributed to changed sterilisation practices in combination with a change in owner attitudes that view their pets as family members, which leads to improved pet confinement (Rowan & Kartal, 2018). It has been shown that low cost spay- and neuter programmes increase the number of spayed and neutered pet in the community, where they are employed. However, it is less clear if these measures have a direct impact on reducing the numbers of animals taken into shelters (Frank & Carlisle-Frank, 2007). There is a positive correlation between pet abandonment, size of stray pet populations, low voluntary pet sterilisation rates and poor socioeconomic conditions in a community (Arluke & Rowan, 2020). Sustainable pet population control requires trust, accountability and access to low-cost veterinary care in communities of low socioeconomic status (Decker Sparks et al., 2018).

### 6.3 | Trap, Neuter, Return programmes

Trap, Neuter, Return (TNR) programmes have become a widely discussed approach to reducing free-roaming animal populations. Animals are trapped, spayed or neutered and returned to either their original habitat or another location. Other methods of sterilisation such as immunocontraception, ovary-sparing surgery or vasectomy may be considered under certain circumstances (Chapters 3 and 4). TNR programmes are seen to be a humane alternative to traditional methods of controlling animal number such as euthanasia by focusing on sterilisation and population control without causing undue harm to the animals. TNR programmes are aimed at reducing the reproduction rates of free-roaming animals by sterilising them, leading to population stabilisation over time. However, the data is not clear on this point and there is evidence that such programmes only work temporarily or when employed continuously. This is because new free-roaming animals from other areas intrude and repopulate the area as animal numbers decline and animals that may have been missed by the TNR programme also repopulate the area (Boone, 2015; Gunther et al., 2022; Schmidt et al., 2009). Progress with TNR programmes can be slow as the “carrying capacity” of an area needs to be considered which is mainly affected by availability of food, which if sufficient supports reproduction. This carrying capacity of a specified area has been defined as “the number (or density) of individuals that the local environment can, on average, support” (Boone, 2015). In order for a TNR programme to be successful in an area where a feral animal population has been established and a stable state has been achieved, the overall number of offspring born in that feral population needs to be reduced by the TNR programme to below those needed for a stable carrying capacity. Therefore, there may be a significant lag time starting from implementation of the TNR programme until the impact becomes apparent. The population decline will only be noticeable when adult animals die and are no longer replaced by



young ones. The effect can further be delayed or even reversed if during this time fertile animals move into the area. Therefore, TNR programmes work best in small, closed communities that are geographically isolated with limited or no migration of outside animals (*e.g.* islands or remote communities) and where a sufficiently high proportion of the intact feral population can be trapped and neutered (Lloyd & DeVore, 2010; Nogales et al., 2013). By providing veterinary care during the neutering process, TNR programmes can enhance the overall health and welfare of the individual animal and that of the entire population.

Concurrent rabies vaccination programmes with TNR programmes, controls animal rabies and reduces zoonotic potential. A modelling study has suggested that only 30% of dogs need to be treated with an anti-GnRH and rabies combination vaccine to eradicate rabies in that region (Carroll et al., 2010). When no concurrent reproduction control is combined with rabies vaccination then the vaccination rates need be much higher (Lugelo et al., 2022; Thulke & Eisinger, 2008). Many TNR programmes encourage community involvement, fostering collaboration between animal welfare organisations, volunteers and the public, leading to increased awareness and subsequently improved animal welfare (McDonald et al., 2018). However, implementation of TNR programmes requires significant resources, such as funding, personnel and veterinary services. Long-term commitment is essential if gains in population control are to be maintained, and this may pose challenges for organisations and communities with limited resources. Unless socio economic upliftment is achieved, TNR campaigns have limited long term impact and sustained campaigns are needed to curb stray and feral animal populations. When TNR is considered as a viable alternative to euthanasia, it needs to be borne in mind that free-roaming animals, even when neutered, may threaten local wildlife populations through predation and disturbance (Moseby et al., 2015). Therefore, the decision to substitute humane euthanasia to control free roaming animals in some areas, with TNR programmes raises serious ecological impact concerns. In addition, free roaming animals may pose a threat to people and owned pets. Therefore, TNR programmes can be met with valid opposition from segments of the public and other stakeholders which should be heeded and alternative methods to combat stray and feral populations should be considered (Crawford et al., 2019).

Conclusions: TNR programmes can play a role in reducing animal overpopulation. While TNR programmes can offer humane population control and improved welfare for free roaming animals, they also face challenges. Especially relating to effectiveness, which is commonly dependent on the environment (*e.g.* open *versus* closed populations), resource demands and availability, the impact on local wildlife and also public health and perception. For each TNR programme, the available resources, and its long-term sustainability need to be carefully considered. Overall, although TNR programmes can be useful in certain situations, *e.g.* in closed populations, an integrated approach to animal overpopulation, incorporating TNR programmes with responsible pet ownership, education and community outreach initiatives is more likely to have the best success in reducing animal populations, long-term.

#### 6.4 | Responsible pet ownership

Responsible pet ownership plays a crucial role in ensuring the wellbeing of animals on the one hand and maintaining a healthy human-animal bond on the other. The concept of “Responsible pet ownership” is not new and has been already raised 50 years ago (Koltveit, 1973). However, throughout history, societies have recognised the importance of responsible pet ownership as an integral tool for effective animal control. Since medieval times, especially in the Victorian era, the perception of dog and cat ownership shifted with dogs and cats becoming not only valued for their companionship but also increasingly viewed as family members (Gordon, 2016). In earlier times, pets were mostly kept for practical purposes, such as pest control, protection and hunting, which necessitated ensuring the wellbeing and training of working animals to serve specific functions. The emergence of companion animals brought about the need for responsible pet ownership, emphasising the importance of care, shelter and veterinary care (Serpell, 1996). Responsible pet ownership plays an important role in ensuring animal welfare. Regular veterinary visits ensure preventive healthcare measures including vaccinations, contraceptive measures and parasite control, which contribute to controlling the spread of diseases, reduce zoonotic threat and reducing the number of animals in shelters. Pet overpopulation has long been a challenge, leading to overcrowded shelters and the euthanasia of large numbers of healthy animals. Responsible pet ownership addresses this issue through appropriate contraception programmes, which in turn reduce unwanted animal reproduction. However, while spaying and neutering practices are often viewed intricately linked with responsible pet ownership (RSPCA, 2024) this view is currently being questioned and other methods of contraception maybe seen as appropriate (Arluke & Rowan, 2020; Veterinary Record, 2023). Promoting responsible pet ownership requires educational initiatives aimed at raising awareness about the needs of pets. Educating prospective pet owners about their responsibilities, such as training, socialisation and commitment to lifelong care, can help to prevent impulsive decisions and subsequent pet abandonment. Teaching children about empathy and respect for animals fosters responsible behaviour towards pets from an early age onward (Hawkins et al., 2017). Responsible pet ownership involves ensuring that pets are easily identifiable and can be reunited with their owners if lost. Ensuring that pets are microchipped provides a reliable method of identification and enables quick and accurate reunions with their caregivers (Lord et al., 2009). Thereby reducing the burden on animal shelters.

Cultural shifts, such as increased awareness of animal welfare (*e.g.* ethical breeding practices, prioritising the pet’s wellbeing), higher emphasis on adoption and rescue programmes (*e.g.* “adopt, don’t shop” campaigns), change in living arrangements (*e.g.* urbanisation), changing views on training methods and the availability of digital resources may impact responsible pet ownership practices, necessitating continuous education and adaptation of animal control policies to address emerging challenges effectively. Effective animal

control and responsible pet ownership require collaboration between various stakeholders. These include the veterinary profession, animal welfare organisations, local authorities and also the wider community. Strengthening partnerships between these stakeholders can facilitate the implementation of comprehensive strategies that address the challenges of pet overpopulation, abandonment and neglect. For instance, the campaign “Trust your Vet” was launched by the British Veterinary Association, the Veterinary Medicines Directorate and the British Small Animal Veterinary Association in the UK in 2018 to promote responsible pet ownership (Jarvis, 2018). Initially intended to encourage pet owners to accept the veterinarian’s advice regarding antimicrobial prescription, it also asked owners to trust their veterinarian on other issues concerning their pet’s health and registering with a veterinarian for ongoing care.

**Conclusions:** Responsible pet ownership has evolved over time, reflecting societal changes and advancements in the public’s understanding of animal welfare. The role of responsible pet ownership in continuously improving animal welfare and reducing the challenges associated with pet overpopulation and abandonment is crucial and its promotion needs to be a continuing effort for veterinarians and veterinary associations worldwide.

### 6.5 | Variation of spaying and neutering rates

The discussion about the ethics of spaying/neutering of pets is multifaceted and regional differences exist. Whereas in many Western countries routine spaying/neutering of pets has long been seen as standard of care, this is not the case in other regions, such as Scandinavia. Only recently has spaying and neutering for cats without a medical indication been allowed in Sweden if they roam outside (Fossati, 2022).

Different attitudes are reflected in varying rates of spaying and neutering. While spay and neuter rates across both sexes in the USA have been stated to be around 64 to 78% in dogs and 82 to 85% in cats (American Pet Products Association, 2021; Trevejo et al., 2011), it is lower in Ireland where reportedly around 47% of pet dogs and 76% of pet cats are spayed and neutered (Downes et al., 2009). In Germany, it was reported that 43% of dogs are spayed and neutered (Kubinyi et al., 2009). Only close to 2% of dogs were spayed and neutered in Sweden (Sallander et al., 2001). Note that these data are mainly derived from owner-surveys, which may include a bias and may overestimate the number of spayed and castrated animals. It should be highlighted that robust data on spaying/neutering prevalence is lacking in most countries which complicates reliable comparisons and observation of trends as well as understanding the impact of spay/neuter programmes on animal numbers in total and in numbers in shelters.

### 6.6 | Early age spaying and neutering

Early age desexing (EAD) or spaying and neutering (aka paediatric spaying and neutering) is practiced to varying degrees across the world. The practice is endorsed by some large national organisations, *e.g.* the British Small Animal Veterinary Association and the British Veterinary Association, which both endorse spaying and neutering dogs before puberty and owned cats after 16 weeks and feral/rescue cats from 8 weeks (BVA, 2021). Similarly, Australia’s Royal Society for the Prevention of Cruelty to Animals recommends EAD from six to <16 weeks for kittens and for puppies in shelters (RSPCA, 2012). The decision whether early age spaying and neutering is to be performed should be based on weighing up risks and benefits and should be avoided, if possible, in client-owned dogs (Chapters 4 and 5). According to a survey, veterinarians in France do not commonly perform early spaying and neutering in cats, with only 2 % stating that they perform the procedure routinely and 56% reporting that they never perform it (Gagnon et al., 2020). In the UK 28% of surveyed veterinarians considered it appropriate to neuter 12 to 16 weeks old cats (Murray et al., 2008) and in a council in Australia 13 of 43 veterinary clinics offered EAD for pets (Verrinder, 2011).

The decline of animals taken into shelters has at least been partially attributed to widespread sterilisation practices and consequent reduction of unwanted breeding (Looney et al., 2008; Miller et al., 2014). High prevalence of spayed animals decreases the number of unwanted litters that end up in animal shelters. This, in turn, reduces the burden on animal shelters by reducing the number of animals that are taken in and also euthanased. Ultimately this allows for the space and resources being used more effectively, hopefully increasing the rate of pet adoptions. However, an earlier study demonstrated that financial incentives and marketing increased desexing rates but failed to show that this resulted in decreased shelter intake (Frank & Carlisle-Frank, 2007). More data is needed to clearly demonstrate the long-term impact spaying and neutering practices have on shelter intake rates.

### 6.7 | Ethical implications of sterilisation of dogs and cats

The question whether preventing reproduction in pets breaches the duty of care has been proposed (Wayne, 2017). The two main theories behind the debate are ‘welfarists’ on the one side and ‘abolitionists’ on the other (Francione & Garner, 2010). The stated goal of “Welfarists” is to prevent unnecessary harm to animals. Under this view, animal use by humans is acceptable for some purposes, if animals are treated humanely and no unnecessary suffering is imposed upon them. By and large, welfarists endorse sterilisation as a part of reducing aggregate harm to animals. The criticism of welfarism stems from the notion that routine sterilisation may not be justified under this view as spaying and neutering may not always be performed for the benefit of the individual animal. It is argued that it is being done rather for perceived benefits for humans such as reducing pet overpopulation or reducing nuisance behaviour thus making adoption more likely (Wayne, 2017).

Abolitionists on the other hand argue that animals have the right not to be treated as private property and pet ownership in general is not compatible with this notion (Francione & Garner, 2010). They therefore commonly endorse sterilisation as a means to reach the goal of not bringing any domesticated animals into existence.

## 6.8 | Mandatory spay and neuter laws

Mandatory Spay and Neuter (MSN) laws have been implemented in several regions worldwide, such as in areas of Europe (Fosatti, 2022), the USA (Holzer, 2008) and Australia (Orr & Jones, 2019) with the intent of increasing the number of spayed and neutered pets in the community. A significant debate around their effectiveness and their ethical implications is ongoing among various stakeholders. MSN laws are intended to benefit communities by reducing incidents of animal-related nuisance behaviours such as barking, roaming, dog-bite injuries and fighting as a result of reducing the number of (especially free-roaming) animals. Sound evidence of the effectiveness of such population control measures in client-owned and shelter animals is lacking. MSN laws have often been implemented in areas with already existing low rates of pet overpopulation, and it is unclear whether such laws would have a significant impact in areas with high rates of pet overpopulation. It is to note that current literature is predominantly based on overall spaying/neutering prevalence and not stratified into reasons, such as if the procedure were performed based on owner-preference or following mandatory requirements. In addition, multiple measures are often implemented at the same time, making it difficult to address the impact of each one, although introduction of fee-waived adult cat adoption programmes coincided with an improved cat live release rate (Weiss et al., 2013). To date there is no robust data showing the effect of mandatory spay/neuter laws on shelter intake. Furthermore, several issues complicate the enforcement of MSN laws. Significant amounts of public resources are needed for the administration of such programmes, which could be spent on other initiatives that may lead to better outcomes with questionable impact (Zanowski, 2012). The identification of intact animals may be challenging and expensive, especially when done by non-veterinarians, such as animal control officers. Unintended negative consequences should also be taken into account such as an increase in pet abandonment and relinquishment as well as an increase of unregistered/unlicensed pets if pet owners are unable or unwilling to comply. Some owners may resent the lack of personal freedom to make their own decisions on issues relating to their pet's health and reproductive status (Fallon Jr, 1994). It is also being argued that low-income or disadvantaged populations who may not have the resources to comply with these laws are disproportionately affected, making it an equality issue. It can infringe on the ability to replace existing pets as people from low-income populations may not be able to afford to buy a new pet, as spayed and neutered animals can be more costly than intact ones. In addition, such laws don't allow for individual risk-benefit assessment, which makes it impossible to take individual animal and owner circumstances into account when taking spay and neuter decisions. Also, opponents of MSN argue that it may not be an effective solution to reducing pet overpopulation (Levy et al., 2014). Ultimately, problems with free-roaming dogs cannot be separated from human population growth, urbanisation and increased waste (Jackman & Rowan, 2007).

Overall, the benefit of MSN laws has never been clearly demonstrated and their implementation is resource intensive. It could be argued that these resources may be better spent on other aspects of animal control, *e.g.* promotion of responsible pet ownership as well as promotion and implementation of low-cost spay/neuter programmes and improving shelter resources. Prospective well-designed studies are needed to identify the impact of each measure to advise on the most appropriate use to animals and humans of the limited resources that are available for animal control.

Conclusions: Recently, the veterinary profession started to question the long held believe that all dogs and cats not intended for breeding should be spayed and neutered as early as possible. Through emerging research, it is now becoming apparent that various factors need to be considered to reach the decision if spaying and neutering is in the best interest of the animal, its owner and the society at large.

The role of veterinarians is becoming increasingly important as they are perfectly positioned to advise caretakers and policy makers on the benefits and risks on an individual and population level basis. This necessitates the availability of high quality, evidence-based information on which the decision can be founded. Continuing education of veterinarians plays a key role in the dissemination of such information. In addition, more high-quality robust research into the benefits and risks of spaying and neutering is needed which may lead to global consensus on the subject. It is noteworthy that reliable data on animal numbers, in total and in shelters, are not available for most countries, which makes comparisons and impact of measures taken unreliable. This should be addressed through improved collaboration and standardisation of data collection. Prospective, well designed international research studies are needed to acquire the necessary data on shelter analytics but also to expand the understanding of stratified risk-benefit analysis of sterilisation practices to allow optimising advice to all stakeholders.

## 6.9 | Recommendations on reproduction control of dogs and cats in different settings

The decision if a dog or cat is to be spayed, neutered or otherwise being rendered infertile is influenced by several factors. While temperament traits or preexisting health conditions may influence benefit and risk assessments for an individual animal, it is important to discuss the setting in which the decision is being made as well as the setting the animal lives in or will likely live in. These recommendations may change according to individual circumstances and the final decision if and how an animal's reproductive status is altered needs to be made by the client in consultation with a veterinarian.



**Table 11. Recommendations for using different methods of reproduction control for client owned (depending on whether owners are considered responsible pet owners) versus shelter or feral female dogs and cats**

	Female dogs				Female cats			
	Client-owned dogs		Not client-owned dogs		Client-owned cats		Not client-owned cats	
	RPO	No RPO	Dogs in shelters	Feral dogs	RPO	No RPO	Cats in shelters	Feral cats
No intervention	++	–	–	–	–	–	–	–
Ovariohysterectomy	+	+	+	+	+	+	+	+
Ovariectomy	+	++	+	++	++	++	++	++
Hysterectomy	+	+	+	+	–	–	–	+
GnRH-Implant	+	*	*	–	+	–	–	+

RPO Responsible pet owner, GnRH implant Long-acting GnRH-agonist s.c. implant

Recommended in most cases: ++

Acceptable with specific indication: +

Generally not recommended: –

\*Option in countries that don't allow routine surgical spay/neuter procedures

Recommendations for the use of different sterilisation procedures for female dogs and cats in several different settings at the time of decision making with a focus on long-term (in most cases irreversible) procedures are presented in Table 11. For client-owned dogs and cats it is important to ascertain if the client is a responsible pet owner (RPO). As discussed in Chapter 5, it can be advisable, especially in certain breeds, to leave the females ovary intact. However, the owner needs to be aware of (and consent to) the management of a female dog in pro/oestrus, including the risk of unwanted pregnancy. Furthermore, the increased risk of, *e.g.* mammary tumours warrants monthly mammary exams performed by the owner following training by a veterinary professional. The inconvenience of bloody vaginal discharge and the risk of unwanted pregnancy can be eliminated by hysterectomizing the female dog. This may also be the best option in certain situations where pregnancy prevention can be impractical (*e.g.* in a multi-dog household with an intact male present). The long-term side-effects of hysterectomy in dogs are not well researched. It is therefore reasonable to hypothesise that hysterectomy may increase the risk of vaginal prolapse especially in brachycephalic breeds that are prone to hormone-dependent vaginal hyperplasia/prolapse.

At present there is insufficient evidence to ascertain that gonad-sparing surgery provides the same benefits to the animal as does remaining entirely intact as the exact relationship between the reproductive organs and other body systems has not yet been comprehensively investigated. This is an evolving field of research that may impact recommendations on reproductive control in the future. However, the current state of knowledge seems to justify hysterectomy in selected dogs owned by an RPO.

OE may be considered in some female dogs of low-risk breeds because of the client's preference or in cases in which responsible pet ownership is questionable, *e.g.* where it is unlikely that regular mammary checks will be performed. OHE instead of OE may be the most appropriate if uterine pathology is present. These two options are also recommended in feral dogs. Hysterectomy in feral dogs is not recommended, especially in settings where animals are released quickly after the procedure. Accidental breeding shortly after hysterectomy may, albeit in rare cases, result in opening of the ligated vaginal vault, which may lead to fatal peritonitis. As described in Chapter 2, OE is sufficient and recommended for most animals except where uterine pathology is already present.

In shelter dogs, where the main objective is permanent sterilisation, hysterectomy may be the most appropriate choice in breeds that have been shown to be negatively influenced by gonadectomy. When compared to client owned animals, reproduction control in shelters may require a broader approach which considers not only individual risks and benefits to the animal but also chances of being adopted. In those cases, hysterectomy may not be the best option and OE or in some cases even complete OHE may have to be performed. Ideally the decision should be delayed until the new owner has been identified and then the appropriate procedure could be undertaken before the animal is released.

If a female dog is only to be rendered temporarily infertile a GnRH implant (a long-acting GnRH agonist) might be considered. The use of GnRH implants in adult female dogs is currently not included among its official indications due to observed conditions of prolonged heats, ovarian cysts, pyometra, lactation and behavioural changes (Arlt et al., 2011; Fontaine & Fontbonne, 2011; Tal & Grinberg, 2013; Romagnoli et al., 2009; Theise, 2016). However, the prevalence of such conditions has not been studied and the scant number of their report's points to a limited risk in middle-aged to elderly female dogs. Because of the occurrence of diseases possibly linked to high systemic LH levels (discussed in detail in Chapter 3) in gonadectomised female dogs, cautious use of GnRH implants in selected cases of young female dogs may be considered as an alternative to surgery or in ovariectomised animals. Although not an official indication as well, the use of GnRH implants in female cats is characterised by much fewer side effects (Romagnoli & Ferre-Dolcet, 2022) and may be considered as a safe alternative to surgery in young to adult, healthy female cats. Other than cost and the need for owner compliance there is no described contraindication preventing lifelong GnRH implants. However, availability and local legal implications need to be considered when considering this option.

It has to be noted that paediatric gonadectomy is not recommended in neither males or females because of detrimental health effects (see Chapter 5) and should be limited for instances where no other alternatives are well accepted. Examples are shelter environ-

**Table 12. Recommendations for using different methods of reproduction control for client owned (depending on whether owners are considered responsible pet owners) versus shelter or feral male dogs and cats**

	Male dogs				Male cats			
	Client-owned dogs		Not client-owned dogs		Client-owned cats		Not client-owned cats	
	RPO	No RPO	Dogs in shelters	Feral dogs	RPO	No RPO	Cats in shelters	Feral cats
No intervention	++	–	–	–	–	–	–	–
Orchiectomy	+	++	++	++	++	++	++	++
Vasectomy	++	+	++	+	–	–	–	++
Epididymectomy	No data available		–	–	–	–	–	++
Intratesticular injection	++	++	++	–	–	–	–	–
GnRH- Implant	++	–	–	–	+	–	–	+

RPO Responsible pet owner, shelter animal, feral cat, GnRH implant Long-acting GnRH-agonist s.c. implant, intratesticular injection Intratesticular injection of a locally irritating substance, leading to testicular necrosis and infertility  
 Recommended in most cases: ++  
 Acceptable with specific indication: +  
 Generally not recommended: –

ments that have as their first priority the permanent sterilisation of pets they home and object to gonad-sparing surgeries, as that may reduce adoption rates. The situation for female cats is different than in dogs as OE in cats is not correlated with the same number and severity of health detriments as discussed in Chapter 5. Because of the difficulty in keeping intact female cats in a home setting, gonadectomy is recommended for most female cats. Hysterectomy is only recommended in some feral cats provided that they don't live in close proximity to humans. Keeping cats ovary-intact and vasectomizing male cats in such colonies will lead to the dominant vasectomised male cats continuing to unsuccessfully breed with intact females whilst also keeping out potentially intact male cats that would otherwise have displaced a gonadectomised male. Similarly, hysterectomised female cats keep intact male cats sexually occupied thereby limiting breedings with ovary intact cats that may have been missed by TNR campaigns or new arrivals within the colony (McCarthy et al., 2013). In almost all other cases OE or OHE is the method of choice to render female cats permanently sterile. A GnRH implant may be considered in certain situations where feral cats are to be sterilised without the required infrastructure to perform surgical procedures.

Recommendations for the use of different sterilisation procedures for male dogs and cats in several different settings at the time of decision making are presented in Table 12. As described for female animals above, it is important to ascertain if the animal is (or will be) living with an RPO.

For male dogs, the option of being kept gonad-intact or, if sterilisation is requested, vasectomised should be considered. Owners of vasectomized dogs need to be informed and instructed to perform regular monitoring of the dog for testicular and prostatic disease. If an owner is unlikely to perform such monitoring, orchiectomy should be recommended. This may also be appropriate for some client owned dogs living in a multi-dog household where reproductive behaviour should be avoided. However in these cases, a GnRH-implant can be considered, especially if sterility is only intended to be temporary. Similarly, to female dogs, a GnRH implant may also be used in orchiectomised dogs to lower the endogenous LH-secretion. Intratesticular injection of, *e.g.* calcium chloride or zinc gluconate is a viable sterilisation option for all male dogs if they can be monitored for complications for 7 days after application, which makes it not feasible for feral populations as they are routinely released soon after a sterilisation procedure is completed. Especially in shelters, testicular injection may be an attractive alternative to surgical procedures. In paediatric patients, especially when orchiectomy is not recommended, a vasectomy should also be considered.

For feral dog control, orchiectomy should be the treatment of choice in most situations as this has been reported to lead to reduced intermale aggression and less roaming activity, which can result in less nuisance activity and also less traffic accidents caused by roaming dogs (Jackman & Rowan, 2007; Lockwood, 1995; Wright, 1991). However, in certain projects, *e.g.* in closed populations, it may be desirable to leave the dynamics of the population unaltered and vasectomy may be more appropriate. This has the added benefit that dominant, sterilised dogs continue to breed available females without resulting in pregnancies. There is a clear need for more research in this area. Similar to the situation in female cats, leaving male pet cats intact is generally not recommended unless the cat is kept for breeding purposes. In most situations, orchiectomy is the treatment of choice as it not only renders the animals sterile but also eliminates certain unwanted behaviour. The health benefits of leaving male cats intact are not as clear as in dogs. Intratesticular injections may not eliminate testosterone production sufficiently to eliminate undesired hormone-related behaviour and is therefore not feasible in most situations. Although this may not be a big concern in feral cats, as discussed for dogs, not being able to properly monitor the occurrence of complications makes this method not recommended. Orchiectomy is also the treatment of choice in feral cat populations. However, as discussed for feral male dogs, vasectomy or epididymectomy may keep the social structure intact and lead to infertile males breeding many females thereby reducing fecundity (McCarthy et al., 2013).

In countries where routine surgical procedures in dogs are illegal, GnRH implants may be a feasible alternative, especially if the only other option would be to leave the dog intact. Owner's compliance is an issue when using GnRH implants on a regular basis and the need to present the dog for re-implantation timeously needs to be stressed with the client.

The category of “unowned stray” animals is not being discussed as situations vary widely. The recommendations for animals owned by a non-RPO or in some instances feral animals usually apply to that category but need to be considered separately in each setting.

Conclusions: The decision whether an animal is to be temporarily or permanently sterilised and by which method is dependent on a multitude of factors. While the animal’s individual health should be of paramount importance, it is recognised that there are other factors and situations that may make a less recommended option more suitable for the circumstances. The veterinarian needs to carefully weigh up risks and benefits to advise on the most appropriate option that takes the animal’s, the client’s and wider society’s needs into consideration.

### 6.10 | Position of reproduction control committee on prosthetic testicular implants

Prosthetic testicular implants (fake testes) are prosthetic implants designed to replace the removed testes in orchiectomised males. They have been used in human medicine for decades to improve quality of life by in individuals affected by testicular loss (Araújo et al., 2023; Hayon et al., 2020). In recent years, implanting testicular prosthetics became an option in dogs (Aleksiewicz et al., 2009; Itze, 2010) and has led to debate among pet owners, veterinarians and animal welfare advocates alike.

One of the main arguments in favour of prosthetic testicular implants is their potential psychological benefit to pet owners. The external physical appearance of the pet appears unchanged after orchiectomy, which may alleviate the emotional distress some owners feel due to the perception of emasculation. Owners of pets with prosthetic testicular implants can avoid potential social stigmatisation associated with orchiectomy. In some cases, pet owners may fear to face judgement or criticism from others who perceive neutering as detrimental to the animal’s masculinity, appearance or health. For pet owners involved in animal shows or those who have specific aesthetic preferences, prosthetic testicular implants can help maintain the physical appearance of an intact animal.

Prosthetic testicular implants can provide an alternative solution for maintaining the physical appearance of these animals while still addressing the need for sterilisation, however their use has the potential to mislead others about the pet’s reproductive status. For example, a pet could fraudulently be claimed to be intact if such a state is required, *e.g.* in breed conformation shows. Also, in situations where other animals are involved, prosthetic testicular implants could create confusion and misunderstanding among other pet owners, *e.g.* in a dog park setting as assessing the risk of unwanted breeding or conflicts with other animals are more difficult.

The implantation of prosthetic testicular implants carries risk for infection, implant rejection and surgical complications. The procedure involves elective anaesthesia and surgery, increasing the chances of postoperative complications (see Chapter 2). These significant health threats to the animal should be carefully considered before a decision for prosthetic testicular implants is made. Furthermore, there is an ethical debate around the question of whether the procedure is in the animal’s best interest. Critics argue that neutering is primarily performed for health and population control reasons and cosmetic alterations are not warranted. The focus should be on the overall wellbeing of the animal rather than satisfying human aesthetic preferences.

The use of prosthetic testicular implants presents a complex dilemma for pet owners and veterinarians alike. While they may offer psychological benefits to some owners and help address aesthetic concerns, the procedure is not without potential risks and ethical considerations. Pet owners have to weigh the risks and benefits of placing the implants. These include weighing the health and wellbeing of their pet against their own personal preferences. Open and informed discussions with a trusted veterinarian are vital to make responsible decisions regarding prosthetic testicular implants or any other elective cosmetic procedure for pets. The animal’s health and welfare should remain the top priority for owners and veterinarians alike.

### Acknowledgements

The help of Ms Luiza Saad Pierucci, senior veterinary student, University of Sao Paulo, Brazil, in editing the manuscript is gratefully acknowledged.

### Author contributions

**Stefano Romagnoli:** Conceptualization (lead); funding acquisition (lead); methodology (equal); project administration (lead); supervision (lead); validation (equal); visualization (equal); writing – original draft (supporting); writing – review and editing (lead). **Natali Krekeler:** Conceptualization (equal); data curation (equal); formal analysis (equal); methodology (equal); supervision (equal); validation (equal); visualization (equal); writing – original draft (lead); writing – review and editing (equal). **Kurt de Cramer:** Conceptualization (equal); data curation (equal); formal analysis (equal); methodology (equal); validation (equal); visualization (equal); writing – original draft (equal); writing – review and editing (equal). **Michelle Kutzler:** Conceptualization (equal); data curation (equal); formal analysis (equal); methodology (equal); validation (equal); visualization (equal); writing – original draft (lead); writing – review and editing (equal). **Robert McCarthy:** Conceptualization (equal); data curation (equal); formal analysis (equal); methodology (equal); supervision (equal); validation (equal); visualization (equal); writing – original draft (lead); writing – review and editing (equal). **Sabine Schaefer-Somi:** Conceptualization (equal); data curation (equal); formal analysis (equal); methodology (equal); project administration (equal); supervision (equal); validation (equal); visualization (equal); writing – original draft (lead); writing – review and editing (equal).



## Conflict of interest

None of the authors of this article has a financial or personal relationship with other people or organisations that could inappropriately influence or bias the content of the paper.

## References

- Aaron, A., Eggleton, K., Power, C. & Holt, R.E. (1996) Urethral sphincter mechanism incompetence in male dogs: a retrospective analysis of 54 cases. *Veterinary Record*, **139**, 542–546.
- Ackermann, C., Volpato, R., Destro, F., Trevisol, E., Sousa, N.R., Guaitolini, C.R.F. et al. (2012) Ovarian activity reversibility after the use of deslorelin acetate as a short-term contraceptive in domestic queens. *Theriogenology*, **78**, 817–822.
- Adachi, K., Dissen, G.A., Lomniczi, A., Xie, Q., Ojeda, S.R. & Nakai, H. (2020) Adeno-associated virus-binding antibodies detected in cats living in the northeastern United States lack neutralizing activity. *Scientific Reports*, **10**, 10073.
- Adin, C.A. (2011) Complications of ovariectomy and orchiectomy in companion animals. *Veterinary Clinics: Small Animal Practice*, **41**, 1023–1039.
- Aertsens, A., Rincon Alvarez, J., Poncet, C.M., Beaufrère, H. & Ragetly, G.R. (2015) Comparison of the tibia plateau angle between small and large dogs with cranial cruciate ligament disease. *Veterinary and Comparative Orthopaedics and Traumatology*, **28**, 385–390.
- Agudelo, C.F. (2005) Cystic endometrial hyperplasia-pyometra complex in cats. A review. *Veterinary Quarterly*, **27**, 173–182.
- Åhlberg, T.M., Salonen, H.M., Laitinen-Vapaavuori, O.M. & Mölsä, S.H. (2022) CT imaging of dogs with perineal hernia reveals large prostates with morphological and spatial abnormalities. *Veterinary Radiology & Ultrasound: The Official Journal of the American College of Veterinary Radiology and the International Veterinary Radiology Association*, **63**, 530–538.
- Ahlgren, G., Pedersen, K., Lundberg, S., Aus, G., Hugosson, J. & Abrahamsson, P.A. (2000) Regressive changes and neuroendocrine differentiation in prostate cancer after neoadjuvant hormonal treatment. *The Prostate*, **42**, 274–279.
- Akgül, Ö. & Kaya, A. (2016) Microbiological analysis of acute mastitis in a van cat. *Kafkas Universitesi Veteriner Fakültesi Dergisi*, **22**, 159–162.
- Alan, M., Cetin, Y., Sendag, S. & Eski, F. (2007) True vaginal prolapse in a bitch. *Animal Reproduction Science*, **100**, 411–414.
- Aleksiewicz, R., Adamiak, Z., Romiszewski, P., Cichecki, M. & Niedziela, D. (2009) Application of silicone implants in reconstructive surgery in dogs. Case studies. *Bulletin of the Veterinary Institute in Pulawy*, **53**, 547–552.
- American Pet Products Association. (2021) 2021–2022 APPA national pet owners survey. Greenwich, CT: American Pet Products Manufacturing Association.
- Anderson, L.J. & Jarrett, W.F. (1966) Mammary neoplasia in the dog and cat. II. Clinico-pathological aspects of mammary tumours in the dog and cat. *Journal of Small Animal Practice*, **7**, 697–701.
- Anderson, C. & Pratschke, K. (2011) Uterine adenocarcinoma with abdominal metastases in an ovariectomized cat. *Journal of Feline Medicine and Surgery*, **13**, 44–47.
- Anfinsen, K.P., Grotmol, T., Bruland, O.S. & Jonasdottir, T.J. (2011) Breed-specific incidence rates of canine primary bone tumors – a population based survey of dogs in Norway. *Canadian Journal of Veterinary Research*, **75**, 209–215.
- Angriman, D.S.R., Brito, M.M., Rui, B.R., Nichi, M. & Vannucchi, C.I. (2020) Reproductive and endocrinological effects of Benign Prostatic Hyperplasia and finasteride therapy in dogs. *Scientific Reports*, **10**, 14834.
- Any, K.O., Ogueji, C.F., Nnaji, T.O. & Udeani, I.J. (2020) Vaginal hyperplasia and progressive vaginal fold prolapse in a bullmastiff bitch. *Open Journal of Veterinary Medicine*, **10**, 55–63.
- Appleton, D.J., Rand, J.S. & Sunvold, G.D. (2001) Insulin sensitivity decreases with obesity, and lean cats with low insulin sensitivity are at greatest risk of glucose intolerance with weight gain. *Journal of Feline Medicine and Surgery*, **3**, 211–228.
- Araújo, A.S., Anacleto, S., Rodrigues, R., Tinoco, C., Cardoso, A., Oliveira, C. et al. (2023) Testicular prostheses—impact on quality of life and sexual function. *Asian Journal of Andrology*, **26**, 160–164. Available from: <https://doi.org/10.4103/aja202325>
- Arendt, M., Ambrosen, A., Fall, T., Kierczak, M., Tengvall, K., Meadows, J.R.S. et al. (2021) The ABCC4 gene is associated with pyometra in golden retriever dogs. *Scientific Reports*, **11**, 16647.
- Arlt, S.P. & Haimel, P. (2016) Cystic ovaries and ovarian neoplasia in the female dog – a systematic review. *Reproduction in Domestic Animals*, **51**(Supplement 1), 3–11.
- Arlt, S., Spankowsky, S. & Heuwieser, W. (2011) Follicular cysts and prolonged oestrus in a female dog after administration of a deslorelin implant. *New Zealand Veterinary Journal*, **59**, 87–91.
- Arlt, S., Wehrend, A. & Reichler, I.M. (2017) Kastration der Hündin – neue und alte Erkenntnisse zu Vor- und Nachteilen. *Tierärztliche Praxis Ausgabe K, Kleintiere/Heimtiere*, **45**, 253–263.
- Arluke, A. & Rowan, A. (2020) Underdogs: pets, people, and poverty. Athens: University of Georgia Press.
- Arnold, S., Arnold, P., Hubler, M., Casal, M. & Rüsch, P. (1989) Urinary incontinence in spayed bitches: prevalence and breed disposition. *Schweizer Archiv fuer Tierheilkunde*, **131**, 259–263.
- Arnold, S., Hubler, M., Casal, M., Lott, S.G., Hauser, B. & Rusch, P. (1992) The tissue transplantation of autologous ovarian tissue in the bitch for the prevention of side effects due to spaying: a retrospective study several years after surgery. *European Journal of Companion Animal Practice*, **3**, 67–71.
- Arntz, G.-J.H.M. (2019) Transvaginal laparoscopic ovariectomy in 60 dogs: description of the technique and comparison with 2-portal-access laparoscopic ovariectomy. *Veterinary Surgery*, **48**, 726–734.
- ASPCA. (2023) Pet statistics. American Society for the Prevention of Cruelty to Animals.
- Augsburger, H.R. & Cruz-Orive, L.M. (1995) Stereological analysis of the urethra in sexually intact and spayed female dogs. *Acta Anatomica*, **154**, 135–142.
- Axner, E. (2010) In: England, G. & Van Heimendahl, A. (Eds.) Clinical approach to the infertile queen. BSAVA manual of canine and feline reproduction and neonatology. Gloucester: British Small Animal Veterinary Association, pp. 63–69.
- Backus, R.C., Cave, N.J. & Keisler, D.H. (2007) Gonadectomy and high dietary fat but not high dietary carbohydrate induces gains in body weight and fat of domestic cats. *The British Journal of Nutrition*, **98**, 641–650.
- Bakhtiari, J., Khalaj, A.R., Aminlou, E. & Niasari-Naslaji, A. (2012) Comparative evaluation of conventional and transvaginal laparoscopic ovariectomy in dogs. *Veterinary Surgery*, **41**, 755–758.
- Bálint, A., Rieger, G., Miklósi, Á. & Pongrácz, P. (2017) Assessment of owner-directed aggressive behavioural tendencies of dogs in situations of possession and manipulation. *Royal Society Open Science*, **4**, 171040.
- Ball, R.L., Birchard, S.J., May, L.R., Threlfall, W.R. & Young, G.S. (2010) Ovarian remnant syndrome in dogs and cats: 21 cases (2000–2007). *Journal of the American Veterinary Medical Association*, **236**, 548–553.
- Balogh, O., Borruat, N., Andrea Meier, A., Hartnack, S. & Reichler, I.M. (2018) The influence of spaying and its timing relative to the onset of puberty on urinary and general behaviour in Labrador Retrievers. *Reproduction in Domestic Animals*, **53**, 1184–1190.
- Banchi, P., Morello, E.M., Bertero, A., Ricci, A. & Rota, A. (2022) A retrospective study and survival analysis on bitches with mammary tumours spayed at the same time of mastectomy. *Veterinary and Comparative Oncology*, **20**, 172–178.
- Banfield Pet Hospital Report. (2013) State of pet health 2013 report: spaying, neutering correlate with longer lives. State of Pet Health Report.
- Banfield Pet Hospital Report. (2020) Overweight pets: let's talk before the problem gets any bigger. In: Veterinary emerging topics (Vet)TM report, pp. 1–26.
- Baran, A., Ozdas, O.B., Gulcubuk, A., Hamzaoglu, I. & Tonguc, M. (2010) Pilot study: intratesticular injection induces sterility in male cats. *Proceedings of the 4th international symposium on non-surgical methods of pet population control*. pp. 8–10.
- Barrera, J.S. & Monnet, E. (2012) Effectiveness of a bipolar vessel sealant device for sealing uterine horns and bodies from dogs. *American Journal of Veterinary Research*, **73**, 302–305.
- Barsanti, J.A. & Finco, D.R. (1986) Canine prostatic diseases. *Veterinary Clinics of North America: Small Animal Practice*, **16**, 587–599.
- Barsanti, J.A., Edwards, P.D. & Losonsky, J. (1981) Testosterone responsive urinary incontinence in a castrated male dog. *Journal of the American Animal Hospital Association*, **17**, 117–119.
- Bartel, C., Meyer, F., Schäfer-Somi, S. & Walter, I. (2015) Expression of steroid hormone receptors in the genital structures of a true hermaphrodite pug dog. *Reproduction in Domestic Animals*, **50**, 164–167.
- Beach, F.A. (1970) Coital behavior in dogs: VI. Long-term effects of castration upon mating in the male. *Journal of Comparative and Physiological Psychology*, **70**, 1–32.

- Beal, M.W., Brown, D.C. & Shofer, F.S. (2000) The effects of perioperative hypothermia and the duration of anesthesia on postoperative wound infection rate in clean wounds: a retrospective study. *Veterinary Surgery*, **29**, 123–127.
- Beaudu-Lange, C., Larrat, S., Lange, E., Lecoq, K. & Nguyen, F. (2021) Prevalence of reproductive disorders including mammary tumors and associated mortality in female dogs. *Veterinary Sciences*, **8**, 184.
- Beauvais, W., Cardwell, J. & Brodbelt, D. (2012a) The effect of neutering on the risk of mammary tumours in dogs—a systematic review. *Journal of Small Animal Practice*, **53**, 314–322.
- Beauvais, W., Cardwell, J.M. & Brodbelt, D.C. (2012b) The effect of neutering on the risk of urinary incontinence in bitches: a systematic review. *Journal of Small Animal Practice*, **53**, 198–204.
- Beck, P. (1977) Effect of progestins on glucose and lipid metabolism. *Annals of the New York Academy of Sciences*, **286**, 434–445.
- Beijerink, N.J., Bhatti, S.F.M., Okkens, A.C., Dieleman, S.J., Mol, J.A., Duchateau, L. et al. (2007a) Adenohypophyseal function in bitches treated with medroxyprogesterone acetate. *Domestic Animal Endocrinology*, **32**, 63–78.
- Beijerink, N.J., Buijtsels, J.J.C.W., Okkens, A.C., Kooistra, H.S. & Dieleman, S.J. (2007b) Basal and GnRH-induced secretion of FSH and LH in anestrus versus ovariectomized bitches. *Theriogenology*, **67**, 1039–1045.
- Belanger, J.M., Bellumori, T.P., Bannasch, D.L., Famula, T.R. & Oberbauer, A.M. (2017) Correlation of neuter status and expression of heritable disorders. *Canine Genetics and Epidemiology*, **4**, 6.
- Bell, F.W., Klausner, J.S., Hayden, D.W., Feeney, D.A. & Johnston, S.D. (1991) Clinical and pathologic features of prostatic adenocarcinoma in sexually intact and castrated dogs: 31 cases (1970–1987). *Journal of the American Veterinary Medical Association*, **199**, 1623–1630.
- Bellah, J.R., Spencer, C.P. & Salmeri, K.R. (1989) Hemiprostic urethral avulsion during cryptorchid orchiectomy in a dog. *Journal of the American Animal Hospital Association*, **25**, 553–556.
- Bellenger, C.R. (1980) Perineal hernia in dogs. *Australian Veterinary Journal*, **56**, 434–438.
- Bellenger, C. & Chen, J. (1990) Effect of megestrol acetate on the endometrium of the prepubertally ovariectomized kitten. *Research in Veterinary Science*, **48**, 112–118.
- Belluzzi, E., Santos, M.A., Jifcovic, A., Redolfi, G., Di Virgilio, F., Deneuche, A. et al. (2022) Comparison of the incidence of intra-operative haemorrhage from ovarian vessels during ovariectomy and ovariohysterectomy of dogs and cats performed by inexperienced surgeons using surgeon's and constrictor knots. *New Zealand Veterinary Journal*, **70**, 88–94.
- Belsito, K.R., Vester, B.M., Keel, T., Graves, T.K. & Swanson, K.S. (2009) Impact of ovariohysterectomy and food intake on body composition, physical activity, and adipose gene expression in cats. *Journal of Animal Science*, **87**, 594–602.
- Bendas, A.J.R., Moreto, R.L.d.N., Coxo, A.B., Holguin, R.G. & do Vale Soares, D. (2022) Intra-abdominal transmissible venereal tumor in a dog: a case report. *Brazilian Journal of Veterinary Medicine*, **44**, e001422.
- Bender, S.C., Bergman, D.L., Wenning, K.M., Miller, L.A., Slate, D., Jackson, F.R. et al. (2009) No adverse effects of simultaneous vaccination with the immun contraceptive GonaCon™ and a commercial rabies vaccine on rabies virus neutralizing antibody production in dogs. *Vaccine*, **27**, 7210–7213.
- Benka, V.A., Scarlett, J.M., Sahrman, J., Rieke, K., Briggs, J.R., Ruple, A. et al. (2023) Age at gonadectomy, sex, and breed size affect risk of canine overweight and obese outcomes: a retrospective cohort study using data from United States primary care veterinary clinics. *Journal of the American Veterinary Medical Association*, **261**, 1316–1325.
- Bennett, P.F., Taylor, R. & Williamson, P. (2018) Demographic risk factors for lymphoma in Australian dogs: 6201 cases. *Journal of Veterinary Internal Medicine*, **32**, 2054–2060.
- Beretta, S., Apparício, M., Castro Moraes, P.d., Ribeiro, C.V., Estevam, M.V., Smargiassi, N.F. et al. (2023) True vaginal prolapse associated with retroflexion of the urinary bladder in a bitch. *The Canadian Veterinary Journal*, **64**, 252–256.
- Bermingham, E.N., Thomas, D.G., Cave, N.J., Morris, P.J., Butterwick, R.F. & German, A.J. (2014) Energy requirements of adult dogs: a meta-analysis. *PLoS One*, **9**, e109681.
- Berry, S.J., Strandberg, J.D., Saunders, W.J. & Coffey, D.S. (1986) Development of canine benign prostatic hyperplasia with age. *The Prostate*, **9**, 363–373.
- Bertazzolo, W., Dell'Orco, M., Bonfanti, U., DeLorenzi, D., Masserdotti, C., De Marco, B. et al. (2004) Cytological features of canine ovarian tumours: a retrospective study of 19 cases. *Journal of Small Animal Practice*, **45**, 539–545.
- Bethlehem, M. & van der Luer, R.J. (1993) Feliene fibro-epitheliale hyperplasie bij drie gecasteerde katers na behandeling met progestativa. *Tijdschrift voor Diergeneeskunde*, **118**, 650–652.
- Bhatti, S.F., Rao, N.A., Okkens, A.C., Mol, J.A., Duchateau, L., Ducatelle, R. et al. (2007) Role of progestin-induced mammary-derived growth hormone in the pathogenesis of cystic endometrial hyperplasia in the bitch. *Domestic Animal Endocrinology*, **33**, 294–312.
- Bianchi, M., Dahlgren, S., Massey, J., Dietschi, E., Kierczak, M., Lund-Ziener, M. et al. (2015) A multi-breed genome-wide association analysis for canine hypothyroidism identifies a shared major risk locus on CFA12. *PLoS One*, **10**, e0134720.
- Bianchi, M., Rafati, N., Karlsson, Å., Murén, E., Rubin, C.-J., Sundberg, K. et al. (2020) Whole-genome genotyping and resequencing reveal the association of a deletion in the complex interferon alpha gene cluster with hypothyroidism in dogs. *BMC Genomics*, **21**, 307.
- Biddle, D. & Macintire, D.K. (2000) Obstetrical emergencies. *Clinical Techniques in Small Animal Practice*, **15**, 88–93.
- Bleser, B., Brodbelt, D.C., Gregory, N.G. & Martinez, T.A. (2011) The association between acquired urinary sphincter mechanism incompetence in bitches and early spaying: a case-control study. *Veterinary Journal*, **187**, 42–47.
- Blottner, S. & Jewgenow, K. (2007) Moderate seasonality in testis function of domestic cat. *Reproduction in Domestic Animals*, **42**, 536–540.
- Blythe, L., Gannon, J. & Craig, A. (2007) Endocrine glands, hormones and the reproductive system. In: *U: care of the racing and retired greyhound*. Topeka, KS: Hall Commercial Printing, pp. 73–161.
- Boisclair, J. & Doré, M. (2001) Uterine angiolipoleiomyoma in a dog. *Veterinary Pathology*, **38**, 726–728.
- Boone, J.D. (2015) Better trap–neuter–return for free-roaming cats: using models and monitoring to improve population management. *Journal of Feline Medicine and Surgery*, **17**, 800–807.
- Borchelt, P.L. (1983) Aggressive behavior of dogs kept as companion animals: classification and influence of sex, reproductive status and breed. *Applied Animal Ethology*, **10**, 45–61.
- Borges, B.N. (2022) Epigenetic alterations in canine mammary cancer. *Genetics and Molecular Biology*, **45**, e20220131.
- Borges, P., Fontaine, E., Maenhoudt, C., Payan-Carreira, R., Santos, N., Leblond, E. et al. (2015) Fertility in adult bitches previously treated with a 4.7 mg subcutaneous deslorelin implant. *Reproduction in Domestic Animals*, **50**, 965–971.
- Bowersock, T.L., Wu, C.C., Inskeep, G.A. & Chester, S.T. (2000) Prevention of bacteremia in dogs undergoing dental scaling by prior administration of oral clindamycin or chlorhexidine oral rinse. *Journal of Veterinary Dentistry*, **17**, 11–16.
- Brändli, S., Palm, J., Kowalewski, M.P. & Im, R. (2021) Long-term effect of repeated deslorelin acetate treatment in bitches for reproduction control. *Theriogenology*, **173**, 73–82.
- Brendler, C., Berry, S., Ewing, L., McCullough, A.R., Cochran, R.C., Strandberg, J.D. et al. (1983) Spontaneous benign prostatic hyperplasia in the beagle. Age-associated changes in serum hormone levels, and the morphology and secretory function of the canine prostate. *The Journal of Clinical Investigation*, **71**, 1114–1123.
- Brent, L. (2019) Growing interest in hormone sparing dog sterilization and recommendations for standard identification methods. *Clinical Theriogenology*, **11**, 247–253.
- Brinkmann, J. (2015) Verhalten sich kastrierte Hunde anders als nicht kastrierte? Ergebnisse einer Besitzerbefragung. Thesis, University of Veterinary Medicine Hannover, 1–122.
- Brissot, H.N., Dupré, G.P. & Bouvy, B.M. (2004) Use of laparotomy in a staged approach for resolution of bilateral or complicated perineal hernia in 41 dogs. *Veterinary Surgery*, **33**, 412–421.
- Brodey, R.S. (1970) Canine and feline neoplasia. *Advances in Veterinary Science and Comparative Medicine*, **14**, 309–354.
- Brodey, R.S. & Roszel, J.F. (1967) Neoplasms of the canine uterus, vagina, and vulva: a clinicopathologic survey of 90 cases. *Journal of the American Veterinary Medical Association*, **151**, 1294–1307.
- Brodey, R.S., Goldschmidt, M.H. & Roszel, J.R. (1983) Canine mammary-gland neoplasms. *Journal of the American Animal Hospital Association*, **19**, 61–90.
- Brodzki, A., Łopuszyński, W., Millan, Y., Tatar, M.R., Brodzki, P., Kulpa, K. et al. (2021) Androgen and estrogen receptor expression in different types of perianal gland tumors in male dogs. *Animals*, **11**, 875.
- Bronson, R.T. (1982) Variation in age at death of dogs of different sexes and breeds. *American Journal of Veterinary Research*, **43**, 2057–2059.

- Brown, N.O., Patnaik, A.K. & MacEwen, E.G. (1985) Canine hemangiosarcoma: retrospective analysis of 104 cases. *Journal of the American Veterinary Medical Association*, **186**, 56–58.
- Brown, D.C., Conzemius, M.G., Shofer, F. & Swann, H. (1997) Epidemiologic evaluation of postoperative wound infections in dogs and cats. *Journal of the American Veterinary Medical Association*, **210**, 1302–1306.
- Bruenger, F.W., Lloyd, R.D., Miller, S.C., Taylor, G.N., Angus, W. & Huth, D.A. (1994) Occurrence of mammary tumors in beagles given radium-226. *Radiation Research*, **138**, 423–434.
- Brunn, A. (2022) Surgical castration in dogs: does the incision approach influence postoperative recovery? *Veterinary Evidence*, **7**.
- Bryan, J.N., Keeler, M.R., Henry, C.J., Bryan, M.E., Hahn, A.W. & Caldwell, C.W. (2007) A population study of neutering status as a risk factor for canine prostate cancer. *The Prostate*, **67**, 1174–1181.
- Bulman-Fleming, J. (2008) A rare case of uterine adenomyosis in a Siamese cat. *The Canadian Veterinary Journal*, **49**, 709.
- Buote, N.J. (2022) Updates in laparoscopy. *Veterinary Clinics: Small Animal Practice*, **52**, 513–529.
- Burke, T.J. (1982) Pharmacologic control of estrus in bitch and queen. *The Veterinary Clinics of North America. Small Animal Practice*, **12**, 79–84.
- Burke, T. & Reynolds, H., Jr. (1975) Megestrol acetate for estrus postponement in the bitch. *Journal of the American Veterinary Medical Association*, **167**, 285–287.
- Burke, T., Reynolds, H. & Sokolowski, J. (1977) A 280-day tolerance-efficacy study with mibolerone for suppression of estrus in the cat. *American Journal of Veterinary Research*, **38**, 469–477.
- Burrow, R., Batchelor, D. & Cripps, P. (2005) Complications observed during and after ovariohysterectomy of 142 bitches at a veterinary teaching hospital. *Veterinary Record*, **157**, 829–833.
- Burstyn, U. (2010) Management of mastitis and abscessation of mammary glands secondary to fibroadenomatous hyperplasia in a primiparturient cat. *Journal of the American Veterinary Medical Association*, **236**, 326–329.
- Bushby, P. (2013) Surgical techniques for spay/neuter. In: Miller, L. & Zawistowski, S. (Eds.) *Shelter medicine for veterinarians and staff*, 2nd edition. Ames, IA: Wiley-Blackwell, pp. 625–645.
- BVA. (2021) Neutering of cats and dogs. London: British Veterinary Association.
- Byron, J.K., Graves, T.K., Becker, M.D., Cosman, J.F. & Long, E.M. (2010) Evaluation of the ratio of collagen type III to collagen type I in periurethral tissues of sexually intact and neutered female dogs. *American Journal of Veterinary Research*, **71**, 697–700.
- Cafazzo, S., Bonanni, R. & Natoli, E. (2019) Neutering effects on social behaviour of urban unowned free-roaming domestic cats. *Animals*, **9**, 1105.
- Canapp, S.O. (2007) The canine stifle. *Clinical Techniques in Small Animal Practice*, **22**, 195–205.
- Caney, S.M., Holt, P.E., Day, M.J., Rudolf, H. & Gruffydd-Jones, T.J. (1998) Prostatic carcinoma in two cats. *Journal of Small Animal Practice*, **39**, 140–143.
- Cardwell, D.L. (1993) Pros and cons associated with early-age neutering (letter). *Journal of the American Veterinary Medical Association*, **202**, 1788–1789.
- Carnio, A., Eleni, C., Cocumelli, C., Bartolomé Del Pino, L.E., Simeoni, S., Spallucci, V. et al. (2020). Evaluation of intrinsic and extrinsic risk factors for dog visceral hemangiosarcoma: a retrospective case-control study register-based in Lazio region, Italy. *Preventive Veterinary Medicine*, **181**, 105074.
- Carr, J.G., Tobias, K.M. & Smith, L. (2014) Urethral prolapse in dogs: a retrospective study. *Veterinary Surgery*, **43**, 574–580.
- Carroll, M.J., Singer, A., Smith, G.C., Cowan, D.P. & Massei, G. (2010) The use of immunocontraception to improve rabies eradication in urban dog populations. *Wildlife Research*, **37**, 676–687.
- Cavalcá, A.M.B., Brandi, A., Fonseca-Alves, R.H., Laufer-Amorim, R. & Fonseca-Alves, C.E. (2022) P-glycoprotein and androgen receptor expression reveals independence of canine prostate cancer from androgen hormone stimulation. *International Journal of Molecular Sciences*, **23**, 1163.
- Cave, T.A., Hine, R., Howie, F., Thompson, H. & Argyle, D.J. (2002) Uterine carcinoma in a 10-month-old golden retriever. *Journal of Small Animal Practice*, **43**, 133–135.
- Cazzuli, G., Damián, J.P., Molina, E. & Pessina, P. (2022) Post-castration prostatic involution: a morphometric and endocrine study of healthy canines and those with benign prostatic hyperplasia. *Reproduction in Domestic Animals*, **57**, 157–164.
- Charlesworth, T.M. & Sanchez, F.T. (2019) A comparison of the rates of postoperative complications between dogs undergoing laparoscopic and open ovariectomy. *Journal of Small Animal Practice*, **60**, 218–222.
- Chastain, C., Graham, C. & Nichols, C. (1981) Adrenocortical suppression in cats given megestrol acetate. *American Journal of Veterinary Research*, **42**, 2029–2035.
- Chen, Z.L., Huang, X.B., Suo, J.P., Li, J. & Sun, L. (2010) The contraceptive effect of a novel filtering-type nano-copper complex/polymer composites intra-vas device on male animals. *International Journal of Andrology*, **33**, 810–817.
- Cheng, K.Y., Soh, P., Bennett, P.F. & Williamson, P. (2019) Lymphoma in Australian border collies: survey results and pedigree analyses. *Australian Veterinary Journal*, **97**, 14–22.
- Chiang, C.-F., Villaverde, C., Chang, W.-C., Fascetti, A.J. & Larsen, J.A. (2022) Prevalence, risk factors, and disease associations of overweight and obesity in cats that visited the veterinary medical teaching hospital at the University of California, Davis from January 2006 to December 2015. *Topics in Companion Animal Medicine*, **47**, 100620.
- Chisholm, H. (1993) Massive mammary enlargement in a cat. *The Canadian Veterinary Journal*, **34**, 315.
- Chua, D., Rand, J. & Morton, J. (2017) Surrendered and stray dogs in Australia—estimation of numbers entering municipal pounds, shelters and rescue groups and their outcomes. *Animals*, **7**, 50.
- Cicirelli, V., Lacalandra, G.M. & Aiudi, G.G. (2022) The effect of splash block on the need for analgesia in dogs subjected to video-assisted ovariectomy. *Veterinary Medicine and Science*, **8**, 104–108.
- Cicirelli, V., Burgio, M., Carbonari, A., Lacalandra, G.M. & Aiudi, G.G. (2023) Tissue sealing versus suture ligation in open canine ovariectomy: surgical times, intraoperative nociceptive response and frequency of complications. *Veterinary Medicine and Science*, **9**, 76–81.
- Cilip, C.M., Pierorazio, P.M., Ross, A.E., Allaf, M.E. & Fried, N.M. (2011) High-frequency ultrasound imaging of noninvasive laser coagulation of the canine vas deferens. *Lasers in Surgery and Medicine*, **43**, 838–842.
- Cimino Brown, D. (2012) Wound infection and antimicrobial use. In: Tobias, K.M. & Johnston, S.A. (Eds.) *Veterinary surgery small animal*. St. Louis: Elsevier, pp. 135–139.
- Clark, C., Gruffydd-Jones, T. & Murray, J.K. (2012) Number of cats and dogs in UK welfare organisations. *Veterinary Record*, **170**, 493.
- Classen, D.C., Evans, R.S., Pestotnik, S.L., Horn, S.D., Menlove, R.L. & Burke, J.P. (1992) The timing of prophylactic administration of antibiotics and the risk of surgical-wound infection. *New England Journal of Medicine*, **326**, 281–286.
- Clinton, R.L. (1972) Canine vasectomy: a modern solution to an age-old problem. *Veterinary Medicine, Small Animal Clinician*, **67**, 1097–1099.
- Coe, R.J., Grint, N.J., Tivers, M.S., Moore, A.H. & Holt, P.E. (2006) Comparison of flank and midline approaches to the ovariohysterectomy of cats. *Veterinary Record*, **159**, 309–313.
- Coggeshall, J.D., Franks, J.N., Wilson, D.U. & Wiley, J.L. (2012) Primary ovarian teratoma and GCT with intra-abdominal metastasis in a dog. *Journal of the American Animal Hospital Association*, **48**, 424–428.
- Cohen, D., Reif, J.S., Brodey, R.S. & Keiser, H. (1974) Epidemiological analysis of the most prevalent sites and types of canine neoplasia observed in a veterinary hospital. *Cancer Research*, **34**, 2859–2868.
- Coisman, J.G., Case, J.B., Shih, A., Harrison, K., Isaza, N. & Ellison, G. (2014) Comparison of surgical variables in cats undergoing single-incision laparoscopic ovariectomy using a LigaSure or extracorporeal suture versus open ovariectomy. *Veterinary Surgery*, **43**, 38–44.
- Coit, V.A., Gibson, I.F., Evans, N.P. & Dowell, F.J. (2008) Neutering affects urinary bladder function by different mechanisms in male and female dogs. *European Journal of Pharmacology*, **584**, 153–158.
- Coit, V.A., Dowell, F.J. & Evans, N.P. (2009) Neutering affects mRNA expression levels for the LH- and GnRH-receptors in the canine urinary bladder. *Theriogenology*, **71**, 239–247.
- Colton, M. (1965) Progestational agents in pet practice, indications, agents and doses, precautions. *Modern Veterinary Practice*, **1965**, 53–56.
- Concannon, P.W. (1993) Biology of gonadotropin secretion in adult and prepubertal female dogs. *Journal of Reproduction and Fertility*, **47**, 3–27.
- Concannon, P. (1995) Contraception in the dog. *The Veterinary Annual*, **35**, 11.
- Concannon, P. (2013) Estrus suppression in the bitch. In: Bonagura, T.D.C. (Ed.) *Kirk's current veterinary therapy XV*. St. Louis, MO: Elsevier, pp. 984–992.
- Concannon, P.W. & Meyers-Wallen, V.N. (1991) Current and proposed methods for contraception and termination of pregnancy in dogs and cats. *Journal of the American Veterinary Medical Association*, **198**, 1214–1225.
- Concannon, P., Altszuler, N., Hampshire, J., Butler, W.R. & Hansel, W. (1980) Growth hormone, prolactin, and cortisol in dogs developing mammary nodules and an acromegaly-like appearance during treatment with medroxyprogesterone acetate. *Endocrinology*, **106**, 1173–1177.



- Concannon, P.W., Spraker, T.R., Casey, H.W. & Hansel, W. (1981) Gross and histopathologic effects of medroxyprogesterone acetate and progesterone on the mammary glands of adult beagle bitches. *Fertility and Sterility*, **36**, 373–387.
- Cooley, D.M., Beranek, B.C., Schlittler, D.L., Glickman, N.W., Glickman, L.T. & Waters, D.J. (2002) Endogenous gonadal hormone exposure and bone sarcoma risk. *Cancer Epidemiology, Biomarkers and Prevention*, **11**, 1434–1440.
- Cooley, D.M., Schlittler, D.L., Glickman, L.T., Hayek, M. & Waters, D.J. (2003) Exceptional longevity in pet dogs is accompanied by cancer resistance and delayed onset of major diseases. *The Journals of Gerontology. Series A*, **58**, B1078–B1084.
- Cooper, T.K., Ronnett, B.M., Ruben, D.S. & Zink, M.C. (2006) Uterine myxoid leiomyosarcoma with widespread metastases in a cat. *Veterinary Pathology*, **43**, 552–556.
- Cornell, K.K., Bostwick, D.G., Cooley, D.M., Hall, G., Harvey, H.J., Hendrick, M.J. et al. (2000) Clinical and pathologic aspects of spontaneous canine prostate carcinoma: a retrospective analysis of 76 cases. *The Prostate*, **45**, 173–183.
- Corrada, Y., Hermo, G., Johnson, C., Trigg, T.E. & Gobbello, C. (2006) Short-term progestin treatments prevent estrous induction by a GnRH agonist implant in anestrous bitches. *Theriogenology*, **65**, 366–373.
- Costa, M.R., Oliveira, A.L., Ramos, R.M., de Moura Vidal, L.W., Borg, N. & Höglund, O.V. (2016) Ligation of the mesovarium in dogs with a self-locking implant of a resorbable polyglycolic based co-polymer: a study of feasibility and comparison to suture ligation. *BMC Research Notes*, **9**, 1–6.
- Cowan, L.A., Barsanti, J.A., Crowell, W. & Brown, J. (1991) Effects of castration on chronic bacterial prostatitis in dogs. *Journal of the American Veterinary Medical Association*, **199**, 346–350.
- Cox, M.E., Deebie, P.D., Lakhani, S. & Parsons, S.J. (1999) Acquisition of neuroendocrine characteristics by prostate tumor cells is reversible: implications for prostate cancer progression. *Cancer Research*, **59**, 3821–3830.
- Craig, L.E. (2001) Physeal dysplasia with slipped capital femoral epiphysis in 13 cats. *Veterinary Pathology*, **38**, 92–97.
- Crawford, H.M., Calver, M.C. & Fleming, P.A. (2019) A case of letting the cat out of the bag—why trap-neuter-return is not an ethical solution for stray cat (*Felis catus*) management. *Animals*, **9**, 171.
- Culp, W.T., Mayhew, P.D. & Brown, D.C. (2009) The effect of laparoscopic versus open ovariectomy on postsurgical activity in small dogs. *Veterinary Surgery*, **38**, 811–817.
- Cunto, M., Mariani, E., Anicito Guido, E., Ballotta, G. & Zambelli, D. (2019) Clinical approach to prostatic diseases in the dog. *Reproduction in Domestic Animals*, **54**, 815–822.
- Cunto, M., Ballotta, G. & Zambelli, D. (2022) Benign prostatic hyperplasia in the dog. *Animal Reproduction Science*, **247**, 107096.
- Da Costa, R.E., Kinsman, R.H., Owczarzak-Garstecka, S.C., Casey, R.A., Tasker, S., Knowles, T.G. et al. (2022) Age of sexual maturity and factors associated with neutering dogs in the UK and the Republic of Ireland. *Veterinary Record*, **191**, e1265.
- Dalrymple, A.M., MacDonald, L.J. & Kreisler, R.E. (2022) Ear-tipping practices for identification of cats sterilized in trap-neuter-return programs in the USA. *Journal of Feline Medicine and Surgery*, **24**, e302–e309.
- Daniel, S.S., Sardinas, J.C. & Montavon, P.M. (2016) Ventral midline preputial approach to the caudal abdomen in male dogs. *Veterinary Surgery*, **45**, 723–725.
- Das, M.R., Patra, R.C., Das, R.K., Rath, P.K. & Mishra, B.P. (2017) Hemato-biochemical alterations and urinalysis in dogs suffering from benign prostatic hyperplasia. *Veterinary World*, **10**, 331–335.
- Davidson, A.P. & Baker, T.W. (2009) Reproductive ultrasound of the bitch and queen. *Topics in Companion Animal Medicine*, **24**, 55–63.
- Davies, O. & Taylor, A.J. (2020) Refining the “double two-thirds” rule: genotype-based breed grouping and clinical presentation help predict the diagnosis of canine splenic mass lesions in 288 dogs. *Veterinary and Comparative Oncology*, **18**, 548–558.
- De Cramer, K.G.M., Joubert, K.E. & Nöthling, J.O. (2016) Hematocrit changes in healthy periparturient bitches that underwent elective cesarean section. *Theriogenology*, **86**, 1333–1340.
- De Gier, J., Kooistra, H. & Vinke, C. (2013) The effects of orchietomy and chemical castration using deslorelin on male dog behavior (abstract). *Proceeding of EVSSAR Congress*. Toulouse.
- DeCampos, C., Damasceno, K.A., Gamba, C.O., Ribeiro, A.M., Machado, C.J., Lavallo, G.E. et al. (2016) Evaluation of prognostic factors and survival rates in malignant feline mammary gland neoplasms. *Journal of Feline Medicine and Surgery*, **18**, 1003–1012.
- Decker Sparks, J.L., Camacho, B., Tedeschi, P. & Morris, K.N. (2018) Race and ethnicity are not primary determinants in utilizing veterinary services in underserved communities in the United States. *Journal of Applied Animal Welfare Science*, **21**, 120–129.
- DeForge, T.L. (2020) Sertoli cell tumor/mixed germ cell-stromal cell tumor as separate neoplasms in a bilaterally cryptorchid dog. *The Canadian Veterinary Journal*, **61**, 994–996.
- Delaune, T., Matres-Lorenzo, L., Bernardé, A. & Bernard, F. (2021) Use of a T'LIFT transabdominal organ retraction device in two-portal laparoscopic ovariectomy in dogs. *Veterinary Surgery*, **50**(Supplement 1), 040–048.
- Demirel, M.A. & Acar, D.B. (2012) Ovarian remnant syndrome and uterine stump pyometra in three queens. *Journal of Feline Medicine and Surgery*, **14**, 913–918.
- Demirel, M.A. & Ergin, I. (2014) Medical and surgical approach to gangrenous mastitis related to galactostasis in a cat. *Acta Scientiae Veterinariae*, **42**, 1–4.
- DeNardo, G.A., Becker, K., Brown, N.O. & Dobbins, S. (2001) Ovarian remnant syndrome: revascularization of free-floating ovarian tissue in the feline abdominal cavity. *Journal of the American Veterinary Medical Association*, **37**, 290–296.
- DeTora, M. & McCarthy, R.J. (2011) Ovariectomy versus ovariectomy for elective sterilization of female dogs and cats: is removal of the uterus necessary? *Journal of the American Veterinary Medical Association*, **239**, 1409–1412.
- Devereaux, K.A. & Schoolmeester, J.K. (2019) Smooth muscle tumors of the female genital tract. *Surgical Pathology Clinics*, **12**, 397–455.
- Devitt, C.M., Cox, R.E. & Hailey, J.J. (2005) Duration, complications, stress, and pain of open ovariectomy versus a simple method of laparoscopic-assisted ovariectomy in dogs. *Journal of the American Veterinary Medical Association*, **227**, 921–927.
- Di Sant'Agnese, P.A. (1992) Neuroendocrine differentiation in carcinoma of the prostate. Diagnostic, prognostic, and therapeutic implications. *Cancer*, **70**, 254–268.
- Di Sant'Agnese, P.A. (1998) Neuroendocrine cells of the prostate and neuroendocrine differentiation in prostatic carcinoma: a review of morphologic aspects. *Urology*, **51**, 121–124.
- Diez-Bru, N., Garcia-Real, I., Martínez, E.M., Rollan, E., Mayenco, A. & Llorens, P. (1998) Ultrasonographic appearance of ovarian tumors in 10 dogs. *Veterinary Radiology & Ultrasound*, **39**, 226–233.
- Dissen, G.A., Lomniczi, A., Boudreau, R.L., Chen, Y.H., Davidson, B.L. & Ojeda, S.R. (2012) Applying gene silencing technology to contraception. *Reproduction in Domestic Animals*, **47**, 381–386.
- Dissen, G.A., Adachi, K., Lomniczi, A., Chatkupt, T., Davidson, B.L., Nakai, H. et al. (2017) Engineering a gene silencing viral construct that targets the cat hypothalamus to induce permanent sterility: an update. *Reproduction in Domestic Animals*, **52**, 354–358.
- Dixon, R.M. & Mooney, C.T. (1999) Canine serum thyroglobulin autoantibodies in health, hypothyroidism and non-thyroidal illness. *Research in Veterinary Science*, **66**, 243–246.
- Dixon, R.M., Reid, S.W. & Mooney, C.T. (1999) Epidemiological, clinical, haematological and biochemical characteristics of canine hypothyroidism. *Veterinary Record*, **145**, 481–487.
- Dobson, J.M. (2013) Breed-predispositions to cancer in pedigree dogs. *ISRN Veterinary Science*, **2013**, 941275.
- Dobson, J.M., Samuel, S., Milstein, H., Rogers, K. & Wood, J.L.N. (2002) Canine neoplasia in the UK: estimates of incidence rates from a population of insured dogs. *Journal of Small Animal Practice*, **43**, 240–246.
- D'Onise, K., Hazel, S. & Caraguel, C. (2017) Mandatory desexing of dogs: one step in the right direction to reduce the risk of dog bite? A systematic review. *Injury Prevention: Journal of the International Society for Child and Adolescent Injury Prevention*, **23**, 212–218.
- Donnay, I., Rauis, J. & Verstegen, J. (1994) Influence des antécédents hormonaux sur l'apparition clinique des tumeurs mammaires chez la chienne. Étude épidémiologique. *Annales de Médecine Vétérinaires*, **138**, 109–117.
- Dorfmann, M. & Barsanti, J.A. (1995) CVT update: treatment of canine bacterial prostatitis. In: Current veterinary therapy XII. Philadelphia, PA: WB Saunders.
- Dorn, A.S. (1975) Ovariectomy by the flank approach. *Veterinary Medicine Small Animal Clinician*, **70**, 569–573.
- Dorn, M. & Seath, I.J. (2018) Neuter status as a risk factor for canine intervertebral disc herniation (IVDH) in dachshunds: a retrospective cohort study. *Canine Genetics and Epidemiology*, **5**, 1–14.
- Dorn, C.R., Taylor, D.O. & Hibbard, H.H. (1967) Epizootologic characteristics of canine and feline leukemia and lymphoma. *American Journal of Veterinary Research*, **28**, 993–1001.
- Dorn, C.R., Taylor, D.O., Schneider, R., Hibbard, H.H. & Klauber, M.R. (1968) Survey of animal neoplasms in Alameda and Contra Costa Counties, California. II. Cancer morbidity in dogs and cats from Alameda County. *Journal of the National Cancer Institute*, **40**, 307–318.

- Dow, C. (1960) Ovarian abnormalities in the bitch. *Journal of Comparative Pathology*, **70**, 59–69.
- Dow, C. (1962) Testicular tumours in the dog. *Journal of Comparative Pathology*, **72**, 247–265.
- Downes, S.J. (1969) Vasectomy of a tom cat. *The Veterinary Record*, **84**, 672.
- Downes, M., Canty, M.J. & More, S.J. (2009) Demography of the pet dog and cat population on the Island of Ireland and human factors influencing pet ownership. *Preventive Veterinary Medicine*, **92**, 140–149.
- Downes, M.J., Devitt, C., Downes, M.T. & More, S.J. (2015) Neutering of cats and dogs in Ireland; pet owner self-reported perceptions of enabling and disabling factors in the decision to neuter. *PeerJ*, **3**, e11196.
- Doxsee, A.L., Yager, J.A., Best, S.J. & Foster, R.A. (2006) Extratesticular interstitial and Sertoli cell tumors in previously neutered dogs and cats: a report of 17 cases. *The Canadian Veterinary Journal*, **47**, 763–766.
- Druce, J.D., Robinson, W.F., Locarnini, S.A., Kyaw-Tanner, M.T., Sommerlad, S.F. & Birch, C.J. (1997) Transmission of human and feline immunodeficiency viruses via reused suture material. *Journal of Medical Virology*, **53**, 13–18.
- Dube, D., Assaf, A., Pelletier, G. & Labrie, F. (1987) Morphological study of the effects of an GnRH agonist on the canine testis after 4 months of treatment and recovery. *Acta Endocrinologica*, **116**, 413–417.
- Duerr, F.M., Duncan, C.G., Savicky, R.S., Park, R.D., Egger, E.L. & Palmer, R.H. (2007) Risk factors for excessive tibial plateau angle in large-breed dogs with cranial cruciate ligament disease. *Journal of the American Veterinary Medical Association*, **231**, 1688–1691.
- Duval, J., Budsberg, S., Flo, G. & Sammarco, J.L. (1999) Breed, sex, and body weight as risk factors for rupture of the cranial cruciate ligament in young dogs. *Journal of the American Veterinary Medical Association*, **215**, 811–814.
- Edmunds, G.L., Smalley, M.J., Beck, S., Errington, R.J., Gould, S., Winter, H. et al. (2021) Dog breeds and body conformations with predisposition to osteosarcoma in the UK: a case-control study. *Canine Genet Epidemiol*, **8**, 2.
- Egenvall, A., Hagman, R., Bonnett, B.N., Hedhammar, A., Olson, P. & Lagerstedt, A.S. (2001) Breed risk of pyometra in insured dogs in Sweden. *Journal of Veterinary Internal Medicine*, **15**, 530–538.
- Egenvall, A., Bonnett, B.N., Ohagen, P., Olson, P., Hedhammar, A. & von Euler, H. (2005) Incidence of and survival after mammary tumors in a population of over 80,000 insured female dogs in Sweden from 1995 to 2002. *Preventive Veterinary Medicine*, **69**, 109–127.
- Egenvall, A., Nødtvedt, A. & Euler, H.v. (2007) Bone tumors in a population of 400 000 insured Swedish dogs up to 10 y of age: incidence and survival. *Canadian Journal of Veterinary Research*, **71**, 292–299.
- Egenvall, A., Bonnett, B.N., Häggström, J., Holst, B.S., Möller, L. & Nødtvedt, A. (2010) Morbidity of insured Swedish cats during 1999–2006 by age, breed, sex, and diagnosis. *Journal of Feline Medicine and Surgery*, **12**, 948–959.
- Ehrhardt, C., Odunayo, A., Pascutti, K., Carvajal, J., Ham, K. & Harris, A.N. (2023) Stump pyometra in a spayed female dog secondary to tamoxifen. *Veterinary Medicine and Science*, **9**, 47–52.
- Eigenmann, J.E., Eigenmann, R.Y. & Rijnberk, A. (1983) Progesterone-controlled growth hormone overproduction and naturally occurring canine diabetes and acromegaly. *Acta Endocrinologica*, **104**, 167–176.
- Elbahi, A.M., Mahgiubi, S.A.M. & Gaja, A.O. (2022) Ovarian granulosa cell tumor in a Persian cat: Case report from Tripoli, Libya. *Open Veterinary Journal*, **12**, 519–524.
- Ellis, C. (1975) Oral progestogens in cats. *The Veterinary Record*, **96**, 513–514.
- Enginler, S. & Senunver, A. (2011) The effects of progesterone hormone applications used for suppression of estrus on mammary glands in queens. *Kafkas Üniversitesi Veteriner Fakültesi Dergisi*, **17**, 277–284.
- England, G. (1997) Effect of progestogens and androgens upon spermatogenesis and steroidogenesis in dogs. *Journal of Reproduction and Fertility. Supplement*, **51**, 123–138.
- Erickson, A.K., Fox-Alvarez, W.A., Regier, P.J. & Case, J.B. (2020) In vitro holding strength of the laparoscopic Miller's knot compared with open Miller's knot, open surgeon's throw, and laparoscopic surgeon's throw in a vascular pedicle model. *Veterinary Surgery*, **49**, 1563–1570.
- Ettinger, A.M., Gust, S.K. & Kutzler, M.A. (2019) Luteinizing hormone receptor expression by nonneoplastic and neoplastic canine lymphocytes. *American Journal of Veterinary Research*, **80**, 572–577.
- Eugster, S., Schawalder, P., Gaschen, F. & Boerlin, P. (2004) A prospective study of postoperative surgical site infections in dogs and cats. *Veterinary Surgery*, **33**, 542–550.
- Evans, J. & Sutton, D. (1989) The use of hormones, especially progestagens, to control oestrus in bitches. *Journal of Reproduction and Fertility. Supplement*, **39**, 163–173.
- Evci, E.C., Aslan, S., Schäfer-Somi, S., Ergene, O., Sayiner, S., Darbaz, I. et al. (2023) Monitoring of canine pregnancy by considering anti-Müllerian hormone, C-reactive protein, progesterone and complete blood count in pregnant and non-pregnant dogs. *Theriogenology*, **195**, 69–76.
- Faggella, A.M. & Aronsohn, M.G. (1994) Evaluation of anesthetic protocols for neutering 6- to 14-week-old pups. *Journal of the American Veterinary Medical Association*, **205**, 308–314.
- Fagundes, A.K.F., Oliveira, E.C., Tenorio, B.M., Melo, C.C.S., Nery, L.T.B., Santos, F.A.B. et al. (2014) Injection of a chemical castration agent, zinc gluconate, into the testes of cats results in the impairment of spermatogenesis: a potentially irreversible contraceptive approach for this species? *Theriogenology*, **81**, 230–236.
- Fahim, M., Fahim, Z., Harman, J., Thompson, I., Montie, J. & Hall, D.G. (1977) Ultrasound as a new method of male contraception. *Fertility and Sterility*, **28**, 823–831.
- Fahim, M., Wang, M., Sutcu, M., Fahim, Z. & Youngquist, R.S. (1993) Sterilization of dogs with intra-epididymal injection of zinc arginine. *Contraception*, **47**, 107–122.
- Fall, T., Hamlin, H.H., Hedhammar, A., Kämpe, O. & Egenvall, A. (2007) Diabetes mellitus in a population of 180,000 insured dogs: incidence, survival, and breed distribution. *Journal of Veterinary Internal Medicine*, **21**, 1209–1216.
- Fall, T., Hedhammar, A., Wallberg, A., Fall, N., Ahlgren, K.M., Hamlin, H.H. et al. (2010) Diabetes mellitus in elkhounds is associated with diestrus and pregnancy. *Journal of Veterinary Internal Medicine*, **24**, 1322–1328.
- Fallon, R.H., Jr. (1994) Two senses of autonomy. *Stanford Law Review*, (APR 1), 875–905.
- Famula, T.R., Belanger, J.M. & Oberbauer, A.M. (2003) Heritability and complex segregation analysis of hypoadrenocorticism in the standard poodle. *Journal of Small Animal Practice*, **44**, 8–12.
- Farhoody, P., Mallawaarachchi, I., Tarwater, P.M., Serpell, J.A., Duffy, D.L. & Zink, C. (2018) Aggression toward familiar people, strangers, and conspecifics in gonadectomized and intact dogs. *Frontiers in Veterinary Science*, **5**, 18.
- Faro, T.A.S. & Oliveira, E.H.C.d. (2023) Canine transmissible venereal tumor – from general to molecular characteristics: a review. *Animal Genetics*, **54**, 82–89.
- Farris, G.M. & Benjamin, S.A. (1993) Inhibition of myelopoiesis by conditioned medium from cultured canine thymic cells exposed to estrogen. *American Journal of Veterinary Research*, **54**, 1366–1373.
- Faya, M., Carranza, A., Priotto, M., Graiff, D., Zurbriggen, G., Diaz, J.D. et al. (2011) Long-term melatonin treatment prolongs interestrus, but does not delay puberty, in domestic cats. *Theriogenology*, **75**, 1750–1754.
- Faya, M., Marchetti, C., Priotto, M., Grisolia, M., D'Francisco, F. & Gobello, C. (2018) Postponement of canine puberty by neonatal administration of a long term release GnRH superagonist. *Theriogenology*, **118**, 190–195.
- Feldhahn, J.R., Rand, J.S. & Martin, G. (1999) Insulin sensitivity in normal and diabetic cats. *Journal of Feline Medicine and Surgery*, **1**, 107–115.
- Ferré-Dolcet, L., Carniello, L., Ferro, S., Cattai, A., Romagnoli, S. & Mollo, A. (2020a) Interval between removal of a 4.7 mg deslorelin implant after a 3-, 6-, and 9-month treatment and restoration of testicular function in tomcats. *Animals*, **10**, 1559.
- Ferré-Dolcet, L., Romagnoli, S., Banzato, T., Cavicchioli, L., Di Maggio, R., Cattai, A. et al. (2020b) Progesterone-responsive vaginal leiomyoma and hyperprogesteronemia due to ovarian luteoma in an older bitch. *BMC Veterinary Research*, **16**, 284.
- Ferré-Dolcet, L., Ferro, S., Contiero, B., Andretta, F., Cattai, A., Fontaine, C. et al. (2022) Resumption of ovarian activity following removal of a 4.7 mg deslorelin implant in queens. *Reproduction in Domestic Animals*, **57**, 3–9.
- Ferré-Dolcet, L., Ventura, L. & Marchiori, A. (2023) Long term effect of neutering on cancer development in cats: can we compare it to the dog? Submitted. *Proceedings 1st European Veterinary Reproduction Congress*, Nantes, France, 21–23 September.
- Fink, R.L., Caridis, D.T., Chmiel, R. & Ryan, G. (1980) Renal impairment and its reversibility following variable periods of complete ureteric obstruction. *The Australian and New Zealand Journal of Surgery*, **50**, 77–83.
- Fischer, H.R., Norton, J., Kobluk, C.N., Reed, A.L., Rooks, R.L. & Borostyankoi, F. (2004) Surgical reduction and stabilization for repair of femoral capital physeal fractures in cats: 13 cases (1998–2002). *Journal of the American Veterinary Medical Association*, **224**, 1478–1482.

- Fischer, A., Benka, V.A., Briggs, J.R., Driancourt, M.-A., Maki, J., Mora, D.S. et al. (2018) Effectiveness of GonaCon as an immunocontraceptive in colony-housed cats. *Journal of Feline Medicine and Surgery*, **20**, 786–792.
- Fontaine, E. & Fontbonne, A. (2011) Clinical use of GnRH agonists in canine and feline species. *Reproduction in Domestic Animals*, **46**, 344–353.
- Fontaine, E., Maenhoudt, C., Mir, F., Navarro, C. & Fontbonne, A. (2012) Postponement of puberty using GnRH agonist implants in bitches of different breeds. *Proceedings of the 7th International Symposium on Canine and Feline Reproduction*, Whistler, BC, Canada. pp. 26–29.
- Fontes, G.S. & McCarthy, R.J. (2020) Ovarian remnant syndrome in a cat with ovarian tissue in the omentum. *Journal of the American Veterinary Medical Association*, **257**, 631–634.
- Forzán, M., Garde, E., Perez, G. & Vanderstichel, R.V. (2014) Necrosuppurative orchitis and scrotal necrotizing dermatitis following intratesticular administration of zinc gluconate neutralized with arginine (EsterilSol) in 2 mixed-breed dogs. *Veterinary Pathology*, **51**, 820–823.
- Fossati, P. (2022) Spay/neuter laws as a debated approach to stabilizing the populations of dogs and cats: an overview of the European legal framework and remarks. *Journal of Applied Animal Welfare Science*, **27**, 281–293. Available from: <https://doi.org/10.1080/10888705.2022.2081807>
- Foster, R.A., Caswell, J.L. & Rinkardt, N. (1996) Chronic fibrinous and necrotic orchitis in a cat. *The Canadian Veterinary Journal=La revue veterinaire canadienne*, **37**, 681–682.
- Francione, G.L. & Garner, R. (2010) *The animal rights debate: abolition or regulation?* New York: Columbia University Press.
- Frank, J.M. & Carlisle-Frank, R.L. (2007) Analysis of programs to reduce overpopulation of companion animals: do adoption and low-cost spay/neuter programs merely cause substitution of sources? *Ecological Economics*, **62**, 740–746.
- Fransson, B.A. (2017) Ovaries and uterus. In: Johnston, S.A. & Tobias, K.M. (Eds.) *Veterinary surgery: small Animal expert consult*, 2nd edition. St. Louis, MO: Elsevier, pp. 2109–2130.
- Fransson, B.A. & Mayhew, P.D. (2015) *Small Animal Laparoscopy and Thoracoscopy*. Hoboken, NJ: John Wiley and Sons.
- Fraser, H. (1988) 9 LHRH analogues: their clinical physiology and delivery systems. *Baillière's Clinical Obstetrics and Gynaecology*, **2**, 639–658.
- Frenette, M.D., Dooley, M.P. & Pineda, M.H. (1986) Effect of flushing the vasa deferentia at the time of vasectomy on the rate of clearance of spermatozoa from the ejaculates of dogs and cats. *American Journal of Veterinary Research*, **47**, 463–470.
- Freshman, J., Olson, P., Amann, R., Carlson, E.D., Twedt, D.C. & Bowen, R.A. (1990) The effects of methyltestosterone on reproductive function in male greyhounds. *Theriogenology*, **33**, 1057–1073.
- Frey, E., Costin, M., Granick, J., Kornya, M. & Weese, J.S. (2022) 2022 AAFP/AAHA antimicrobial stewardship guidelines. *Journal of the American Veterinary Medical Association*, **58**, 1–5.
- Fried, N.M., Roberts, W.W., Sinelnikov, Y.D., Wright, E.J. & Solomon, S.B. (2002) Focused ultrasound ablation of the epididymis with use of thermal measurements in a canine model. *Fertility and Sterility*, **78**, 609–613.
- Fudge, J.M., Lee, I., Page, B. & Jeffery, U. (2022) Comparison of preoperative to postoperative blood glucose in puppies undergoing elective surgical neutering. *The Veterinary Journal*, **281**, 105811.
- Furthner, E., Roos, J., Niewiadomska, Z., Maenhoudt, C. & Fontbonne, A. (2020) Contraceptive implants used by cat breeders in France: a study of 140 purebred cats. *Journal of Feline Medicine and Surgery*, **22**, 984–992.
- Furthner, E., Fabian, R., Kipar, A., Schuler, G., Janett, F., Nudelman, N. et al. (2023) Epididymectomy as a novel surgical procedure; application in the domestic cat. *Theriogenology*, **200**, 168–178.
- Gagnon, A.C., Langlade, C., Rosset, E. & Buff, S. (2020) French veterinarians' opinions and practices regarding early neutering of cats: a convenience sampling survey interpreted in an international context. *Veterinary Record*, **187**, e120.
- Gamlem, H., Nordstoga, K. & Arnesen, K. (2008) Canine vascular neoplasia – a population-based clinicopathologic study of 439 tumours and tumour-like lesions in 420 dogs. *APMIS. Supplementum*, **125**, 41–54.
- Ganguly, B., Das, U. & Das, A.K. (2016) Canine transmissible venereal tumour: a review. *Veterinary and Comparative Oncology*, **14**, 1–12.
- Gannon, J. (1976) Clinical aspects of the oestrus cycle in the greyhound. *Racing Greyhound*, **1**, 12–22.
- Ganz, S., Wehrend, A. & Georgiev, P. (2020) Chirurgisches Vorgehen bei einem Vaginalfaltenvorfall in der Läufigkeit bei einer Deutschen Dogge. *Tierärztliche Praxis Ausgabe K, Kleintiere/Heimtiere*, **48**, 39–43.
- García Romero, G., Fernández, P., Gimeno, E., Barbeito, C. & Gobello, C. (2012) Effects of the GnRH antagonist acyline on the testis of the domestic cat (*Felis catus*). *The Veterinary Journal*, **193**, 279–282.
- Garde, E., Pérez, G., Vanderstichel, R., Villa, P.F.D. & Serpell, J.A. (2016) Effects of surgical and chemical sterilization on the behavior of free-roaming male dogs in Puerto Natales, Chile. *Preventive Veterinary Medicine*, **123**, 106–120.
- Gaunt, S.D. & Pierce, K.R. (1986) Effects of estradiol on hematopoietic and marrow adherent cells of dogs. *American Journal of Veterinary Research*, **47**, 906–909.
- Gazin, A.A., Vatnikov, Y.A., Sturov, N.V., Kulikov, E.V., Grishin, V., Krotova, E.A. et al. (2022) Canine testicular tumors: an 11-year retrospective study of 358 cases in Moscow Region, Russia. *Veterinary World*, **15**, 483–487.
- Gedon, J., Wehrend, A., Failing, K. & Kessler, M. (2021a) Canine mammary tumours: size matters – a progression from low to highly malignant subtypes. *Veterinary and Comparative Oncology*, **19**, 707–713.
- Gedon, J., Wehrend, A. & Kessler, M. (2021b) Ovariectomy reduces the risk of tumour development and influences the histologic continuum in canine mammary tumours. *Veterinary and Comparative Oncology*, **20**, 476–483.
- Gelberg, H.B. & McEntee, K. (1984) Hyperplastic endometrial polyps in the dog and cat. *Veterinary Pathology*, **21**, 570–573.
- Gelberg, H.B. & McEntee, K. (1985) Feline ovarian neoplasms. *Veterinary Pathology*, **22**, 572–576.
- German, A.J. (2006) The growing problem of obesity in dogs and cats. *The Journal of Nutrition*, **136**, 1940S–1946S.
- German, A.J., Blackwell, E., Evans, M. & Westgarth, C. (2017) Overweight dogs are more likely to display undesirable behaviours: results of a large online survey of dog owners in the UK. *Journal of Nutritional Science*, **6**, e14.
- Ghaffari, M.S. (2008) Iatrogenic hyperlipidemia associated with lipid-laden aqueous humor in a cat following administration of megestrol acetate. *Turkish Journal of Veterinary & Animal Sciences*, **32**, 399–401.
- de Gier, J., Buijts, J.J.C.W.M., Albers-Wolthers, C.H.J., Oei, C.H.Y., Kooistra, H.S. & Okkens, A.C. (2012) Behaviour and the pituitary-testicular axis in dogs before and after surgical or chemical castration with the GnRH agonist deslorelin. *7th Quadrennial International Symposium on Canine and Feline Reproduction*.
- Gill, S.S. & Barstad, R.D. (2018) A review of the surgical management of perineal hernias in dogs. *Journal of the American Animal Hospital Association*, **54**, 179–187.
- Gilson, S.A. (2016) Cesarean section. In: Aronson, L.R. (Ed.) *Small animal surgical emergencies*. Ames, IA: Wiley Blackwell, pp. 391–396.
- Gimenez, F., Stornelli, M., Tittarelli, C., Savignone, C.A., Dorna, I.V., de la Sota, R.L. et al. (2009) Suppression of estrus in cats with melatonin implants. *Theriogenology*, **72**, 493–499.
- Gionfriddo, J.P., Denicola, A.J., Miller, L.A. & Fagerstone, K.A. (2011) Efficacy of GnRH immunocontraception of wild white-tailed deer in New Jersey. *Wildlife Society Bulletin*, **35**, 142–148.
- Glickman, L.T., Schofer, F.S., McKee, L.J., Reif, J.S. & Goldschmidt, M.H. (1989) Epidemiologic study of insecticide exposures, obesity, and risk of bladder cancer in household dogs. *Journal of Toxicology and Environmental Health*, **28**, 407–414.
- Gobello, C. (2021) Revisiting canine pseudocyesis. *Theriogenology*, **167**, 94–98.
- Gobello, C., La Sota, R.L.D. & Goya, R.G. (2001) A review of canine pseudocyesis. *Reproduction in Domestic Animals*, **36**, 283–288.
- Goddard, M. & Beilharz, R. (1986) Early prediction of adult behaviour in potential guide dogs. *Applied Animal Behaviour Science*, **15**, 247–260.
- Goericke-Pesch, S. (2017) Long-term effects of GnRH agonists on fertility and behaviour. *Reproduction in Domestic Animals*, **52**, 336–347.
- Goericke-Pesch, S., Wilhelm, E. & Hoffmann, B. (2010a) Hormonal downregulation of testicular function in the dog and cat - a retrospective study. *Praktischer Tierarzt*, **91**, 563.
- Goericke-Pesch, S., Wilhelm, E., Ludwig, C., Desmoulins, P.O., Driancourt, M.A. & Hoffmann, B. (2010b) Evaluation of the clinical efficacy of Gonazon implants in the treatment of reproductive pathologies, behavioral problems, and suppression of reproductive function in the male dog. *Theriogenology*, **73**, 920–926.
- Goericke-Pesch, S., Georgiev, P., Antonov, A., Albouy, M. & Wehrend, A. (2011) Clinical efficacy of a GnRH-agonist implant containing 4.7 mg deslorelin, Suprelorin®, regarding suppression of reproductive function in tomcats. *Theriogenology*, **75**, 803–810.
- Goericke-Pesch, S., Georgiev, P., Atanasov, A., Albouy, M., Navarro, C. & Wehrend, A. (2013) Treatment of queens in estrus and after estrus with a GnRH-agonist implant containing 4.7 mg deslorelin; hormonal response, duration of efficacy, and reversibility. *Theriogenology*, **79**, 640–646.



- Goericke-Pesch, S., Georgiev, P., Antonov, A., Vodenicharov, A., Navarro, C. & Wehrend, A. (2014) Reversibility of germinative and endocrine testicular function after long-term contraception with a GnRH-agonist implant in the tom—a follow-up study. *Theriogenology*, **81**, 941–946.
- Golden, T. (2014) Calcium chloride as a non-surgical sterilant for male dogs and cats: a history and summary of research. Review of the Alliance for Contraception in dogs and cats, November 2014, 1–18. Available from: [https://static1.squarespace.com/static/60106baf6eaab30c510d352a/t/60821e4e0cb433204656917b/1619140175242/accd\\_caci\\_review-nov2014.pdf](https://static1.squarespace.com/static/60106baf6eaab30c510d352a/t/60821e4e0cb433204656917b/1619140175242/accd_caci_review-nov2014.pdf) [Accessed 22nd July 2023].
- Gontier, A., Youala, M., Fontaine, C., Raibon, E., Fournel, S., Briantais, P. et al. (2022) Efficacy and safety of 4.7 mg deslorelin acetate implants in suppressing oestrus cycle in prepubertal female dogs. *Animals*, **12**, 3504.
- Gonzalez-Gasch, E. & Monnet, E. (2015) Comparison of single port access versus multiple port access systems in elective laparoscopy: 98 dogs (2005–2014). *Veterinary Surgery*, **44**, 895–899.
- Gordon, R. (2016) From pests to pets: social and cultural perceptions of animals in post-medieval urban centres in England (AD1500–1900). *Papers from the Institute of Archaeology*, **27**, 1–9.
- Gorman, S.P., Levy, J.K., Hampton, A.L., Collante, W.R., Harris, A.L. & Brown, R.G. (2002) Evaluation of a porcine zona pellucida vaccine for the immunocontraception of domestic kittens (*Felis catus*). *Theriogenology*, **58**, 135–149.
- Gouletsou, P.G., Galatos, A.D., Apostolidis, K. & Sideri, A.I. (2009) Vaginal fold prolapse during the last third of pregnancy, followed by normal parturition, in a bitch. *Animal Reproduction Science*, **112**, 371–376.
- Graham, L., Swanson, W., Wildt, D. & Brown, J.L. (2004) Influence of oral melatonin on natural and gonadotropin-induced ovarian function in the domestic cat. *Theriogenology*, **61**, 1061–1076.
- Greenfield, C.L., Johnson, A.L. & Schaeffer, D.J. (2004) Frequency of use of various procedures, skills, and areas of knowledge among veterinarians in private small animal exclusive or predominant practice and proficiency expected of new veterinary school graduates. *Journal of the American Veterinary Medical Association*, **224**, 1780–1787.
- Greenlee, P.G. & Patnaik, A.K. (1985) Canine ovarian tumors of germ cell origin. *Veterinary Pathology*, **22**, 117–122.
- Greer, K.A., Canterberry, S.C. & Murphy, K.E. (2007) Statistical analysis regarding the effects of height and weight on life span of the domestic dog. *Research in Veterinary Science*, **82**, 208–214.
- Gregory, S.P., Parkinson, T.J. & Holt, P.E. (1992) Urethral conformation and position in relation to urinary incontinence in the bitch. *Veterinary Record*, **131**, 167–170.
- Grieco, V., Riccardi, E., Greppi, G.F., Teruzzi, F., Iermanò, V. & Finazzi, M. (2008) Canine testicular tumours: a study on 232 dogs. *Journal of Comparative Pathology*, **138**, 86–89.
- Griffin, B., Heath, A., Young, D. & Wright, J. (2001) Effects of melatonin implants on ovarian function in the domestic cat. *Proceedings of the 19th Congress of the American College of Veterinary Internal Medicine (ACVIM)*, Denver, CO, USA.
- Griffin, B., Henry, B., Elizabeth, W., Miller, L. & Fagerstone, K. (2004) Response of dogs to a GnRH-KLH conjugate contraceptive vaccine adjuvanted with adjuvac. *Proceedings of the 2004 ACC&D 2<sup>nd</sup> International Symposium on Surgical Methods for Pet Population Control*, 185–186.
- Griffin, B., Bushby, P.A., McCobb, E., White, S.C., Rigdon-Brestle, Y.K., Appel, L.D. et al. (2016) The association of shelter veterinarians' 2016 veterinary medical care guidelines for spay-neuter programs. *Journal of the American Veterinary Medical Association*, **249**, 165–188.
- Griffin, B., Bohling, M. & Brestle, W. (2020) Tattoo and ear tipping techniques for identification of surgically sterilized dogs and cats. In: White, S. (Ed.) *High-quality-high-volume spay and neuter and other shelter surgeries*. Hoboken, NJ: Wiley-Blackwell, pp. 325–338.
- Griffin, M.A., Culp, W.T.N. & Rebhun, R.B. (2021) Canine and feline haemangiosarcoma. *The Veterinary Record*, **189**, e585.
- Grint, N.J., Murison, P.J., Coe, R.J. & Waterman Pearson, A.E. (2006) Assessment of the influence of surgical technique on postoperative pain and wound tenderness in cats following ovariohysterectomy. *Journal of Feline Medicine and Surgery*, **8**, 15–21.
- Grüntzig, K., Graf, R., Hässig, M., Welle, M., Meier, D., Lott, G. et al. (2015) The Swiss canine cancer registry: a retrospective study on the occurrence of tumours in dogs in Switzerland from 1955 to 2008. *Journal of Comparative Pathology*, **152**, 161–171.
- Grüntzig, K., Graf, R., Boo, G., Guscetti, F., Hässig, M., Axhausen, K.W. et al. (2016) Swiss canine cancer registry 1955–2008: occurrence of the most common tumour diagnoses and influence of age, breed, body size, sex and neutering status on tumour development. *Journal of Comparative Pathology*, **155**, 156–170.
- Guest, K.E., Ellerbrock, R.E., Adams, D.J., Reed, R.A. & Grimes, J.A. (2023) Performing an ovariohysterectomy at the time of c-section does not pose an increase in risk of mortality, intra- or postoperative complications, or decreased mothering ability of the bitch. *Journal of the American Veterinary Medical Association*, **261**, 837–843.
- Gültiken, N., Aslan, S., Ay, S.S., Gülbahar, M.Y., Thuróczy, J., Koldaş, E. et al. (2017) Effect of deslorelin on testicular function, serum dihydrotestosterone and oestradiol concentrations during and after suppression of sexual activity in tom cats. *Journal of Feline Medicine and Surgery*, **19**, 123–131.
- Gunter, L.M., Barber, R.T. & Wynne, C.D. (2018) A canine identity crisis: genetic breed heritage testing of shelter dogs. *PLoS One*, **13**, e0202633.
- Gunther, I., Hawlena, H., Azriel, L. & Klement, E. (2022) Reduction of free-roaming cat population requires high-intensity neutering in spatial contiguity to mitigate compensatory effects. *Proceedings of the National Academy of Sciences*, **119**, e2119000119.
- Gupta, K. (2012) Epidemiological studies on canine mammary tumour and its relevance for breast cancer studies. *IOSR Journal of Pharmacy (IOSRPHR)*, **2**, 322–333.
- Gupta, S.K., Toor, S., Minhas, V., Chaudhary, P., Raman, M., Anoop, S. et al. (2022) Contraceptive efficacy of recombinant porcine zona proteins and fusion protein encompassing canine ZP3 fragment and GnRH in female beagle dogs. *American Journal of Reproductive Immunology*, **87**, e13536.
- Guptill, L., Glickman, L. & Glickman, N. (2003) Time trends and risk factors for diabetes mellitus in dogs: analysis of veterinary medical data base records (1970–1999). *The Veterinary Journal*, **165**, 240–247.
- Haakensen, V.D., Bjørro, T., Lüders, T., Riis, M., Bukholm, I.K., Kristensen, V.N. et al. (2011) Serum estradiol levels associated with specific gene expression patterns in normal breast tissue and in breast carcinomas. *BMC Cancer*, **11**, 332.
- van Hagen, M.A., Ducro, B.J., Broek, J.v. & Knol, B.W. (2005) Incidence, risk factors, and heritability estimates of hind limb lameness caused by hip dysplasia in a birth cohort of boxers. *American Journal of Veterinary Research*, **66**, 307–312.
- Hagman, R. (2018) Pyometra in small animals. *The Veterinary Clinics of North America. Small Animal Practice*, **48**, 639–661.
- Hagman, R. (2022) Pyometra in small animals 2.0. *The Veterinary Clinics of North America. Small Animal Practice*, **52**, 631–657.
- Hagman, R. (2023) Pyometra in small animals 3.0. *The Veterinary Clinics of North America. Small Animal Practice*, **53**, 1223–1254.
- Hagman, R., Ström Holst, B., Möller, L. & Egenvall, A. (2014) Incidence of pyometra in Swedish insured cats. *Theriogenology*, **82**, 114–120.
- Hall, J.L., Owen, L., Riddell, A., Church, D.B., Brodbelt, D.C. & O'Neill, D.G. (2019) Urinary incontinence in male dogs under primary veterinary care in England: prevalence and risk factors. *Journal of Small Animal Practice*, **60**, 86–95.
- Hamilton, K.H., Henderson, E.R., Toscano, M. & Chanoit, G.P. (2014) Comparison of postoperative complications in healthy dogs undergoing open and closed orchidectomy. *Journal of Small Animal Practice*, **55**, 521–526.
- Hancock, R.B., Lanz, O.I., Waldron, D.R., Duncan, R.B., Broadstone, R.V. & Hendrix, P.K. (2005) Comparison of postoperative pain after ovariohysterectomy by harmonic scalpel-assisted laparoscopy compared with median celiotomy and ligation in dogs. *Veterinary Surgery*, **34**, 273–282.
- Handa, R.J. & Weiser, M.J. (2014) Gonadal steroid hormones and the hypothalamo-pituitary-adrenal axis. *Frontiers in Neuroendocrinology*, **35**, 197–220.
- Hanyu, S., Iwanaga, T., Kano, K. & Fujita, T. (1987) Distribution of serotonin-immunoreactive paraneurons in the lower urinary tract of dogs. *The American Journal of Anatomy*, **180**, 349–356.
- Hardie, E.M. & Kyles, A.E. (2004) Management of ureteral obstruction. *Veterinary Clinics of North America: Small Animal Practice*, **34**, 989–1010.
- Harris, T. & Wolchuk, N. (1963) The suppression of estrus in the dog and cat with long-term administration of synthetic progestational steroids. *American Journal of Veterinary Research*, **24**, 1003–1006.
- Hart, B.L. & Cooper, L. (1984) Factors relating to urine spraying and fighting in prepubertally gonadectomized cats. *Journal of the American Veterinary Medical Association*, **184**, 1255–1258.
- Hart, B.L., Hart, L.A., Thigpen, A.P. & Willits, N.H. (2014) Long-term health effects of neutering dogs: comparison of Labrador retrievers with Golden retrievers. *PLoS One*, **9**, e102241.
- Hart, B.L., Hart, L.A., Thigpen, A.P. & Willits, N.H. (2016) Neutering of German shepherd dogs: associated joint disorders, cancers and urinary incontinence. *Veterinary Medicine and Science*, **2**, 191–199.
- Hart, B.L., Hart, L.A., Thigpen, A.P. & Willits, N.H. (2020) Assisting decision-making on age of neutering for 35 breeds of dogs: associated joint disorders, cancers, and urinary incontinence. *Frontiers in Veterinary Science*, **7**, 388.
- Hassan, B.B., Elshafae, S.M., Supsavhad, W., Simmons, J.K., Dirksen, W.P., Sokkar, S.M. et al. (2017) Feline mammary cancer. *Veterinary Pathology*, **54**, 32–43.

- Hawkins, R.D., Williams, J.M. & Animals, S. (2017) Childhood attachment to pets: associations between pet attachment, attitudes to animals, compassion, and humane behaviour. *International Journal of Environmental Research and Public Health*, **14**, 490.
- Hayden, D., Johnston, S., Kiang, D., Johnson, K.H. & Barnes, D.M. (1981) Feline mammary hypertrophy/fibroadenoma complex: clinical and hormonal aspects. *American Journal of Veterinary Research*, **42**, 1699–1703.
- Hayden, D., Barnes, D. & Johnson, K. (1989) Morphologic changes in the mammary gland of megestrol acetate-treated and untreated cats: a retrospective study. *Veterinary Pathology*, **26**, 104–113.
- Hayes, A.A. & Mooney, S. (1985) Feline mammary tumors. *Veterinary Clinics of North America: Small Animal Practice*, **15**, 513–520.
- Hayes, H.M. & Wilson, G.P. (1977) Hormone-dependent neoplasms of the canine perianal gland. *Cancer Research*, **37**, 2068–2071.
- Hayes, H.M. & Young, J.L. (1978) Epidemiologic features of canine ovarian neoplasms. *Gynecologic Oncology*, **6**, 348–353.
- Hayes, H.M., Milne, K.L. & Mandell, C.P. (1981) Epidemiological features of feline mammary carcinoma. *Veterinary Record*, **108**, 476–479.
- Hayes, H.M., Wilson, G.P. & Pendergrass, T.W. (1985) Canine cryptorchidism and subsequent testicular neoplasia: case-control study with epidemiologic update. *Teratology*, **32**, 51–56.
- Hayon, S., Michael, J. & Coward, R.M. (2020) The modern testicular prosthesis: patient selection and counseling, surgical technique, and outcomes. *Asian Journal of Andrology*, **22**, 64.
- Hazenfield, K.M. & Smeak, D.D. (2014) In vitro holding security of six friction knots used as a first throw in the creation of a vascular ligation. *Journal of the American Veterinary Medical Association*, **245**, 571–577.
- Heber, D., Dodson, R., Swerdloff, R., Channabasavaiah, K. & Stewart, J.M. (1982) Pituitary receptor site blockade by a gonadotropin-releasing hormone antagonist in vivo: mechanism of action. *Science*, **216**, 420–421.
- Hedlund, C. (2002) Surgery of the reproductive tract. In: Fossum, T.W. (Ed.) *Small animal surgery*, 2nd edition. Philadelphia, PA: Mosby, pp. 610–673.
- Heidenberger, E. & Unshelm, J. (1990) Verhaltensänderungen von Hunden nach Kastration. *Tierärztliche Praxis*, **18**, 69–75.
- Henderson, W. (1951) Cryptorchidism in the adult cat. *North American Veterinarian*, **32**, 634–636.
- Herbst, K.L. (2003) Gonadotropin-releasing hormone antagonists. *Current Opinion in Pharmacology*, **3**, 660–666.
- Hernandez, F.J., Fernandez, B.B., Chertack, M. & Gage, P.A. (1975) Feline mammary carcinoma and progestogens. *Feline Practice*, **5**, 45–48.
- Herron, M.A. (1972) The effect of prepubertal castration on the penile urethra of the cat. *Journal of the American Veterinary Medical Association*, **160**, 208–211.
- Herron, M. (1983) Tumors of the canine genital system. *Journal of the American Animal Hospital Association*, **19**, 981–994.
- Herron, M.A. & Herron, M.R. (1972) Vasectomy in the cat. *Modern Veterinary Practice*, **53**, 41–43.
- Herron, M.A. & Stern, B. (1980) Prognosis and management of feline infertility. In: Kirk, R.W. (Ed.) *Current veterinary therapy VII*. Philadelphia, PA: WB Saunders, pp. 1231–1235.
- Hinton, M. & Gaskell, C. (1977) Non-neoplastic mammary hypertrophy in the cat associated either with pregnancy or with oral progestagen therapy. *The Veterinary Record*, **100**, 277–280.
- Hoad, J.G. (2018) Spaying bitches: why, when, how? *The Veterinary Nurse*, **9**, 418–421.
- Hobday, F.T.G. (1924) Surgical diseases of the dog and cat, 3rd edition. London: Bailliere, Tindall and Cox.
- Hoffman, J.M., Creevy, K.E. & Promislow, D.E.L. (2013) Reproductive capability is associated with lifespan and cause of death in companion dogs. *PLoS One*, **8**, e61082.
- Hoffman, J.M., Lourenço, B.N., Promislow, D.E.L. & Creevy, K.E. (2018) Canine hyperadrenocorticism associations with signalment, selected comorbidities and mortality within North American veterinary teaching hospitals. *Journal of Small Animal Practice*, **59**, 681–690.
- Hollinshead, F. & Krekeler, N. (2016) Pyometra in the queen: to spay or not to spay? *Journal of Feline Medicine and Surgery*, **18**, 21–33.
- Holst, B.S. (2022) Feline breeding and pregnancy management: what is normal and when to intervene. *Journal of Feline Medicine and Surgery*, **24**, 221–231.
- Holst, B.S. & Nilsson, S. (2023) Age, weight and circulating concentrations of total testosterone are associated with the relative prostatic size in adult intact male dogs. *Theriogenology*, **198**, 356–360.
- Holt, P.E. (1990) Urinary incontinence in dogs and cats. *Veterinary Record*, **127**, 347–350.
- Holt, P.E. & Thrusfield, M.V. (1993) Association in bitches between breed, size, neutering and docking, and acquired urinary incontinence due to incompetence of the urethral sphincter mechanism. *Veterinary Record*, **133**, 177–180.
- Holzer, H.M. (2008) The policy, law and morality of mandatory spay/neuter. *International Society for Animal Rights*, 1–125. Available from: <https://store.payloadz.com/details/784061-other-files-documents-and-forms-the-policy-law-and-morality-of-mandatory-spayneuter.html> [Accessed 22nd July 2023].
- Hopkins, S.G., Schubert, T.A. & Hart, B.L. (1976) Castration of adult male dogs: effects on roaming, aggression, urine marking, and mounting. *Journal of the American Veterinary Medical Association*, **168**, 1108–1110.
- Hornbuckle, W.E., MacCoy, D.M., Allan, G.S. & Gunther, R. (1978) Prostatic disease in the dog. *The Cornell Veterinarian*, **68**, 284–305.
- Horwitz, D.F. (2019) Common feline problem behaviors: urine spraying. *Journal of Feline Medicine and Surgery*, **21**, 209–219.
- Hosgood, G., Hedlund, C.S., Pechman, R.D. & Dean, P.W. (1995) Perineal herniorrhaphy: perioperative data from 100 dogs. *Journal of the American Animal Hospital Association*, **31**, 331–342.
- Houdeshell, J. & Hennessey, P. (1977) Megestrol acetate for control of estrus in the cat. *Veterinary Medicine, Small Animal Clinician: VM, SAC*, **72**, 1013–1017.
- Houlton, J.E. & McGlennen, N.J. (1992) Castration and physeal closure in the cat. *Veterinary Record*, **131**, 466–467.
- Haupt, K.A., Haupt, T.R. & Pond, W.G. (1979) The pig as a model for the study of obesity and of control of food intake: a review. *The Yale Journal of Biology and Medicine*, **52**, 307–329.
- Howard, P.E. & Bjorling, D.E. (1989) The intersexual animal. Associated problems. *Problems in Veterinary Medicine*, **1**, 74–84.
- Howe, L.M. (1997) Short-term results and complications of prepubertal gonadectomy in cats and dogs. *Journal of the American Veterinary Medical Association*, **211**, 57–62.
- Howe, L.M. (2006) Surgical methods of contraception and sterilization. *Theriogenology*, **66**, 500–509.
- Howe, L.M. (2015) Current perspectives on the optimal age to spay/castrate dogs and cats. *Veterinary Medicine (Auckland, N.Z.)*, **6**, 171–180.
- Howe, L.M., Slater, M.R., Boothe, H.W., Hobson, H.P., Fossum, T.W., Spann, A.C. et al. (2000) Long-term outcome of gonadectomy performed at an early age or traditional age in cats. *Journal of the American Veterinary Medical Association*, **217**, 1661–1665.
- Howe, L.M., Slater, M.R., Boothe, H.W., Hobson, H.P., Holcom, J.L. & Spann, A.C. (2001) Long-term outcome of gonadectomy performed at an early age or traditional age in dogs. *Journal of the American Veterinary Medical Association*, **218**, 217–221.
- Hsu, T.H., Huang, J.K., Ho, D.M., Liu, R.S., Chen, M.T. & Chang, L.S. (1993) Role of the spermatic artery in spermatogenesis and sex hormone synthesis. *Archives of Andrology*, **31**, 191–197.
- Hsueh, C., Giuffrida, M., Mayhew, P.D., Case, J.B., Singh, A., Monnet, E. et al. (2018) Evaluation of pet owner preferences for operative sterilization techniques in female dogs within the veterinary community. *Veterinary Surgery*, **47**, 015–025.
- Hughes, A.M., Nelson, R.W., Famula, T.R. & Bannasch, D.L. (2007) Clinical features and heritability of hypoadrenocorticism in Nova Scotia duck tolling retrievers: 25 cases (1994–2006). *Journal of the American Veterinary Medical Association*, **231**, 407–412.
- Immegart, H.M. & Threlfall, W.R. (2000) Evaluation of intratesticular injection of glycerol for nonsurgical sterilization of dogs. *American Journal of Veterinary Research*, **61**, 544–549.
- Isitor, G.N. & Weinman, D.E. (1979) Origin and early development of canine circumanal glands. *American Journal of Veterinary Research*, **40**, 487–492.
- Ismail, H.R.A., Landry, F., Aprikian, A.G. & Chevalier, S. (2002) Androgen ablation promotes neuroendocrine cell differentiation in dog and human prostate. *The Prostate*, **51**, 117–125.
- Itze, L. (2010) Silicon prosthesis Neuticles as a testicle substitution in a dog. *Veterinářství*, **60**, 404–405.
- Iwazaki, E., Lee, A.H., Kruis, A.M., Phungviwatnikul, T., Valentine, H., Arend, L.S. et al. (2022) Effects of a high-protein, high-fiber diet rich in antioxidants and L-carnitine on body weight, body composition, metabolic status, and physical activity levels of cats after spay surgery. *Journal of Animal Science*, **100**, 1–9.
- Jackman, J. & Rowan, A.N. (2007) Free-roaming dogs in developing countries: the benefits of capture, neuter, and return programs. In: Salem, D.J. & Rowan, A.N. (Eds.) *The state of the animals 2007*. Washington, DC: Humane Society Press, pp. 55–78.
- Jacobs, J.A., Coe, J.B., Pearl, D.L., Widowski, T.M. & Niel, L. (2018a) Factors associated with canine resource guarding behaviour in the presence of people: A cross-sectional survey of dog owners. *Preventive Veterinary Medicine*, **161**, 143–153.
- Jacobs, J.A., Coe, J.B., Pearl, D.L., Widowski, T.M. & Niel, L. (2018b) Factors associated with canine resource guarding behaviour in the presence of dogs: A cross-sectional survey of dog owners. *Preventive Veterinary Medicine*, **161**, 134–142.

- Jacobs, T.M., Hoppe, B.R., Poehlmann, C.E., Ferracone, J.D. & Sorenmo, K.U. (2010) Mammary adenocarcinomas in three male cats exposed to medroxyprogesterone acetate (1990–2006). *Journal of Feline Medicine and Surgery*, **12**, 169–174.
- Jagoe, J.A. & Serpell, J.A. (1988) Optimum time for neutering (letter). *The Veterinary Record*, **122**, 447.
- Jana, K. & Samanta, P.K. (2011) Clinical evaluation of non-surgical sterilization of male cats with single intra-testicular injection of calcium chloride. *BMC Veterinary Research*, **7**, 1–16.
- Jana, K., Samanta, P. & Ghosh, D. (2005) Evaluation of single intratesticular injection of calcium chloride for nonsurgical sterilization of male Black Bengal goats (*Capra hircus*): a dose-dependent study. *Animal Reproduction Science*, **86**, 89–108.
- Jänne, O., Kontula, K., Vihko, R., Feil, P.D. & Bardin, C.W. (1978) Progesterone receptor and regulation of progestin action in mammalian tissues. *Medical Biology*, **56**, 225–248.
- Janssens, L.A.A. & Janssens, G.H.R.R. (1991) Bilateral flank ovariectomy in the dog: surgical technique and sequelae in 72 animals. *Journal of Small Animal Practice*, **32**, 249–252.
- Jarvis, S. (2018) Encouraging responsible pet ownership. *The Veterinary Record*, **182**, 389.
- Javaid, D., Ganie, S.Y., Hajam, Y.A. & Reshi, M.S. (2022) CRISPR/Cas9 system: a reliable and facile genome editing tool in modern biology. *Molecular Biology Reports*, **49**, 12133–12150.
- Jergens, A.E. & Shaw, D.P. (1987) Tumors of the canine ovary. *Compendium on Continuing Education for the Practicing Veterinarian*, **9**, 489–495.
- Jessen, L.R., Damborg, P.P., Spohr, A., Goericke-Pesch, S., Langhorn, R., Houser, G. et al. (2019) Antibiotic use guidelines for companion Animal practice, 2nd edition. Frederiksberg: The Danish Small Animal Veterinary Medical Association.
- Jitpean, S., Hagman, R., Ström Holst, B., Höglund, O.V., Pettersson, A. & Egenvall, A. (2012) Breed variations in the incidence of pyometra and mammary tumours in Swedish dogs. *Reproduction in Domestic Animals*, **47**(Supplement 6), 347–350.
- Johnston, S.D. (1986) Pseudopregnancy in the bitch. In: Morrow, D.A. (Ed.) Current therapy in theriogenology, vol. **2**. Philadelphia: Saunders, pp. 490–491.
- Johnston, S.D. (1989) Vaginal prolapse. In: Kirk, R.W. (Ed.) Current veterinary therapy X. Philadelphia: Saunders, pp. 1302–1305.
- Johnston, S.D., Root Kustritz, M.V. & Olson, P.N. (2001) Disorders of the canine prostate. In: Canine and feline theriogenology. Philadelphia: Saunders, pp. 337–356.
- Johnston, S.D., Kustritz, M.V.R. & Olson, P.N.S. (2001a) Canine and feline theriogenology. Philadelphia: W B Saunders, pp. 16–31.
- Johnston, S.D., Kustritz, M.V.R. & Olson, P.N. (2001b) Disorders of canine vagina, vestibule and vulva. In: Canine and feline theriogenology. Philadelphia: Saunders, pp. 225–242.
- Jooné, C.J. & Konovalov, D.A. (2023) The effect of neuter status on longevity in the Rottweiler dog. *Scientific Reports*, **13**, 17845–17851.
- Jordan, A. (1994) Toxicology of depot medroxyprogesterone acetate. *Contraception*, **49**, 189–201.
- Joshua, J.O. (1965) The spaying of bitches. *Veterinary Record*, **77**, 642–647.
- Junaidi, A., Williamson, P., Cummins, J., Martin, G.B., Blackberry, M.A. & Trigg, T.E. (2003) Use of a new drug delivery formulation of the gonadotrophin-releasing hormone analogue Deslorelin for reversible long-term contraception in male dogs. *Reproduction, Fertility and Development*, **15**, 317–322.
- Junaidi, A., Williamson, P., Martin, G., Blackberry, M.A., Cummins, J.M. & Trigg, T.E. (2009a) Dose–response studies for pituitary and testicular function in male dogs treated with the GnRH superagonist, deslorelin. *Reproduction in Domestic Animals*, **44**, 725–734.
- Junaidi, A., Williamson, P.E., Trigg, T.E., Cummins, J.M. & Martin, G.B. (2009b) Morphological study of the effects of the GnRH superagonist deslorelin on the canine testis and prostate gland. *Reproduction in Domestic Animals*, **44**, 757–763.
- Jung, M.J., Moon, Y.C., Cho, I.H., Yeh, J.-Y., Kim, S.-E., Chang, W.-S. et al. (2005) Induction of castration by immunization of male dogs with recombinant gonadotropin-releasing hormone (GnRH)-canine distemper virus (CDV) T helper cell epitope p35. *Journal of Veterinary Science*, **6**, 21–24.
- Jurka, P. & Max, A. (2009) Treatment of fibroadenomatosis in 14 cats with aglepristone – changes in blood parameters and follow-up. *The Veterinary Record*, **165**, 657–660.
- Kamel, C. & McGahan, L. (2011) In: Information, N.C.B. (Ed.) Classification of surgical wounds. Ottawa: Canadian Agency for Drugs and Technologies in Health.
- Kanca, H. & Yaman, C. (2022) Use of a bipolar vessel sealing device in canine orchiectomy. *Reproduction in Domestic Animals*, **57**, 48.
- Kanchuk, M.L., Backus, R.C., Calvert, C.C., Morris, J.G. & Rogers, Q.R. (2002) Neutering induces changes in food intake, body weight, plasma insulin and leptin concentrations in normal and lipoprotein lipase-deficient male cats. *The Journal of Nutrition*, **132**, 1730S–1732S.
- Kawabata, W., Suzuki, T., Moriya, T., Fujimori, K., Naganuma, H., Inoue, S. et al. (2003) Estrogen receptors (alpha and beta) and 17beta-hydroxysteroid dehydrogenase type 1 and 2 in thyroid disorders: possible in situ estrogen synthesis and actions. *Modern Pathology: An Official Journal of the United States and Canadian Academy of Pathology, Inc.*, **16**, 437–444.
- Kaya, D., Aslan, S., Kaya, S. & Kuru, M. (2013) Clinical and endocrine short-term effects of GnRH analogue Deslorelin in Prepubertal bitches: does a “flare-up” occur? *Kafkas Üniversitesi Veteriner Fakültesi Dergisi*, **19**, 299–304.
- Kaya, D., Schäfer-Somi, S., Kurt, B., Kuru, M., Kaya, S., Kaçar, C. et al. (2015) Clinical use of deslorelin implants for the long-term contraception in prepubertal bitches: effects on epiphyseal closure, body development, and time to puberty. *Theriogenology*, **83**, 1147–1153.
- Kempainen, R.J. & Clark, T.P. (1994) Etiopathogenesis of canine hypothyroidism. *Veterinary Clinics of North America: Small Animal Practice*, **24**, 467–476.
- Kengeri, S.S., Maras, A.H., Suckow, C.L., Chiang, E.C. & Waters, D.J. (2013) Exceptional longevity in female Rottweiler dogs is not encumbered by investment in reproduction. *Age (Dordrecht, Netherlands)*, **35**, 2503–2513.
- Kent, M.S., Burton, J.H., Dank, G., Bannasch, D.L. & Rebhun, R.B. (2018) Association of cancer-related mortality, age and gonadectomy in golden retriever dogs at a veterinary academic center (1989–2016). *PLoS One*, **13**, e0192578.
- Keskin, A., Yilmazbas, G., Yilmaz, R., Ozyigit, M.O. & Gumen, A. (2009) Pathological abnormalities after long-term administration of medroxyprogesterone acetate in a queen. *Journal of Feline Medicine and Surgery*, **11**, 518–521.
- Khalaj, A., Bakhtiari, J. & Niasari-Naslaji, A. (2012) Comparison between single and three portal laparoscopic splenectomy in dogs. *BMC Veterinary Research*, **8**, 161.
- Kiefel, C.A. & Kutzler, M.A. (2020) Assessment of luteinizing hormone receptor expression in structural support tissues of canine hip and femorotibial joints. *American Journal of Veterinary Research*, **81**, 565–571.
- Kim, K.S. & Kim, O. (2005) Cystic endometrial hyperplasia and endometritis in a dog following prolonged treatment of medroxyprogesterone acetate. *Journal of Veterinary Science*, **6**, 81–82.
- Kim, H.-H., Yeon, S.-C., Houpt, K.-A., Lee, H.-C., Chang, H.-H. & Lee, H.-J. (2005) Acoustic feature of barks of ovariohysterectomized and intact German shepherd bitches. *The Journal of Veterinary Medical Science*, **67**, 281–285.
- Kim, H.H., Yeon, S.C., Houpt, K.A., Lee, H.C., Chang, H.H. & Lee, H.J. (2006) Effects of ovariohysterectomy on reactivity in German shepherd dogs. *The Veterinary Journal*, **172**, 154–159.
- Kim, J.-H., Graef, A.J., Dickerson, E.B. & Modiano, J.F. (2015) Pathobiology of hemangiosarcoma in dogs: research advances and future perspectives. *Veterinary Sciences*, **2**, 388–405.
- Kim, I.-H., Choi, J.-Y., Hwang, D.-Y. & Kang, H.-G. (2019) Remission of progesterone-induced diabetes mellitus after ovariohysterectomy in an intact female dog. *Journal of Veterinary Clinics*, **36**, 74–77.
- Kirby, F.D. (1980) A technique for castrating the cryptorchid dog or cat. *Veterinary Medicine (London)*, **75**, 632.
- Knapp, D.W., Glickman, N.W., DeNicola, D.B., Bonney, P.L., Lin, T.L. & Glickman, L.T. (2000) Naturally-occurring canine transitional cell carcinoma of the urinary bladder A relevant model of human invasive bladder cancer. *Urologic Oncology*, **5**, 47–59.
- Knol, B.W. & Egberink-Alink, S.T. (1989) Treatment of problem behaviour in dogs and cats by castration and progestagen administration: a review. *The Veterinary Quarterly*, **11**, 102–107.
- Koger, L. (1978) Calcium chloride castration. *Modern Veterinary Practice*, **59**, 119–121.
- Kolata, R.J. & Freeman, L.J. (1999) Access, port placement, and basic endosurgical skills. In: Freeman, L.J. (Ed.) Veterinary endosurgery. St. Louis, MO: Mosby, pp. 44–60.
- Koltveit, A. (1973) Toward more responsible pet ownership. *Journal of the American Veterinary Medical Association*, **162**, 434.
- Körber, H., Wehrend, A., Hoffmann, B. & Goericke-Pesch, S. (2013) The use of Suprelorin® for estrus suppression in the bitch. *Reproductive Biology*, **13**, 30–31.
- Kowaleski, M.P., Boudrieau, R.J. & Pozzi, A. (2018) Stifle joint. In: Johnston, S.A. & Tobias, K.M. (Eds.) Veterinary Surgery: Small Animal, 2nd edition. St. Louis, MO, USA: Elsevier, pp. 1071–1167.
- Kraft, W. (1998) Geriatrics in canine and feline internal medicine. *European Journal of Medical Research*, **3**, 31–41.
- Krawiec, D. & Hefflin, D. (1992) Study of prostatic disease in dogs: 177 cases (1981–1986). *Journal of the American Veterinary Medical Association*, **200**, 1119–1122.



- Krijnen, J.L., Bogdanowicz, J.F., Seldenrijk, C.A., Mulder, P.G. & van der Kwast, T.H. (1997) The prognostic value of neuroendocrine differentiation in adenocarcinoma of the prostate in relation to progression of disease after endocrine therapy. *The Journal of Urology*, **158**, 171–174.
- Kristiansen, V.M., Nødtvedt, A., Breen, A.M., Langeland, M., Teige, J., Goldschmidt, M. et al. (2013) Effect of ovariohysterectomy at the time of tumor removal in dogs with benign mammary tumors and hyperplastic lesions: a randomized controlled clinical trial. *Journal of Veterinary Internal Medicine*, **27**, 935–942.
- Kristiansen, V.M., Peña, L., Díez Córdova, L., Illera, J.C., Skjerve, E., Breen, A.M. et al. (2016) Effect of ovariohysterectomy at the time of tumor removal in dogs with mammary carcinomas: a randomized controlled trial. *Journal of Veterinary Internal Medicine*, **30**, 230–241.
- Krzaczynski, J. (1974) The flank approach to feline ovariohysterectomy (an alternate technique). *Veterinary Medicine, Small Animal Clinician*, **69**, 572–574.
- Krzyżewska-Młodawska, A., Max, A. & Bartyzel, B.J. (2014) Influence of gonadectomy on serum fT4 concentrations in male and female dogs. *Electronic Journal of Polish Agricultural Universities*, **17**, 1.
- Kubinyi, E., Turcsán, B. & Miklósi, Á. (2009) Dog and owner demographic characteristics and dog personality trait associations. *Behavioural Processes*, **81**, 392–401.
- Kudo, T., Kamiie, J., Aihara, N., Doi, M., Sumi, A., Omachi, T. et al. (2019) Malignant Leydig cell tumor in dogs: two cases and a review of the literature. *Journal of Veterinary Diagnostic Investigation: Official Publication of the American Association of Veterinary Laboratory Diagnosticians, Inc.*, **31**, 557–561.
- Kuhne, F. (2012) Kastration von Hunden aus Sicht der Tierverhaltenstherapie. *Tierärztliche Praxis Ausgabe K, Kleintiere/Heimtiere*, **40**, 140–145.
- Kumar, D., Kumar, A., Kumar, P., Yadava, C.L. & Yadav, S.P. (2019) Follicular cyst in bitches. *Journal of Animal Health and Production*, **7**, 38–42.
- Kumar, R.V., Ramakrishna, O. & Sreeraman, R.K. (1995) Leiomyoma uteri in a bitch. *The Canadian Veterinary Journal*, **36**, 185.
- Kustritz, M.V. (1999) Early spay-neuter in the dog and cat. *Veterinary Clinics of North America: Small Animal Practice*, **29**, 935–943, vii.
- Kustritz, M.V.R. (2002) Early spay-neuter: clinical considerations. *Clinical Techniques in Small Animal Practice*, **17**, 124–128.
- Kustritz, M.V.R. (2007) Determining the optimal age for gonadectomy of dogs and cats. *Journal of the American Veterinary Medical Association*, **231**, 1665–1675.
- Kustritz, M.V. & Rudolph, K.D. (2001) Theriogenology question of the month. Functional ovarian remnant containing estrogen-secreting follicles or ovarian remnant containing an estrogen-secreting neoplasm. *Journal of the American Veterinary Medical Association*, **219**, 1065–1066.
- Kutzler, M.A. (2020a) Possible relationship between long-term adverse health effects of gonad-removing surgical sterilization and luteinizing hormone in dogs. *Animals*, **10**, 599.
- Kutzler, M.A. (2020b) Gonad-sparing surgical sterilization in dogs. *Frontiers in Veterinary Science*, **7**, 342.
- Kutzler, M.A. (2023) Understanding the effects of sustained supraphysiologic concentrations of luteinizing hormone in gonadectomized dogs: what we know and what we still need to learn. *Theriogenology*, **196**, 270–274.
- Kutzler, M.V., Moccia, V., Zwida, K. & Löhr, C.V. (2022) Luteinizing hormone receptor expression in neoplastic mast cells is increased in spayed and neutered dogs. *Journal of the American Animal Hospital Association*, **58**, 271–276.
- Kydd, D.M. & Burnie, A.G. (1986) Vaginal neoplasia in the bitch: a review of forty clinical cases. *Journal of Small Animal Practice*, **27**, 255–263.
- L'Abée-Lund, T.M., Heiene, R., Friis, N.F., Ahrens, P. & Sørum, H. (2003) *Mycoplasma canis* and urogenital disease in dogs in Norway. *Veterinary Record*, **153**, 231–235.
- Lacoste, D., Dubé, D., Trudel, C., Bélanger, A. & Labrie, F. (1989) Normal gonadal functions and fertility after 23 months of treatment of prepubertal male and female dogs with the GnRH agonist [D-Trp6, des-Gly-NH210] GnRH ethylamide. *Journal of Andrology*, **10**, 456–465.
- Ladd, A., Tsong, Y.-Y., Walfield, A. & Thau, R. (1994) Development of an antifertility vaccine for pets based on active immunization against luteinizing hormone-releasing hormone. *Biology of Reproduction*, **51**, 1076–1083.
- Lai, C.-L., van den Ham, R., van Leenders, G., van der Lugt, J., Mol, J.A. & Teske, E. (2008) Histopathological and immunohistochemical characterization of canine prostate cancer. *The Prostate*, **68**, 477–488.
- van Lanen, K. & Sande, A. (2014) Canine hypoadrenocorticism: pathogenesis, diagnosis, and treatment. *Topics in Companion Animal Medicine*, **29**, 88–95.
- Lang, S.H., Hyde, C., Reid, I.N., Hitchcock, I.S., Hart, C.A., Bryden, A.A.G. et al. (2002) Enhanced expression of vimentin in motile prostate cell lines and in poorly differentiated and metastatic prostate carcinoma. *The Prostate*, **52**, 253–263.
- Lapshin, A. & Kondratova, I. (2015) Prostatic adenocarcinoma in tomcat. Clinical case report. *Vetpharma*.
- Larsson, B., Åström, G., Einarsson, S., Rydén, L., Granberg-Ohman, I. & Lindhe, B.A. (1981a) The possible risks of a copper and an inert intrauterine device situated in the abdominal cavity: an experimental study in pigs and dogs. *Fertility and Sterility*, **36**, 229–231.
- Larsson, B., Åström, G., Rydén, L., Einarsson, S., Granberg-Ohman, I. & Lindhe, B.A. (1981b) Investigation of the mechanism of perforation of an intrauterine device in pigs and dogs. *Fertility and Sterility*, **36**, 225–228.
- Lauber, B., Molitor, V., Meury, S., Doherr, M.G., Favrot, C., Tengvall, K. et al. (2012) Total IgE and allergen-specific IgE and IgG antibody levels in sera of atopic dermatitis affected and non-affected Labrador- and Golden retrievers. *Veterinary Immunology and Immunopathology*, **149**, 112–118.
- Lawler, D.F., Johnston, S.D., Keltner, D.G., Ballam, J.M., Kealy, R.D., Bunte, T. et al. (1999) Influence of restricted food intake on estrous cycles and pseudopregnancies in dogs. *American Journal of Veterinary Research*, **60**, 820–825.
- Le Roux, P.H. (1983) Thyroid status, oestradiol level, work performance and body mass of ovariectomised bitches and bitches bearing ovarian autotransplants in the stomach wall. *Journal of the South African Veterinary Association*, **54**, 115–117.
- Le Roux, P.H. & Van Der Walt, L.A. (1977) Ovarian autograft as an alternative to ovariectomy in bitches. *Journal of the South African Veterinary Association*, **48**, 117–123.
- Lea, C., Walker, D., Blazquez, C., Zaghloul, O., Tappin, S. & Kelly, D. (2022) Prostatitis and prostatic abscessation in dogs: retrospective study of 82 cases. *Australian Veterinary Journal*, **100**, 223–229.
- Leav, I., Schelling, K.H., Adams, J.Y., Merk, F.B. & Alroy, J. (2001) Role of canine basal cells in postnatal prostatic development, induction of hyperplasia, and sex hormone-stimulated growth; and the ductal origin of carcinoma. *The Prostate*, **48**, 210–224.
- Lefebvre, S.L., Yang, M., Wang, M., Elliott, D.A., Buff, P.R. & Lund, E.M. (2013) Effect of age at gonadectomy on the probability of dogs becoming overweight. *Journal of the American Veterinary Medical Association*, **243**, 236–243.
- Lehner, M. & von Reinhardt, C. (2013) Kastration und Sterilisation beim Hund. Bernau, Germany: Animal Learn Verlag.
- Leidinger, E., Hooijberg, E., Sick, K., Reinelt, B. & Kirtz, G. (2011) Fibroepithelial hyperplasia in an entire male cat: cytologic and histopathological features. *Tierärztliche Praxis. Ausgabe K, Kleintiere/Heimtiere*, **39**, 198–202.
- Leitch, B.J., Bray, J.R., Kim, N.J.G., Cann, B. & Lopez-Vilalobos, N. (2012) Pedicle ligation in ovariohysterectomy: an in vitro study of ligation techniques. *Journal of Small Animal Practice*, **53**, 592–598.
- Lekcharoensuk, C., Osborne, C.A. & Lulich, J.P. (2001) Epidemiologic study of risk factors for lower urinary tract diseases in cats. *Journal of the American Veterinary Medical Association*, **218**, 1429–1435.
- Leoci, R., Aiudi, G., Silvestre, F., Lissner, E.A. & Lacalandra, G.M. (2014a) Alcohol diluent provides the optimal formulation for calcium chloride non-surgical sterilization in dogs. *Acta Veterinaria Scandinavica*, **56**, 1–7.
- Leoci, R., Aiudi, G., Silvestre, F., Lissner, E.A., Marino, F. & Lacalandra, G.M. (2014b) A dose-finding, long-term study on the use of calcium chloride in saline solution as a method of nonsurgical sterilization in dogs: evaluation of the most effective concentration with the lowest risk. *Acta Veterinaria Scandinavica*, **56**, 1–8.
- Leoci, R., Aiudi, G., Silvestre, F., Lissner, E.A., Marino, F. & Lacalandra, G.M. (2015) Therapeutic ultrasound as a potential male dog contraceptive: determination of the most effective application protocol. *Reproduction in Domestic Animals*, **50**, 712–718.
- Leoci, R., Aiudi, G., Cicirelli, V., Brent, L., Iaria, C. & Lacalandra, G.M. (2019) Effects of intratesticular vs intraepididymal calcium chloride sterilant on testicular morphology and fertility in dogs. *Theriogenology*, **127**, 153–160.
- LeRoy, B.E. & Lech, M.E. (2004) Prostatic carcinoma causing urethral obstruction and obstipation in a cat. *Journal of Feline Medicine and Surgery*, **6**, 397–400.
- LeRoy, B.E. & Northrup, N. (2009) Prostate cancer in dogs: comparative and clinical aspects. *The Veterinary Journal*, **180**, 149–162.
- LeRoy, B.E., Sellers, R.S. & Rosol, T.J. (2004) Canine prostate stimulates osteoblast function using the endothelin receptors. *The Prostate*, **59**, 148–156.
- Leslie, T.A., Illing, R.O., McCormick, R., Guillebaud, J. & Cranston, D.W. (2007) The incidence of chronic scrotal pain after vasectomy: a prospective audit. *BJU International*, **100**, 1330–1333.
- Levy, J. (2010) Current contraceptive approaches for feral cats. 4th International Symposium on Non-Surgical Methods of Pet Population Control.
- Levy, J.K., Miller, L.A., Crawford, P.C., Ritchey, J.W., Ross, M.K. & Fagerstone, K.A. (2004) GnRH immunocontraception of male cats. *Theriogenology*, **62**, 1116–1130.
- Levy, J.K., Mansour, M., Crawford, P.C., Pohajdak, B. & Brown, R.G. (2005) Survey of zona pellucida antigens for immunocontraception of cats. *Theriogenology*, **63**, 1334–1341.
- Levy, J.K., Friary, J.A., Miller, L.A., Tucker, S.J. & Fagerstone, K.A. (2011) Long-term fertility control in female cats with GonaCon™, a GnRH immunocontraceptive. *Theriogenology*, **76**, 1517–1525.

- Levy, J., Isaza, N. & Scott, K. (2014) Effect of high-impact targeted trap-neuter-return and adoption of community cats on cat intake to a shelter. *The Veterinary Journal*, **201**, 269–274.
- Lévy, X., Niżański, W., Von Heimendahl, A. & Mimouni, P. (2014) Diagnosis of common prostatic conditions in dogs: an update. *Reproduction in Domestic Animals*, **49**, 50–57.
- Leyva, H., Madley, T. & Stabenfeldt, G. (1989a) Effect of light manipulation on ovarian activity and melatonin and prolactin secretion in the domestic cat. *Journal of Reproduction and Fertility. Supplement*, **39**, 125–133.
- Leyva, H., Madley, T. & Stabenfeldt, G. (1989b) Effect of melatonin on photoperiod responses, ovarian secretion of oestrogen, and coital responses in the domestic cat. *Journal of Reproduction and Fertility. Supplement*, **39**, 135–142.
- Li, P., Boenzli, E., Hofmann-Lehmann, R. & Helfer-Hungerbuehler, A.K. (2019) Pre-existing antibodies to candidate gene therapy vectors (adeno-associated vector serotypes) in domestic cats. *PLoS One*, **14**, e0212811.
- Liao, A.T., Chu, P.Y., Yeh, L.-S., Lin, C.-T. & Liu, C.-H. (2009) A 12-year retrospective study of canine testicular tumors. *The Journal of Veterinary Medical Science*, **71**, 919–923.
- Lincoln, G.A., Johnston, J.D., Andersson, H., Wagner, G. & Hazlerigg, D.G. (2005) Photorefractoriness in mammals: dissociating a seasonal timer from the circadian-based photoperiod response. *Endocrinology*, **146**, 3782–3790.
- Lockwood, R. (1995) The ethology and epidemiology of canine aggression. In: *The domestic dog: its evolution, behavior, and interactions with people*. Cambridge, UK: Cambridge University Press.
- Long, R. (1972) Pyometritis in spayed cats. *The Veterinary Record*, **91**, 105–106.
- Looney, A.L., Bohling, M.W., Bushby, P.A., Howe, L.M., Griffin, B., Levy, J.K. et al. (2008) The Association of Shelter Veterinarians veterinary medical care guidelines for spay-neuter programs. *Journal of the American Veterinary Medical Association*, **233**, 74–86.
- Lopate, C. & Foster, R. (2010) Ovarian disease in the dog: perspectives and treatment options. *Clinical Theriogenology*, **2**, 169–176.
- Lord, L.K., Ingwersen, W., Gray, J.L. & Wintz, D.J. (2009) Characterization of animals with microchips entering animal shelters. *Journal of the American Veterinary Medical Association*, **235**, 160–167.
- Loretto, A.P., da Silva Ilha, M.R., Ordás, J. & de las Mulas, J.M. (2005) Clinical, pathological and immunohistochemical study of feline mammary fibroepithelial hyperplasia following a single injection of depot medroxyprogesterone acetate. *Journal of Feline Medicine and Surgery*, **7**, 43–52.
- Loyd, K.A.T. & DeVore, J.L. (2010) An evaluation of feral cat management options using a decision analysis network. *Ecology and Society*, **15**, 10.
- Lugelo, A., Hampson, K., Ferguson, E.A., Czapryna, A., Bigambo, M., Duamor, C.T. et al. (2022) Development of dog vaccination strategies to maintain herd immunity against rabies. *Viruses*, **14**, 830.
- Lund, E.M., Armstrong, P.J., Kirk, C.A. & Klausner, J.S. (2006) Prevalence and risk factors for obesity in adult dogs from private US veterinary practices. *International Journal of Applied Research in Veterinary Medicine*, **4**, 177.
- Lunn, S.A., Fraser, A., Thompson, A. & Moses, P.A. (2009) Uterine rupture secondary to traumatic mating in a recently spayed bitch. *Australian Veterinary Practitioner*, **39**, 141–143.
- Lutz, K.-M., Hartnack, S. & Reichler, I.M. (2020) Do prevalence rates and severity of acquired urinary incontinence differ between dogs spayed by laparoscopy or laparotomy? Comparing apples with apples with a matched-pair cohort study. *Veterinary Surgery*, **49**(Supplement 1), 0112–0119.
- Maarschalkwerd, R.J., Eendenburg, N., Kirpensteijn, J. & Knol, B.W. (1997) Influence of orchietomy on canine behaviour. *Veterinary Record*, **140**, 617–619.
- MacDougall, L.D. (2003) Mammary fibroadenomatous hyperplasia in a young cat attributed to treatment with megestrol acetate. *The Canadian Veterinary Journal*, **44**, 227.
- MacVean, D.W., Monlux, A.W., Anderson, R.S., Silberg, S.L. & Roszel, J.F. (1978) Frequency of canine and feline tumors in a defined population. *Veterinary Pathology*, **15**, 700–715.
- Macy, D.W., Withrow, S.J. & Hoopes, J. (1983) Transitional cell carcinoma of the bladder associated with cyclophosphamide administration. *Journal of the American Veterinary Medical Association*, **19**, 965–969.
- Madbouly, H., Korany, R., El-Shahat, K., Eissa, H. & Fathi, M. (2021) Efficacy of intratesticular glycerol injection as male cat contraception in comparison with two surgical approaches. *Topics in Companion Animal Medicine*, **42**, 100493.
- Maenhoudt, C., Santos, N., Fontaine, E., Mir, F., Reynaud, K., Navarro, C. et al. (2012) Results of Gn RH agonist implants in oestrous induction and oestrous suppression in bitches and queens. *Reproduction in Domestic Animals*, **47**, 393–397.
- Maenhoudt, C., Santos, N.R. & Fontbonne, A. (2014) Suppression of fertility in adult dogs. *Reproduction in Domestic Animals*, **49**(Supplement 2), 58–63.
- Mahi-Brown, C.A., Huang, T.T., Jr. & Yanagimachi, R. (1982) Infertility in bitches induced by active immunization with porcine zona pellucida. *Journal of Experimental Zoology*, **222**, 89–95.
- Mahi-Brown, C.A., Yanagimachi, R., Nelson, M., Yanagimachi, H. & Palumbo, N. (1988) Ovarian histopathology of bitches immunized with porcine zona pellucida. *American Journal of Reproductive Immunology and Microbiology*, **18**, 94–103.
- Manothaiudom, K. & Johnston, S.D. (1991) Approach to vaginal/vestibular masses in the bitch. *Veterinary Clinics of North America: Small Animal Practice*, **21**, 509–521.
- Mantzias, G., Alonge, S., Faustini, M. & Luconi, G.C. (2017) Assessment of the age for a preventive ultrasonographic examination of the prostate in the dog. *Theriogenology*, **100**, 114–119.
- Mared, M., Catchpole, B., Kämpe, O. & Fall, T. (2012) Evaluation of circulating concentrations of glucose homeostasis biomarkers, progesterone, and growth hormone in healthy elk hounds during anestrus and diestrus. *American Journal of Veterinary Research*, **73**, 242–247.
- Marino, G., Quartuccio, M., Cristarella, S., Nicotina, P.A. & Zanghi, A. (2007) Adenoma of the uterine tube in the bitch: two case reports. *Veterinary Research Communications*, **31**(Supplement 1), 173–175.
- Martin, L., Siliart, B., Dumon, H., Backus, R., Biourge, V. & Nguyen, P. (2001) Leptin, body fat content and energy expenditure in intact and gonadectomized adult cats: a preliminary study. *Journal of Animal Physiology and Animal Nutrition*, **85**, 195–199.
- Masson, S., Medam, T., Raibon, E., Fontaine, C. & Levy, X. (2021) Double-blind, placebo-controlled trial of cyproterone acetate to prevent flare-up effect on dogs implanted with deslorelin. *Frontiers in Veterinary Science*, **8**, 714154.
- Mathon, D.H., Paliere, S., Meynaud-Collard, P., Laysol-Lamour, C., Dulaurent-Ferrieres, A., Colson, A. et al. (2011) Laparoscopic-assisted colopexy and sterilization in male dogs: short-term results and physiologic consequences. *Veterinary Surgery*, **40**, 500–508.
- Matsunami, T. (2022) Laparoscopic ovariohysterectomy for dogs under 5 kg body weight. *Veterinary Surgery*, **51**(Supplement 1), 092–097.
- May, C. (1998) Orthopaedic effects of prepubertal neutering in dogs. *Veterinary Record*, **142**, 71–72.
- Mayayo, S.L., Bo, S. & Pisu, M.C. (2018) Mammary fibroadenomatous hyperplasia in a male cat. *Journal of Feline Medicine and Surgery Open Reports*, **4**, 1–5.
- Mayenco Aquirre, A.M., Garcia Fernandez, P. & Sanchez Muela, M. (1996) Sperm granuloma in the dog: complication of vasectomy. *Journal of Small Animal Practice*, **37**, 392–393.
- Mayhew, P.D. & Brown, D.C. (2007) Comparison of three techniques for ovarian pedicle hemostasis during laparoscopic-assisted ovariohysterectomy. *Veterinary Surgery*, **36**, 541–547.
- McCann, J.P., Altszuler, N., Hampshire, J. & Concannon, P.W. (1987) Growth hormone, insulin, glucose, cortisol, luteinizing hormone, and diabetes in beagle bitches treated with medroxyprogesterone acetate. *European Journal of Endocrinology*, **116**, 73–80.
- McCarthy, R. (2019) Traditional surgical and laparoscopic vasectomy in dogs and cats. *Clinical Theriogenology*, **11**, 243–246.
- McCarthy, R.J., Levine, S.H. & Reed, J.M. (2013) Estimation of effectiveness of three methods of feral cat population control by use of a simulation model. *Journal of the American Veterinary Medical Association*, **243**, 502–511.
- McDonald, R.K. (1989) Urethral prolapse in a Yorkshire terrier. *The Compendium on Continuing Education for the Practicing Veterinarian*, **11**, 682–683.
- McDonald, J.L., Farnworth, M.J. & Clements, J. (2018) Integrating trap-neuter-return campaigns into a social framework: developing long-term positive behavior change toward unowned cats in urban areas. *Frontiers in Veterinary Science*, **258**, 1–10.
- McEntee, K. (1990) Cysts in and around the ovary. In: *Reproductive pathology of domestic mammals*. San Diego, CA: Academic Press, pp. 52–68.
- McEntee, M.C. (2002) Reproductive oncology. *Clinical Techniques in Small Animal Practice*, **17**, 133–149.
- McGrath, H., Hardie, R.J. & Davis, E.D. (2004) The lateral flank approach for ovariohysterectomy in small animals. *Compendium on Continuing Education for the Practicing Veterinarian*, **26**, 922–930.
- McGreevy, P.D., Wilson, B., Starling, M.J. & Serpell, J.A. (2018) Behavioural risks in male dogs with minimal lifetime exposure to gonadal hormones may complicate population-control benefits of desexing. *PLoS One*, **5**, e0196284.
- McNicholas, W.T., Wilkens, B.E., Blevins, W.E., Snyder, P.W., McCabe, G.P., Applewhite, A.A. et al. (2002) Spontaneous femoral capital physeal fractures in adult cats: 26 cases (1996–2001). *Journal of the American Veterinary Medical Association*, **221**, 1731–1736.

- Meakin, L.B., Murrell, J.C., Doran, I.C.P., Knowles, T.G., Tivers, M.S. & Chanoit, G.P.A. (2017) Electrosurgery reduces blood loss and immediate postoperative inflammation compared to cold instruments for midline celiotomy in dogs: a randomized controlled trial. *Veterinary Surgery*, **46**, 515–519.
- Meisl, D., Hubler, M. & Arnold, S. (2003) Der Progesteronantagonist Aglépristone (Alizine) zur Behandlung der fibroepithelialen Hyperplasie der Mamma bei der Katze. *Schweizer Archiv für Tierheilkunde*, **145**, 130–136.
- Mejia, S., Duncan, C., Iodence, A., Monnet, E., Wheeler, R. & Duerr, F. (2020) Evaluation of completeness of resection of the glandular portion of the uterus with hysterectomy in dogs – a pilot study. *Animal Reproduction Science*, **219**, 106527.
- Memon, M.A., Pavletic, M.M. & Kumar, M.S. (1993) Chronic vaginal prolapse during pregnancy in a bitch. *Journal of the American Veterinary Medical Association*, **202**, 295–297.
- Mendes-de-Almeida, F., Faria, M., Landau-Remy, G. & Branco, A.S. (2006) The impact of hysterectomy in an urban colony of domestic cats (*Felis catus* Linnaeus, 1758). *International Journal of Applied Research in Veterinary Medicine*, **4**, 134.
- Mendes-de-Almeida, F., Remy, G.L., Gershony, L.C., Rodrigues, D.P., Chame, M. & Labarthe, N.V. (2011) Reduction of feral cat (*Felis catus* Linnaeus 1758) colony size following hysterectomy of adult female cats. *Journal of Feline Medicine and Surgery*, **13**, 436–440.
- Merlin, T., Cinti, F. & Charlesworth, T.M. (2022) Healthy nonobese bitches maintain acceptable spontaneous ventilation during laparoscopic ovariectomies. *Journal of the American Veterinary Medical Association*, **260**, 1489–1495.
- Meyers-Wallen, V.N. (2012) Gonadal and sex differentiation abnormalities of dogs and cats. *Sexual Development: Genetics, Molecular Biology, Evolution, Endocrinology, Embryology, and Pathology of Sex Determination and Differentiation*, **6**, 46–60.
- Meyers-Wallen, V.N. & Patterson, D.F. (1989) Sexual differentiation and inherited disorders of sexual development in the dog. *Journal of Reproduction and Fertility. Supplement*, **39**, 57–64.
- Michell, A.R. (1999) Longevity of British breeds of dog and its relationships with sex, size, cardiovascular variables and disease. *Veterinary Record*, **145**, 625–629.
- Middleton, D. & Watson, A. (1985) Glucose intolerance in cats given short-term therapies of prednisolone and megestrol acetate. *American Journal of Veterinary Research*, **46**, 2623–2625.
- Middleton, D.J., Watson, A., Howe, C. & Caterson, I.D. (1987) Suppression of cortisol responses to exogenous adrenocorticotrophic hormone, and the occurrence of side effects attributable to glucocorticoid excess, in cats during therapy with megestrol acetate and prednisolone. *Canadian Journal of Veterinary Research*, **51**, 60.
- Mielo, M.R., Amirian, E.S. & Levy, J.K. (2022) Identification of spayed and neutered cats and dogs: veterinary training and compliance with practice guidelines. *The Veterinary Journal*, **285**, 105856.
- Millanta, F., Calandrella, M., Bari, G., Niccolini, M., Vannozzi, I. & Poli, A. (2005) Comparison of steroid receptor expression in normal, dysplastic, and neoplastic canine and feline mammary tissues. *Research in Veterinary Science*, **79**, 225–232.
- Miller, D.M. (1995) Ovarian remnant syndrome in dogs and cats: 46 cases (1988–1992). *Journal of Veterinary Diagnostic Investigation: Official Publication of the American Association of Veterinary Laboratory Diagnosticians, Inc.*, **7**, 572–574.
- Miller, M.A., Ramos-Vara, J.A., Dickerson, M.F., Johnson, G.C., Pace, L.W., Kreeger, J.M. et al. (2003) Uterine neoplasia in 13 cats. *Journal of Veterinary Diagnostic Investigation: Official Publication of the American Association of Veterinary Laboratory Diagnosticians, Inc.*, **15**, 515–522.
- Miller, M.A., Hartnett, S.E. & Ramos-Vara, J.A. (2007) Interstitial cell tumor and Sertoli cell tumor in the testis of a cat. *Veterinary Pathology*, **44**, 394–397.
- Miller, G.S., Slater, M.R. & Weiss, E. (2014) Effects of a geographically-targeted intervention and creative outreach to reduce shelter intake in Portland, Oregon. *Open Journal of Animal Sciences*, **4**, 165–174.
- Miller, K.P., Rekers, W.L., DeTar, L.G., Blanchette, J.M. & Milovancev, M. (2018) Evaluation of sutureless scrotal castration for pediatric and juvenile dogs. *Journal of the American Veterinary Medical Association*, **253**, 1589–1593.
- Millis, D.L., Hauptman, J.G. & Johnson, C.A. (1992) Cryptorchidism and monorchidism in cats: 25 cases. *Journal of the American Veterinary Medical Association*, **200**, 1128–1130.
- Milne, K.L. & Hayes, H.M. (1981) Epidemiologic features of canine hypothyroidism. *The Cornell Veterinarian*, **71**, 3–14.
- Mirosevich, J., Bentel, J.M., Zeps, N., Redmond, S.L., D'Antuono, M.F. & Dawkins, H.J. (1999) Androgen receptor expression of proliferating basal and luminal cells in adult murine ventral prostate. *The Journal of Endocrinology*, **162**, 341–350.
- Misdorp, W. (1988) Canine mammary tumours: protective effect of late ovariectomy and stimulating effect of progestins. *The Veterinary Quarterly*, **10**, 26–33.
- Misdorp, W. (2004) Mast cells and canine mast cell tumours. A review. *The Veterinary Quarterly*, **26**, 156–169.
- Misdorp, W., Romijn, A. & Hart, A.A. (1991) Feline mammary tumors: a case-control study of hormonal factors. *Anticancer Research*, **11**, 1793–1797.
- Modiano, J.F., Kokai, Y., Weiner, D.B., Pykett, M.J., Nowell, P.C. & Lyttle, C.R. (1991) Progesterone augments proliferation induced by epidermal growth factor in a feline mammary adenocarcinoma cell line. *Journal of Cellular Biochemistry*, **45**, 196–206.
- Mohammed, S.I., Utturkar, S., Lee, M., Yang, H.H., Cui, Z., Lanman, N.A. et al. (2020) Ductal carcinoma in situ progression in dog model of breast cancer. *Cancers*, **12**, 418.
- Mohr, A., Lüder Ripoli, F., Hammer, S.C., Willenbrock, S., Hewicker-Trautwein, M., Kielbowicz, Z. et al. (2016) Hormone receptor expression analyses in neoplastic and non-neoplastic canine mammary tissue by a bead based multiplex branched DNA assay: a gene expression study in fresh frozen and formalin-fixed, paraffin-embedded samples. *PLoS one*, **11**, e0163311.
- Moise, N. & Reimers, T. (1983) Insulin therapy in cats with diabetes mellitus. *Journal of the American Veterinary Medical Association*, **182**, 158–164.
- Mol, J.A., van Garderen, E., Rutteman, G.R. & Rijnberk, A. (1996) New insights in the molecular mechanism of progestin-induced proliferation of mammary epithelium: induction of the local biosynthesis of growth hormone (GH) in the mammary glands of dogs, cats and humans. *The Journal of Steroid Biochemistry and Molecular Biology*, **57**, 67–71.
- Montoya, M., Morrison, J.A., Arrignon, F., Spofford, N., Charles, H., Hours, M.-A. et al. (2023) Life expectancy tables for dogs and cats derived from clinical data. *Frontiers in Veterinary Science*, **10**, 1082102.
- Moore, G.E., Burkman, K.D., Carter, M.N. & Peterson, M.R. (2001) Causes of death or reasons for euthanasia in military working dogs: 927 cases (1993–1996). *Journal of the American Veterinary Medical Association*, **219**, 209–214.
- Morey, K.L. (2006) Acute peritonitis secondary to traumatic breeding in the bitch. *Journal of Veterinary Emergency and Critical Care*, **16**, 128–130.
- Morrison, S., Singh, A., Rousseau, J. & Weese, J.S. (2016) Adherence of methicillin-resistant *Staphylococcus pseudintermedius* to suture materials commonly used in small animal surgery. *American Journal of Veterinary Research*, **77**, 194–198.
- Moseby, K., Peacock, D. & Read, J. (2015) Catastrophic cat predation: a call for predator profiling in wildlife protection programs. *Biological Conservation*, **191**, 331–340.
- Moulton, J.E., Taylor, D.O.N., Dorn, C.R. & Andersen, A.C. (1970) Canine mammary tumors. *Veterinary Pathology*, **7**, 289–320.
- Moxon, R., Whiteside, H. & England, G.C.W. (2016) Prevalence of ultrasound-determined cystic endometrial hyperplasia and the relationship with age in dogs. *Theriogenology*, **86**, 976–980.
- Moxon, R., Freeman, S., Payne, R., Corr, S. & England, G.C.W. (2022) A prospective cohort study investigating the behavioural development of bitches in a guide dog training programme neutered prepubertally or post-pubertally. *Frontiers in Veterinary Science*, **9**, 902775.
- Moxon, R., Freeman, S.L., Payne, R., Corr, S. & England, G.C.W. (2023) Effect of neutering timing in relation to puberty on female dog behaviour—a scoping review. *The Veterinary Record*, **193**, e2882.
- Munif, M.R., Safawat, M.S. & Hannan, A. (2022) Left lateral flank approach for spaying in cats. *Open Veterinary Journal*, **12**, 540–550.
- Munson, L., Bauman, J., Asa, C., Jöchle, W. & Trigg, T.E. (2001) Efficacy of the GnRH analogue deslorelin for suppression of oestrous cycles in cats. *Journal of Reproduction and Fertility. Supplement*, **57**, 269–273.
- Murakami, Y., Uchida, K., Yamaguchi, R. & Tateyama, S. (2001) Diffuse bilateral hemangiosarcoma of the uterus in a dog. *The Journal of Veterinary Medical Science*, **63**, 191–193.
- Muraro, L. & White, R.S. (2014) Complications of ovariohysterectomy procedures performed in 1880 dogs. *Tierärztliche Praxis Ausgabe K Kleintiere Heimtiere*, **42**, 297–302.
- Murray, J., Skillings, E. & Gruffydd-Jones, T. (2008) Opinions of veterinarians about the age at which kittens should be neutered. *Veterinary Record*, **163**, 381–385.
- Mutsaers, A.J., Widmer, W.R. & Knapp, D.W. (2003) Canine transitional cell carcinoma. *Journal of Veterinary Internal Medicine*, **17**, 136.
- Nascimento, C. & Ferreira, F. (2021) Tumor microenvironment of human breast cancer, and feline mammary carcinoma as a potential study model. *Biochimica et Biophysica Acta. Reviews on Cancer*, **1876**, 188587.
- Neilson, J.C., Eckstein, R.A. & Hart, B.L. (1997) Effects of castration on problem behaviors in male dogs with reference to age and duration of behavior. *Journal of the American Veterinary Medical Association*, **211**, 180–182.



- Nelson, L., Weikel, J., Jr. & Reno, F. (1973) Mammary nodules in dogs during four years' treatment with megestrol acetate or chlormadinone acetate. *Journal of the National Cancer Institute*, **51**, 1303–1311.
- Newell, S.M., Mahaffey, M.B., Binhazim, A. & Greene, C.E. (1992) Paraprostatic cyst in a cat. *Journal of Small Animal Practice*, **33**, 399–401.
- Newman, R.H. (1979) Pyometra and a Sertoli cell tumor in a hermaphroditic dog. *Veterinary Medicine, Small Animal Clinician: VM, SAC*, **74**, 1757.
- Nguyen, P.G., Dumon, H.J., Siliart, B.S., Martin, L.J., Sergheraert, R. & Biourge, V.C. (2004) Effects of dietary fat and energy on body weight and composition after gonadectomy in cats. *American Journal of Veterinary Research*, **65**, 1708–1713.
- Niaz, K., Maqbool, F., Khan, F., Hassan, F.I., Momtaz, S. & Abdollahi, M. (2018) Comparative occurrence of diabetes in canine, feline, and few wild animals and their association with pancreatic diseases and ketoacidosis with therapeutic approach. *Veterinary World*, **11**, 410–422.
- Nielsen, S.W., Misdorp, W. & McEntee, K. (1976) Tumours of the ovary. *Bulletin of the World Health Organization*, **53**, 203–215.
- Nieves, M.A., Hartwig, P., Kinyon, J.M. & Riedesel, D.H. (1997) Bacterial isolates from plaque and from blood during and after routine dental procedures in dogs. *Veterinary Surgery*, **26**, 26–32.
- Nizański, W., Levy, X., Ochota, M. & Pasikowska, J. (2014) Pharmacological treatment for common prostatic conditions in dogs – benign prostatic hyperplasia and prostatitis: an update. *Reproduction in Domestic Animals*, **49**(Supplement 2), 8–15.
- Nizański, W., Ochota, M., Fontaine, C. & Pasikowska, J. (2020) Comparison of clinical effectiveness of deslorelin acetate and osaterone acetate in dogs with benign prostatic hyperplasia. *Animals*, **10**, 1936.
- Noakes, D.E., Dhaliwal, G.K. & England, G.C. (2001) Cystic endometrial hyperplasia/pyometra in dogs: a review of the causes and pathogenesis. *Journal of Reproduction and Fertility. Supplement*, **57**, 395–406.
- Nogales, M., Vidal, E., Medina, F.M., Bonnaud, E., Tershy, B., Campbell, K.J. et al. (2013) Feral cats and biodiversity conservation: the urgent prioritization of Island management. *Bioscience*, **63**, 804–810.
- Norrdin, R.W. & Baum, A.C. (1970) A male pseudohermaphrodite dog with a Sertoli's cell tumor, mucometra, and vaginal glands. *Journal of the American Veterinary Medical Association*, **156**, 204–207.
- Norris, H.J., Garner, F.M. & Taylor, H.B. (1969) Pathology of feline ovarian neoplasms. *The Journal of Pathology*, **97**, 138–143.
- Norris, H.J., Garner, F.M. & Taylor, H.B. (1970) Comparative pathology of ovarian neoplasms. IV. Gonadal stromal tumours of canine species. *Journal of Comparative Pathology*, **80**, 399–405.
- Norris, A.M., Laing, E.J., Valli, V.E., Withrow, S.J., Macy, D.W., Ogilvie, G.K. et al. (1992) Canine bladder and urethral tumors: a retrospective study of 115 cases (1980–1985). *Journal of Veterinary Internal Medicine*, **6**, 145–153.
- Norsworthy, G.D. (1975) Alternative surgical procedures for feline birth control. *Feline Practice*, 24–27.
- Notari, L., Cannas, S., Di Sotto, Y.A. & Palestini, C. (2020) A retrospective analysis of dog–dog and dog–human cases of aggression in northern Italy. *Animals*, **10**, 1662.
- Novak, S., Yakobson, B., Sorek, S., Morgan, L., Tal, S., Nivy, R. et al. (2021) Short term safety, immunogenicity, and reproductive effects of combined vaccination with anti-GnRH (Gonagon) and rabies vaccines in female feral cats. *Frontiers in Veterinary Science*, **8**, 650291.
- Novotny, R., Cizek, P., Vitasek, R., Bartoskova, A., Prinosilova, P. & Janosovska, M. (2012) Reversible suppression of sexual activity in tomcats with deslorelin implant. *Theriogenology*, **78**, 848–857.
- Novotny, R., Vitasek, R., Bartoskova, A., Cizek, P., Prinosilova, P. & Novakova, K. (2015) Azoospermia with variable testicular histology after 7 months of treatment with a deslorelin implant in toms. *Theriogenology*, **83**, 1188–1193.
- Nueangphuet, P., Tanabe, M., Izzati, U.Z., Fuke, N., Hirai, T. & Yamaguchi, R. (2022) Adenomyomatous uterine polyp in a miniature pinscher: histologic, immunohistochemical, and clinical aspects. *Journal of Veterinary Diagnostic Investigation: Official Publication of the American Association of Veterinary Laboratory Diagnosticians, Inc*, **34**, 102–106.
- Nuñez-Favre, R., Bonaure, M., Tittarelli, C., Mansilla-Hermann, D., de la Sota, R.L. & Stornelli, M.A. (2012) Effect of natural photoperiod on epididymal sperm quality and testosterone serum concentration in domestic cat (*Felis silvestris catus*). *Reproduction in Domestic Animals*, **47**, 232–234.
- Nuñez-Favre, R., Bonaure, M.C., Praderio, R., Stornelli, M.C., de la Sota, R.L. & Stornelli, M.A. (2014) Effect of melatonin implants on spermatogenesis in the domestic cat (*Felis silvestris catus*). *Theriogenology*, **82**, 851–856.
- Oberbauer, A.M., Benemann, K.S., Belanger, J.M., Wagner, D.R., Ward, J.H. & Famula, T.R. (2002) Inheritance of hypoadrenocorticism in bearded collies. *American Journal of Veterinary Research*, **63**, 643–647.
- Ochoa, J.S., Favre, R.N., García, M.F., Stornelli, M.C., Sangache, W.C., Rearte, R. et al. (2023) Immunoneutralization of male domestic cats using GnRH vaccine Improvac. *Theriogenology*, **198**, 211–216.
- O'Connell, K. & Thomson, M. (2013) Evaluation of prognostic indicators in dogs with multiple, simultaneously occurring cutaneous mast cell tumours: 63 cases. *Veterinary and Comparative Oncology*, **11**, 51–62.
- Oen, E. (1977) The oral administration of megestrol acetate to postpone oestrus in cats. *Nordisk Veterinaermedicin*, **29**, 287–291.
- O'Farrell, V. & Peachey, E. (1990) Behavioural effects of ovariohysterectomy on bitches. *Journal of Small Animal Practice*, **31**, 595–598.
- Okkens, A., Kooistra, H. & Nickel, R. (1997) Comparison of long-term effects of ovariectomy versus ovariohysterectomy in bitches. *Journal of Reproduction and Fertility. Supplements*, **51**, 227–232.
- Oliveira, E., Fagundes, A., Melo, C., Nery, L.T.B., Rêvored, R.G., Andrade, T.F.G. et al. (2013) Intratesticular injection of a zinc-based solution for contraception of domestic cats: a randomized clinical trial of efficacy and safety. *The Veterinary Journal*, **197**, 307–310.
- Oliveira, M.Rd., Barni, B.S., Heinen Schuster, L.A., Gerardi, D.G., Contesini, E.A., Alievi, M.M. et al. (2019) Feline prostatic carcinoma. *Acta Scientiae Veterinariae*, **47**, 1–7.
- Oliveira, L.C., Fernandes, M.E.D.S.L., Peixoto, A.J.R., da Camara Barros, F.F.P., Coelho, C.M.M., de Assunção Nogueira, V. et al. (2022) Clinical, epidemiological, and histopathological aspects of breast cancer in female dogs at Federal Rural University of Rio de Janeiro Veterinary Hospital. *Brazilian Journal of Veterinary Medicine*, **44**, e000722.
- Oliveira-Martins, M., Portugal, M., Cardoso, L. & Martins-Bessa, A. (2023) The impact of pediatric neutering in dogs and cats – a retrospective study. *Animals*, **13**, 2487.
- Olson, P.N., Nett, T.M. & Bowen, R.A. (1986) A need for sterilization, contraceptives, and abortifacients: abandoned and unwanted pets. I. Current methods of sterilizing pets. *Compendium on Continuing Education for the Practising Veterinarian*, **8**, 87–92.
- Olson, P.N., Root-Kustritz, M.V. & Johnston, S.D. (2001) Early-age neutering of dogs and cats in the United States (a review). *Journal of Reproduction and Fertility*, **57**, 223–232.
- O'Neill, D.G., Church, D.B., McGreevy, P.D., Thomson, P.C. & Brodbelt, D.C. (2013) Longevity and mortality of owned dogs in England. *Veterinary Journal (London, England: 1997)*, **198**, 638–643.
- O'Neill, D.G., Scudder, C., Faire, J.M., Church, D.B., McGreevy, P.D., Thomson, P.C. et al. (2016) Epidemiology of hyperadrenocorticism among 210,824 dogs attending primary-care veterinary practices in the UK from 2009 to 2014. *Journal of Small Animal Practice*, **57**, 365–373.
- O'Neill, D.G., Riddell, A., Church, D.B., Owen, L., Brodbelt, D.C. & Hall, J.L. (2017) Urinary incontinence in bitches under primary veterinary care in England: prevalence and risk factors. *Journal of Small Animal Practice*, **58**, 685–693.
- Orhan, U. (1972) Pyometritis in spayed cats. *The Veterinary Record*, **91**, 77.
- Orr, B. & Jones, B. (2019) A survey of veterinarian attitudes toward prepubertal desexing of dogs and cats in the Australian Capital Territory. *Frontiers in Veterinary Science*, **6**, 272.
- Osborne, C.A. & Sanderson, S.L. (1995) Medical management of urethral prolapse in male dogs. In: Kirk's current veterinary therapy XII, small animal practice. London: IntechOpen Limited, pp. 1027–1029.
- Overall, K.L. & Love, M. (2001) Dog bites to humans – demography, epidemiology, injury, and risk. *Journal of the American Veterinary Medical Association*, **218**, 1923–1934.
- Overley, B., Shofer, F.S., Goldschmidt, M.H., Sherer, D. & Sorenmo, K.U. (2005) Association between ovariohysterectomy and feline mammary carcinoma. *Journal of Veterinary Internal Medicine*, **19**, 560.
- Padley, R.J., Dixon, D.B. & Wu-Wong, J.R. (2002) Effect of castration on endothelin receptors. *Clinical Science (London, England: 1979)*, **103**(Supplement 48), 442S–445S.
- Palerm, J.-S., Mazepa, A., Hutchins, R.G., Ziglioli, V. & Vaden, S.L. (2017) Clinical response and side effects associated with testosterone cypionate for urinary incontinence in male dogs. *Journal of the American Animal Hospital Association*, **53**, 285–290.
- Palerm, J.-S., Zellner, E., Leonard, S., Viall, A.K. & Berger, D.J. (2021) Characterization of recessed vulvas in dogs. *Journal of the American Veterinary Medical Association*, **259**, 744–748.

- Palestrini, C., Mazzola, S.M., Caione, B., Groppetti, D., Pecile, A.M., Minero, M. et al. (2021) Influence of gonadectomy on canine behavior. *Animals*, **11**, 553.
- Palm, J. & Reichler, I.M. (2012) Der Einsatz von Deslorelinazetat (Suprelorin®) in der Kleintiermedizin. *Schweizer Archiv für Tierheilkunde*, **154**, 7–12.
- Palmieri, C., Fonseca-Alves, C.E. & Laufer-Amorim, R. (2022) A review on canine and feline prostate pathology. *Frontiers in Veterinary Science*, **9**, 881232.
- Panciera, D.L. (1994) Hypothyroidism in dogs: 66 cases (1987–1992). *Journal of the American Veterinary Medical Association*, **204**, 761–767.
- Panciera, D.L., Thomas, C.B., Eicker, S.W. & Atkins, C.E. (1990) Epizootologic patterns of diabetes mellitus in cats: 333 cases (1980–1986). *Journal of the American Veterinary Medical Association*, **197**, 1504–1508.
- Paramo, R., Renton, J., Ferguson, J. & Concannon, P.W. (1993) Effects of medroxyprogesterone acetate or gonadotrophin-releasing hormone agonist on suppression of spermatogenesis in the dog (*Canis familiaris*). *Journal of Reproduction and Fertility. Supplement*, **47**, 387–397.
- Park, M.-S., Kim, Y., Kang, M.-S., Oh, S.-Y., Cho, D.-Y., Shin, N.-S. et al. (2006) Disseminated transmissible venereal tumor in a dog. *Journal of Veterinary Diagnostic Investigation: Official Publication of the American Association of Veterinary Laboratory Diagnosticians, Inc.*, **18**, 130–133.
- Parker, K. & Snead, E. (2014) Atypical presentation of ovarian remnant syndrome in a dog. *Journal of the American Animal Hospital Association*, **50**, e1–e5.
- Parlier, M., Thomson, C.B., Rendahl, A., Strelchik, A., Baldo, C., Eckman, S.K. et al. (2024) Prospective, randomized, clinical trial on the effects of laparoscopic insufflation pressures on portal pressures in dogs. *Veterinary Surgery*, **53**, 613–619.
- Pastor, N., Caballé, N.C., Santella, M., Ezquerro, L.J., Tarazona, R. & Duran, E. (2018) Epidemiological study of canine mammary tumors: age, breed, size and malignancy. *Australian Journal of Veterinary Sciences*, **50**, 143–147.
- Patnaik, A.K. & Greenlee, P.G. (1987) Canine ovarian neoplasms: a clinicopathologic study of 71 cases, including histology of 12 granulosa cell tumors. *Veterinary Pathology*, **24**, 509–514.
- Payan-Carreira, R. (2013) Feline mammary fibroepithelial hyperplasia: a clinical approach. In: Payan-Carreira, R. (Ed.) *Insights from veterinary medicine*, 1st edition. London: IntechOpen Limited, pp. 215–232. Available from: <https://doi.org/10.5772/55550>
- Payne-Johnson, C.E., Kelly, D.F. & Davies, R.T. (1986) Endometrial carcinoma in a young dog. *Journal of Comparative Pathology*, **96**, 463–467.
- Pearson, H. (1973) The complications of ovariohysterectomy in the bitch. *Journal of Small Animal Practice*, **14**, 257–266.
- Pecile, A., Groppetti, D., Pizzi, G., Banco, B., Bronzo, V., Giudice, C. et al. (2021) Immunohistochemical insights into a hidden pathology: canine cryptorchidism. *Theriogenology*, **176**, 43–53.
- Pegram, C., Brodbelt, D.C., Church, D.B., Hall, J., Owen, L., Chang, Y.-M. et al. (2019) Associations between neutering and early-onset urinary incontinence in UK bitches under primary veterinary care. *Journal of Small Animal Practice*, **60**, 723–733.
- Pegram, C., Raffan, E., White, E., Ashworth, A.H., Brodbelt, D.C., Church, D.B. et al. (2021) Frequency, breed predisposition and demographic risk factors for overweight status in dogs in the UK. *Journal of Small Animal Practice*, **62**, 521–530.
- Pelican, K., Brown, J., Wildt, D., Ottinger, M.A. & Howard, J.G. (2005) Short term suppression of follicular recruitment and spontaneous ovulation in the cat using levonorgestrel versus a GnRH antagonist. *General and Comparative Endocrinology*, **144**, 110–121.
- Pena, F.J., Gines, J.A., Duque, J., Vieitez, V., Martínez-Pérez, R., Madejón, L. et al. (2006) Endometrial adenocarcinoma and mucometra in a 6-year-old Alaska malamute dog. *Reproduction in Domestic Animals*, **41**, 189–190.
- Pendergrass, T.W. & Hays, H.M. (1975) Cryptorchidism and related defects in dogs: epidemiologic comparisons with man. *Teratology*, **12**, 51–55.
- Percival, A., Singh, A., Zur Linden, R.A., Watrous, G., Patten, S., Valverde, A. et al. (2018) Massive uterine lipoleiomyoma and leiomyoma in a miniature poodle bitch. *The Canadian Veterinary Journal*, **59**, 845–850.
- Pérez Alenza, D., Rutteman, G.R., Peña, L., Beynen, A.C. & Cuesta, P. (1998) Relation between habitual diet and canine mammary tumors in a case-control study. *Journal of Veterinary Internal Medicine*, **12**, 132–139.
- Pérez-Alenza, M.D., Jiménez, A., Nieto, A.I. & Peña, L. (2004) First description of feline inflammatory mammary carcinoma: clinicopathological and immunohistochemical characteristics of three cases. *Breast Cancer Research*, **6**, R300–R307.
- Perez-Marin, C.C., Lopez, R., Dominguez, J.M. & Zafra, R. (2006) Clinical and pathological findings in testis, epididymis, deferens duct and prostate following vasectomy in a dog. *Reproduction in Domestic Animals*, **41**, 169–174.
- Pessina, P., Castillo, V., Araújo, M., Carriquiry, M. & Meikle, A. (2012) Expression of thyroid-specific transcription factors in thyroid carcinoma, contralateral thyroid lobe and healthy thyroid gland in dogs. *Research in Veterinary Science*, **93**, 108–113.
- Pesteanu-Somogyi, L.D., Radzai, C. & Pressler, B.M. (2006) Prevalence of feline infectious peritonitis in specific cat breeds. *Journal of Feline Medicine and Surgery*, **8**, 1–5.
- PETA. (2023) Euthanasia. In: People for the ethical treatment of animals. Available from: <https://www.peta.org/issues/animal-companion-issues/overpopulation/euthanasia/> [Accessed 22nd July 2023].
- Peterson, M. (1987) Effects of megestrol acetate on glucose tolerance and growth hormone secretion in the cat. *Research in Veterinary Science*, **42**, 354–357.
- Peterson, M.E., Kintzler, R.P. & Kass, P.H. (1996) Pretreatment clinical and laboratory findings in dogs with hypoadrenocorticism: 225 cases (1979–1993). *Journal of the American Veterinary Medical Association*, **208**, 85–91.
- Peycke, L.E. (2015) Facilitation of soft tissue surgery: surgical staplers and vessel sealing devices. *Veterinary Clinics of North America: Small Animal Practice*, **45**, 451–461.
- Philibert, J.C., Snyder, P.W., Glickman, N., Glickman, L.T., Knapp, D.W. & Waters, D.J. (2003) Influence of host factors on survival in dogs with malignant mammary gland tumors. *Journal of Veterinary Internal Medicine*, **17**, 102–106.
- Pickard Price, P., Stell, A., O'Neill, D., Church, D. & Brodbelt, D. (2023) Epidemiology and risk factors for mammary tumours in female cats. *Journal of Small Animal Practice*, **64**, 313–320.
- Pineda, M. & Dooley, M.P. (1984) Surgical and chemical vasectomy in the cat. *American Journal of Veterinary Research*, **45**, 291–300.
- Pineda, M.H., Reimers, T.J. & Faulkner, L.C. (1976) Disappearance of spermatozoa from the ejaculates of vasectomized dogs. *Journal of the American Veterinary Medical Association*, **168**, 502–503.
- Pineda, M., Reimers, T., Faulkner, L., Hopwood, M.L. & Seidel, G.E., Jr. (1977) Azoospermia in dogs induced by injection of sclerosing agents into the caudae of the epididymides. *American Journal of Veterinary Research*, **38**, 831–838.
- Pires, M.A., Seixas, F., Palmeira, C. & Payan-Carreira, R. (2010) Histopathologic and immunohistochemical exam in one case of canine endometrial adenocarcinoma. *Reproduction in Domestic Animals*, **45**, 545–549.
- Pisani, G., Millanta, F., Lorenzi, D., Vannozzi, I. & Poli, A. (2006) Androgen receptor expression in normal, hyperplastic and neoplastic hepatoid glands in the dog. *Research in Veterinary Science*, **81**, 231–236.
- Plater, B.L. & Lipscomb, V.J. (2020) Treatment and outcomes of ureter injuries due to ovariohysterectomy complications in cats and dogs. *Journal of Small Animal Practice*, **61**, 170–176.
- Polisca, A., Orlandi, R., Troisi, A., Brecchia, G., Zerani, M., Boiti, C. et al. (2013) Clinical efficacy of the GnRH agonist (deslorelin) in dogs affected by benign prostatic hyperplasia and evaluation of prostatic blood flow by Doppler ultrasound. *Reproduction in Domestic Animals*, **48**, 673–680.
- Polisca, A., Troisi, A., Fontaine, E., Menchetti, L. & Fontbonne, A. (2016) A retrospective study of canine prostatic diseases from 2002 to 2009 at the Alfort Veterinary College in France. *Theriogenology*, **85**, 835–840.
- Pöppel, A.G., Lopes, J.L.X., Nogueira, T.B., da Silva, D.I. & Machado, B.d.S. (2024) Progesterone-related diabetes mellitus in the bitch: current knowledge, the role of pyometra, and relevance in practice. *Animals*, **14**, 890.
- Pöppel, A.G., Mottin, T.S. & González, F.H.D. (2013) Diabetes mellitus remission after resolution of inflammatory and progesterone-related conditions in bitches. *Research in Veterinary Science*, **94**, 471–473.
- Porters, N., Polis, I., Moons, C.P.H., Van de Maele, I., Ducatelle, R., Goethals, K. et al. (2015) Relationship between age at gonadectomy and health problems in kittens adopted from shelters. *The Veterinary Record*, **176**, 572.
- Post, K., van Haaften, B. & Okkens, A.C. (1991) Vaginal hyperplasia in the bitch: literature review and commentary. *The Canadian Veterinary Journal*, **32**, 35–37.
- Power, S.C., Eggleton, K.E., Aaron, A.J., Holt, P.E. & Cripps, P.J. (1998) Urethral sphincter mechanism incompetence in the male dog: importance of bladder neck position, proximal urethral length and castration. *Journal of Small Animal Practice*, **39**, 69–72.
- Prener, A., Engholm, G. & Jensen, O.M. (1996) Genital anomalies and risk for testicular cancer in Danish men. *Epidemiology*, **7**, 14–19.
- Priester, W.A. (1979) Occurrence of mammary neoplasms in bitches in relation to breed, age, tumour type, and geographical region from which reported. *Journal of Small Animal Practice*, **20**, 1–11.
- Probst, C.W. & Webb, A.I. (1983) Postural influence on systemic blood pressure, gas exchange, and acid/base status in the term-pregnant bitch during general anesthesia. *American Journal of Veterinary Research*, **44**, 1963–1965.

- Probst, C.W., Broadstone, R.V. & Evans, A.T. (1987) Postural influence on systemic blood pressure in large full-term pregnant bitches during general anesthesia. *Veterinary Surgery: The official journal of the American College of Veterinary Surgeons*, **16**, 471–473.
- Proctor-Brown, L.A., Cheong, S.H. & Diel de Amorim, M. (2019) Impact of decision to delivery time of fetal mortality in canine caesarean section in a referral population. *Veterinary Medicine and Science*, **5**, 336–344.
- Prymak, C., McKee, L.J., Goldschmidt, M.H. & Glickman, L.T. (1988) Epidemiologic, clinical, pathologic, and prognostic characteristics of splenic hemangiosarcoma and splenic hematoma in dogs: 217 cases (1985). *Journal of the American Veterinary Medical Association*, **193**, 706–712.
- Pukay, B. & Stevenson, D. (1983) Mammary hypertrophy in an ovariohysterectomized cat. *The Canadian Veterinary Journal*, **24**, 143.
- Pulley, L.T. (1979) Sertoli cell tumor. *The Veterinary Clinics of North America. Small Animal Practice*, **9**, 145–150.
- Quartuccio, M., Marino, G., Garufi, G., Cristarella, S. & Zanghi, A. (2012) Sertoli cell tumors associated with feminizing syndrome and spermatic cord torsion in two cryptorchid dogs. *Journal of Veterinary Science*, **13**, 207–209.
- Rafatmah, D., Mogheiseh, A. & Eshghi, D. (2019) Chemical sterilization with intratesticular administration of zinc gluconate in adult dogs: a preliminary report. *Basic and Clinical Andrology*, **29**, 1–9.
- Ragni, R.A. (2007) Urethral prolapse in three male Yorkshire terriers. *Journal of Small Animal Practice*, **48**, 180.
- Rand, J.S., Fleeman, L.M., Farrow, H.A., Appleton, D.J. & Lederer, R. (2004) Canine and feline diabetes mellitus: nature or nurture? *The Journal of Nutrition*, **134**, 2072S–2080S.
- Rao, M.S., Khandpur, R.S., Chakravarti, R.N., Bapna, B.C., Subramanian, T.R. & Vaidyanathan, S. (1980) Use of a portable battery-operated apparatus for occlusive intraluminal vas fulguration in dogs. *Indian Journal of Medical Research*, **72**, 665–669.
- Read, R.A. & Bryden, S. (1995) Urethral bleeding as a presenting sign of benign prostatic hyperplasia in the dog: a retrospective study (1979–1993). *Journal of the American Animal Hospital Association*, **31**, 261–267.
- Read, J.L., Dickman, C.R., Boardman, W.S. & Lepczyk, C.A. (2020) Reply to Wolf et al.: why trap-neuter-return (TNR) is not an ethical solution for stray cat management. *Animals*, **10**, 1525.
- Reece, J.F., Nimesh, M.K., Wyllie, R.E., Jones, A.K. & Dennison, A.W. (2012) Description and evaluation of a right flank, mini-laparotomy approach to canine ovariohysterectomy. *Veterinary Record*, **171**, 248.
- Reece, J.F., Chawla, S.K. & Hiby, A.R. (2013) Decline in human dog-bite cases during a street dog sterilisation programme in Jaipur, India. *The Veterinary Record*, **172**, 473.
- Reed, L.T., Balog, K.A., Boes, K.M., Messick, J.B. & Miller, M.A. (2010) Pathology in practice. Granulomatous pneumonia, prostatitis and uveitis with intralesional yeasts consistent with *Blastomyces*. *Journal of the American Veterinary Medical Association*, **236**, 411–413.
- Reed, L.T., Knapp, D.W. & Miller, M.A. (2013) Cutaneous metastasis of transitional cell carcinoma in 12 dogs. *Veterinary Pathology*, **50**, 676–681.
- Regier, P.J., Smeak, D.D., Coleman, K. & McGilvray, K.C. (2015) Comparison of volume, security, and biomechanical strength of square and Aberdeen termination knots tied with 4-0 polyglyconate and used for termination of intradermal closures in canine cadavers. *Journal of the American Veterinary Medical Association*, **247**, 260–266.
- Reichler, I.M. (2009) Gonadectomy in cats and dogs: a review of risks and benefits. *Reproduction in Domestic Animals*, **44**, 29–35.
- Reichler, I.M. (2010) Vor- und Nachteile der Kastration von Kätzinnen und Katern. *Schweizer Archiv für Tierheilkunde*, **152**, 273–278.
- Reichler, I.M. & Hubler, M. (2014) Urinary incontinence in the bitch: an update. *Reproduction in Domestic Animals*, **49**(Supplement 2), 75–80.
- Reichler, I.M., Hung, E., Jöchle, W., Piché, C.A., Roos, M., Hubler, M. et al. (2005) FSH and LH plasma levels in bitches with differences in risk for urinary incontinence. *Theriogenology*, **63**, 2164–2180.
- Reisner, I.R., Houpt, K.A. & Shofer, F.S. (2005) National survey of owner-directed aggression in English springer spaniels. *Journal of the American Veterinary Medical Association*, **227**, 1594–1603.
- Reiter, R.J. (1991) Neuroendocrine effects of light. *International Journal of Biometeorology*, **35**, 169–175.
- Remfry, J. (1978) Control of feral cat populations by long-term administration of megestrol acetate. *The Veterinary Record*, **103**, 403–404.
- Repasy, A.B., Selmic, L.E. & Kisseberth, W.C. (2022) Canine apocrine gland anal sac adenocarcinoma: a review. *Topics in Companion Animal Medicine*, **50**, 100682.
- Richards, H.G., McNeil, P.E., Thompson, H. & Reid, S.W. (2001) An epidemiological analysis of a canine-biopsies database compiled by a diagnostic histopathology service. *Preventive Veterinary Medicine*, **51**, 125–136.
- Richardson, E.F. & Mullen, H. (1993) Cryptorchidism in cats. *Compendium on Continuing Education for the Practicing Veterinarian*, **15**, 1342–1369.
- Rigdon-Brestle, K., Accornero, V.H., Amtower, M. & Slater, M.R. (2022) Retrospective review reveals few complications of ovarian pedicle tie in 15,927 cats undergoing ovariohysterectomy at a large HQHVSN clinic and training facility in the United States: 2017–2018. *Journal of the American Veterinary Medical Association*, **260**, S28–S35.
- van Rijssel, E.J., Brand, R., Admiraal, C., Smit, I. & Trimbois, J.B. (1989) Tissue reaction and surgical knots: the effect of suture size, knot configuration, and knot volume. *Obstetrics & Gynecology*, **74**, 64–68.
- Risso, A., Valiente, C., Corrada, Y., Romero, G.G., Blanco, P.G., de la Sota, P.E. et al. (2010) The GnRH antagonist acylene prevented ovulation, but did not affect ovarian follicular development or gestational corpora lutea in the domestic cat. *Theriogenology*, **73**, 984–987.
- Risso, A., Corrada, Y., Barbeito, C., Diaz, J.D. & Gobello, C. (2012) Long-term-release GnRH agonists postpone puberty in domestic cats. *Reproduction in Domestic Animals*, **47**, 936–938.
- Robbins, M.A. & Mullen, H.S. (1994) En bloc ovariohysterectomy as a treatment for dystocia in dogs and cats. *Veterinary Surgery*, **23**, 48–52.
- Roberts, W.W., Chan, D.Y., Fried, N.M., Wright, E.J., Nicol, T., Jarrett, T.W. et al. (2002a) High intensity focused ultrasound ablation of the vas deferens in a canine model. *The Journal of Urology*, **167**, 2613–2617.
- Roberts, W.W., Wright, E.J., Fried, N.M., Nicol, T., Jarrett, T.W., Kavoussi, L.R. et al. (2002b) High-intensity focused ultrasound ablation of the epididymis in a canine model: a potential alternative to vasectomy. *Journal of Endourology*, **16**, 621–625.
- Rodriguez, J.R., Davis, J., Hill, S., Wolf, P.J., Hawes, S.M. & Morris, K.N. (2022) Trends in intake and outcome data from US animal shelters from 2016 to 2020. *Frontiers in Veterinary Science*, **9**, 863990.
- Rohrbach, B.W., Legendre, A.M., Baldwin, C.A., Lein, D.H., Reed, W.M. & Wilson, R.B. (2001) Epidemiology of feline infectious peritonitis among cats examined at veterinary medical teaching hospitals. *Journal of the American Veterinary Medical Association*, **218**, 1111–1115.
- Romagnoli, S.E. (1991) Canine cryptorchidism. *Veterinary Clinics of North America: Small Animal Practice*, **21**, 533–544.
- Romagnoli, S. (2015) Progestins to control feline reproduction: historical abuse of high doses and potentially safe use of low doses. *Journal of Feline Medicine and Surgery*, **17**, 743–752.
- Romagnoli, S. & Ferre-Dolcet, L. (2022) Reversible control of reproduction in queens: mastering the use of reproductive drugs to manipulate cyclicity. *Journal of Feline Medicine and Surgery*, **24**, 853–870.
- Romagnoli, S. & Lopate, C. (2017) Reproductive endocrinology and breeding husbandry of the bitch. In: *Textbook of veterinary internal medicine*. St. Louis, MO: Elsevier Saunders, pp. 4459–4601.
- Romagnoli, S. & Schlafer, D.H. (2006) Disorders of sexual differentiation in puppies and kittens: a diagnostic and clinical approach. *Veterinary Clinics of North America: Small Animal Practice*, **36**, 573–606, vii.
- Romagnoli, S., Stelletta, C., Milani, C., Gelli, D., Falomo, M.E. & Mollo, A. (2009) Clinical use of deslorelin for the control of reproduction in the bitch. *Reproduction in Domestic Animals*, **44**, 36–39.
- Romagnoli, S., Siminica, A., Sontas, B., Milani, C., Mollo, A. & Stelletta, C. (2012) Semen quality and onset of sterility following administration of a 4.7-mg deslorelin implant in adult male dogs. *Reproduction in Domestic Animals*, **47**, 389–392.
- Romagnoli, S., Baldan, A., Righetti, C., Milani, C., Mollo, A. & Stelletta, C. (2017) Semen quality and interval to sterility in tom cats treated with a 9.4 mg deslorelin implant. *Journal of Feline Medicine and Surgery*, **19**, 194–199.
- Romagnoli, S., Baldan, A., Ferro, S., Righetti, C., Scenna, L., Gabai, G. et al. (2019) Length of efficacy and effect of implant location in adult tom cats treated with a 9.4 mg deslorelin subcutaneous implant. *Journal of Feline Medicine and Surgery*, **21**, 507–519.
- Romagnoli, S., Diana, A., Ferré-Dolcet, L., Fontaine, C. & Milani, C. (2023) Chronic use of deslorelin in dogs: six cases (2005–2022). *Animals*, **13**, 265.
- Root, M.V., Johnston, S.D., Johnston, G.R. & Olson, P.N. (1996) The effect of prepuberal and postpuberal gonadectomy on penile extrusion and urethral diameter in the domestic cat. *Veterinary Radiology & Ultrasound*, **37**, 363–366.
- Root, M.V., Johnston, S.D. & Olson, P.N. (1997) The effect of prepuberal and postpuberal gonadectomy on radial physeal closure in male and female domestic cats. *Veterinary Radiology & Ultrasound: The Official Journal of the American College of Veterinary Radiology and the International Veterinary Radiology Association*, **38**, 42–47.



- Root, A.L., Parkin, T.D., Hutchison, P., Warnes, C. & Yam, P.S. (2018) Canine pseudopregnancy: an evaluation of prevalence and current treatment protocols in the UK. *BMC Veterinary Research*, **14**, 170.
- Rowan, A. & Kartal, T. (2018) Dog population & dog sheltering trends in The United States of America. *Animals*, **8**, 68.
- Rowan, A.N. & Williams, J. (1987) The success of companion animal management programs: a review. *Anthrozoös*, **1**, 110–122.
- RSPCA. (2012) Early-age desexing of cats and dogs. Royal Society for the Prevention of Cruelty to Animals, pp. 1–19. Available from: <https://kb.rspca.org.au/wp-content/uploads/2019/01/Early-age-desexing-of-cats-and-dogs-%E2%80%93-RSPCA-Research-Report-Aug-2012.pdf> [Accessed 22nd July 2023].
- RSPCA. (2024) Preventing unwanted/unplanned pregnancies through desexing is an essential part of responsible companion animal ownership. Available from: [https://www.rspca.org.au/take-action/responsible-pet-ownership/desexing](https://www.rspca.org.au/take-action/responsible-pet-ownership/desexing#:~:text=%22Desexing%20your%20pet%20is%20part,a%20vet%20clinic%20near%20you) #: ~:text=%22Desexing%20your%20pet%20is%20part,a%20vet%20clinic%20near%20you [Accessed 11th February 2024].
- Ru, G., Terracini, B. & Glickman, L.T. (1998) Host related risk factors for canine osteosarcoma. *The Veterinary Journal*, **156**, 31–39.
- Rubin, L.D. (1977) A technique for vasectomy in dogs. *Veterinary Medicine Small Animal Clinician*, **72**, 579–581.
- Rubion, S., Desmoulins, P., Rivière-Godet, E., Kinziger, M., Salavert, F., Rutten, F. et al. (2006) Treatment with a subcutaneous GnRH agonist containing controlled release device reversibly prevents puberty in bitches. *Theriogenology*, **66**, 1651–1654.
- Ruetten, H., Wehber, M., Murphy, M., Cole, C., Sandhu, S., Oakes, S. et al. (2021) A retrospective review of canine benign prostatic hyperplasia with and without prostatitis. *Clinical Theriogenology*, **13**, 360–366.
- Saba, C.F. & Lawrence, J.A. (2020) Tumors of the female reproductive system. In: Vail, D.M., Thamm, D.H. & Liptak, J.M. (Eds.) *Withrow and MacEwen's small Animal clinical oncology*, 6th edition. Amsterdam: Elsevier Inc., pp. 597–603.
- Sackman, J.E. (2012) Surgical modalities: laser, radiofrequency, ultrasonic, and Electrosurgery. In: Tobias, K.M. & Johnston, S.A. (Eds.) *Veterinary surgery small animal*. St. Louis, MO: Elsevier, pp. 180–186.
- Salas, Y., Márquez, A., Diaz, D. & Romero, L. (2015) Epidemiological study of mammary tumors in female dogs diagnosed during the period 2002–2012: a growing animal health problem. *PLoS One*, **10**, e0127381.
- Salkin, M.S. (1978) Pyometra in a male pseudohermaphrodite dog. *Journal of the American Veterinary Medical Association*, **172**, 913.
- Sallander, M., Hedhammar, Å., Rundgren, M. & Lindberg, J.E. (2001) Demographic data of a population of insured Swedish dogs measured in a questionnaire study. *Acta Veterinaria Scandinavica*, **42**, 1–10.
- Salmeri, K.R., Bloomberg, M.S., Scruggs, S.L. & Shille, V. (1991a) Gonadectomy in immature dogs: effects on skeletal, physical, and behavioral development. *Journal of the American Veterinary Medical Association*, **198**, 1193–1203.
- Salmeri, K.R., Olson, P.N. & Bloomberg, M.S. (1991b) Elective gonadectomy in dogs: a review. *Journal of the American Veterinary Medical Association*, **198**, 1183–1192.
- Salt, C., Morris, P.J., Wilson, D., Lund, E.M. & German, A.J. (2019) Association between life span and body condition in neutered client-owned dogs. *Journal of Veterinary Internal Medicine*, **33**, 89–99.
- Sarrafzadeh-Rezaei, F., Saifzadeh, S., Mazaheri, R. & Behfar, M. (2008) First report of vaginal prolapse in a bitch treated with oestrogen. *Animal Reproduction Science*, **106**, 194–199.
- Sathya, S. & Linn, K. (2014) Regression of a vaginal leiomyoma after ovariectomy in a dog: a case report. *Journal of the American Animal Hospital Association*, **50**, 424–428.
- Scarlett, J.M., Donoghue, S., Saidla, J. & Wills, J. (1994) Overweight cats: prevalence and risk factors. *International Journal of Obesity*, **18**(Supplement 1), 22–28.
- Schäfer-Somi, S. (2017) Effect of melatonin on the reproductive cycle in female cats: a review of clinical experiences and previous studies. *Journal of Feline Medicine and Surgery*, **19**, 5–12.
- Schäfer-Somi, S. (2022) Diseases of the canine prostate gland. In: Eduardo Fonseca-Alves, C. (Ed.) *Recent advances in canine medicine*. London: InTechOpen Limited, pp. 1–35.
- Schäfer-Somi, S., Kaya, D., Gültiken, N. & Aslan, S. (2014) Suppression of fertility in pre-pubertal dogs and cats. *Reproduction in Domestic Animals*, **49**, 21–27.
- Schäfer-Somi, S., Kaya, D. & Aslan, S. (2022) Prepubertal use of long-term GnRH agonists in dogs: current knowledge and recommendations. *Animals*, **12**, 2267–2282.
- Schiff, J.D., Li, P.S., Schlegel, P.N. & Goldstein, M. (2003) Rapid disappearance of spermatozoa after vasal occlusion in the dog. *Journal of Andrology*, **24**, 361–363.
- Schindler, A., Campagnoli, C., Druckmann, R., Huber, J., Pasqualini, J.R., Schweppe, K.W. et al. (2003) Classification and pharmacology of progestins. *Maturitas*, **46**, S7–S16.
- Schlafer, D.H. & Gifford, A.T. (2008) Cystic endometrial hyperplasia, pseudo-placental endometrial hyperplasia, and other cystic conditions of the canine and feline uterus. *Theriogenology*, **70**, 349–358.
- Schlein, L.J. & Thamm, D.H. (2022) Review: NF-κB activation in canine cancer. *Veterinary Pathology*, **59**, 724–732.
- Schmidt, P.M., Swannack, T.M., Lopez, R.R. & Slater, M.R. (2009) Evaluation of euthanasia and trap-neuter-return (TNR) programs in managing free-roaming cat populations. *Wildlife Research*, **36**, 117–125.
- Schneider, R., Dorn, C.R. & Taylor, D.O.N. (1969) Factors influencing canine mammary cancer development and postsurgical survival. *Journal of the National Cancer Institute*, **43**, 1249–1261.
- Schrank, M. & Romagnoli, S. (2020) Prostatic neoplasia in the intact and castrated dog: how dangerous is castration? *Animals*, **10**, 85.
- Schultheiss, P.C. (2004) A retrospective study of visceral and nonvisceral hemangiosarcoma and hemangiomas in domestic animals. *Journal of Veterinary Diagnostic Investigation: Official Publication of the American Association of Veterinary Laboratory Diagnosticians, Inc.*, **16**, 522–526.
- Schultz, K.S., Waldron, D.R., Smith, M.M., Henderson, R.A. & Howe, L.M. (1996) Inadvertent prostatectomy as a complication of cryptorchidectomy in four dogs. *Journal of the American Animal Hospital Association*, **32**, 211–214.
- Schutte, A. (1967) Vaginal prolapse in the bitch. *Journal of the South African Veterinary Association*, **38**, 197–202.
- Selman, R.J., Wolfswinkel, J. & Mol, J.A. (1996) Binding specificity of medroxyprogesterone acetate and proligestone for the progesterone and glucocorticoid receptor in the dog. *Steroids*, **61**, 133–137.
- Serpell, J. (1996) *In the company of animals: a study of human-animal relationships*. Cambridge: Cambridge University Press (Canto).
- Sforna, M., Brachelente, C., Lepri, E. & Mechelli, L. (2003) Canine ovarian tumours: a retrospective study of 49 cases. *Veterinary Research Communications*, **27**, 359–361.
- Shidaifat, F., Daradka, M. & Al-Omari, R. (2004) Effect of androgen ablation on prostatic cell differentiation in dogs. *Endocrine Research*, **30**, 327–334.
- Shivley, J.M., Richardson, J.M., Woodruff, K.A., Brookshire, W.C., Meyer, R.E. & Smith, D.R. (2019) Sharp transection of the suspensory ligament as an alternative to digital strumming during canine ovariectomy. *Veterinary Surgery*, **48**, 216–221.
- Shoop, S.J., Marlow, S., Church, D.B., English, K., McGreevy, P.D., Stell, A.J. et al. (2015) Prevalence and risk factors for mast cell tumours in dogs in England. *Canine Genetics and Epidemiology*, **2**, 1.
- Sigurdardóttir, O.G., Kolbjørnsen, O. & Lutz, H. (2001) Orchitis in a cat associated with coronavirus infection. *Journal of Comparative Pathology*, **124**, 219–222.
- Silva, L.D., Oncin, K., Donnay, I. & Verstegen, J.P. (1993) Laparoscopic vasectomy in the male dog. *Journal of Reproduction and Fertility. Supplement*, **47**, 399–401.
- Silva, R.C., Paranzini, C.S., Franco, L.G., Miguel, M.R., Honsho, C.S. & Souza, F.F. (2018) Calcium chloride combined with dimethyl sulphoxide for the chemical sterilization of dogs. *Reproduction in Domestic Animals*, **53**, 1330–1338.
- Simpson, M., Albright, S., Wolfe, B., Searfoss, E., Street, K., Diehl, K. et al. (2019) Age at gonadectomy and risk of overweight/obesity and orthopedic injury in a cohort of Golden retrievers. *PLoS One*, **14**, e0209131.
- Singer, M.K., Lutz, K.M., Hartnack, S. & Reichler, I.M. (2021) Prevalence of incontinence and mammary tumors in early and late spayed female dogs - a retrospective, matched-pair cohort study. Master thesis, Small Animal Reproduction, Vetsuisse Faculty Zurich, Ch, 1–19.
- Sinibaldi, K.R. & Greene, R.W. (1973) Surgical correction of prolapse of the male urethra in three English bulldogs. *Journal of the American Veterinary Medical Association*, **9**, 450–453.
- Sirinarmutir, K., Johnston, S.D., Kustritz, M.V., Johnston, G.R., Sarkar, D.K. & Memon, M.A. (2001) Effects of finasteride on size of the prostate gland and semen quality in dogs with benign prostatic hypertrophy. *Journal of the American Veterinary Medical Association*, **218**, 1275–1280.
- Sirivaidyapong, S., Mehl, N. & Trigg, T. (2012) Delay of puberty and reproductive performance in male dogs following the implantation of 4.7 and 9.4 mg GnRH-agonist deslorelin at an early pre-pubertal age. *Reproduction in Domestic Animals*, **47**, 400–402.
- Sisk, C.L. & Zehr, J.L. (2005) Pubertal hormones organize the adolescent brain and behavior. *Frontiers in Neuroendocrinology*, **26**, 163–174.
- Skerritt, G. (1975) Oral progestagens and pyometra in the cat. *The Veterinary Record*, **96**, 573.
- Slatter, D.H. (2003) In: Slatter, D. (Ed.) *Textbook of small animal surgery*, 3rd edition. Philadelphia, PA: Saunders.

- Slauterbeck, J.R., Pankratz, K., Xu, K.T., Bozeman, S.C. & Hardy, D.M. (2004) Canine ovariohysterectomy and orchiectomy increases the prevalence of ACL injury. *Clinical Orthopaedics and Related Research*, **429**, 301–305.
- Slaviero, M., Almeida, B.A.d., da Silva, E.M.S., Konflanz, C., Zitelli, L.C., Siqueira, F.M. et al. (2023) *Streptococcus canis* prostatitis and endocarditis with thromboembolism in a dog with sertoli cell tumour in a cryptic testis and prostatic squamous metaplasia. *Veterinary Research Communications*, **47**, 1759–1766.
- Sloane, M.H.B., Tedeschi, P. & Morris, K.N. (2019) Trends in intake and outcome data for Colorado animal shelters and rescues from 2000 through 2015. *Journal of the American Veterinary Medical Association*, **254**, 363–372.
- Smeak, D.D. (2019) Keys to secure ligation of large pedicles; learn the rules. Toronto: World Small Animal Veterinary Congress.
- Smith, J. (2008) Canine prostatic disease: a review of anatomy, pathology, diagnosis, and treatment. *Theriogenology*, **70**, 375–383.
- Soderberg, S.F. (1986) Vaginal disorders. *Veterinary Clinics of North America: Small Animal Practice*, **16**, 543–559.
- Sojka, N.J. (1980) The male reproductive system. In: Morrow, D.W. (Ed.) *Current therapy in theriogenology*. Philadelphia, PA: WB Saunders, pp. 865–869.
- Sokolowski, J. & Geng, S. (1977) Biological evaluation of mibolerone in the female beagle. *American Journal of Veterinary Research*, **38**, 1371–1376.
- Sonnenschein, E.G., Glickman, L.T., Goldschmidt, M.H. & McKee, L.J. (1991) Body conformation, diet, and risk of breast cancer in pet dogs: a case-control study. *American Journal of Epidemiology*, **133**, 694–703.
- Sontas, B.H., Turna, Ö., Ucmak, M. & Ekici, H. (2008) What is your diagnosis? *Journal of Small Animal Practice*, **49**, 545–547.
- Sontas, H.B., Dokuzeylu, B., Turna, O. & Ekici, H. (2009) Estrogen-induced myelotoxicity in dogs: a review. *The Canadian Veterinary Journal*, **50**, 1054.
- Sontas, H.B., Ekici, H. & Romagnoli, S. (2010) Canine vaginal fold prolapse: a comprehensive literature review. *The European Journal of Companion Animal Practice (EJCAP)*, **20**, 127.
- Sorenmo, K. (2003) Canine mammary gland tumors. *Veterinary Clinics of North America: Small Animal Practice*, **33**, 573–596.
- Sorenmo, K.U., Goldschmidt, M., Shofer, F., Goldkamp, C. & Ferracone, J. (2003) Immunohistochemical characterization of canine prostatic carcinoma and correlation with castration status and castration time. *Veterinary and Comparative Oncology*, **1**, 48–56.
- Sorenmo, K.U., Durham, A.C., Radaelli, E., Kristiansen, V., Peña, L., Goldschmidt, M.H. et al. (2019) The estrogen effect; clinical and histopathological evidence of dichotomous influences in dogs with spontaneous mammary carcinomas. *PLoS One*, **14**, e0224504.
- Sorenmo, K.U., Kristiansen, V.M., Cofone, M.A., Shofer, F.S., Breen, A.M., Langeland, M. et al. (2009) Canine mammary gland tumours; a histological continuum from benign to malignant; clinical and histopathological evidence. *Veterinary and Comparative Oncology*, **7**, 162–172.
- Spain, C.V., Scarlett, J.M. & Houpt, K.A. (2004a) Long-term risks and benefits of early-age gonadectomy in dogs. *Journal of the American Veterinary Medical Association*, **224**, 380–387.
- Spain, C.V., Scarlett, J.M. & Houpt, K.A. (2004b) Long-term risks and benefits of early-age gonadectomy in cats. *Journal of the American Veterinary Medical Association*, **224**, 372–379.
- Spangler, W.L. & Culbertson, M.R. (1992) Prevalence, type, and importance of splenic diseases in dogs: 1,480 cases (1985–1989). *Journal of the American Veterinary Medical Association*, **200**, 829–834.
- Srebrnik, N. & Appleby, E.C. (1991) Breed prevalence and sites of haemangioma and haemangiosarcoma in dogs. *Veterinary Record*, **129**, 408–409.
- Srivastava, N., Santhanam, R., Sheela, P., Mukund, S., Thakral, S.S., Malik, B.S. et al. (2002) Evaluation of the immunocontraceptive potential of *Escherichia coli*-expressed recombinant dog ZP2 and ZP3 in a homologous animal model. *Reproduction*, **123**, 847–857.
- Staples, J.E., Gasiewicz, T.A., Fiore, N.C., Lubahn, D.B., Korach, K.S. & Silverstone, A.E. (1999) Estrogen receptor alpha is necessary in thymic development and estradiol-induced thymic alterations. *Journal of Immunology*, **163**, 4168–4174.
- Starling, M.J., Branson, N., Thomson, P.C. & McGreevy, P.D. (2013) Age, sex and reproductive status affect boldness in dogs. *The Veterinary Journal*, **197**, 868–872.
- Stavisky, J., Brennan, M.L., Downes, M. & Dean, R. (2012) Demographics and economic burden of un-owned cats and dogs in the UK: results of a 2010 census. *BMC Veterinary Research*, **8**, 1–10.
- Steagall, P.V.M., Benito, J., Monteiro, B., Lascelles, D., Kronen, P.W., Murrell, J.C. et al. (2020) Intraperitoneal and incisional analgesia in small animals: simple, cost-effective techniques. *Journal of Small Animal Practice*, **61**, 19–23.
- Stempel, S., Körber, H., Reifarth, L., Schuler, G. & Goericke-Pesch, S. (2022a) What happens in male dogs after treatment with a 4.7 mg deslorelin implant? I. Flare up and downregulation. *Animals*, **12**, 2379. Available from: <https://doi.org/10.3390/ani12182379>
- Stempel, S., Körber, H., Reifarth, L., Schuler, G. & Goericke-Pesch, S. (2022b) What happens in male dogs after treatment with a 4.7 mg deslorelin implant? II. Recovery of testicular function after implant removal. *Animals*, **12**, 2545. Available from: <https://doi.org/10.3390/ani12192545>
- Sterman, A.A., Mankin, K.T. & Barton, C.L. (2019) Stump pyometra secondary to human topical estrogen hormone exposure in a spayed female Chihuahua. *Journal of the American Animal Hospital Association*, **55**, e55604.
- Stöcklin-Gautschi, N., Hässig, M., Reichler, I., Hubler, M. & Arnold, S. (2001) The relationship of urinary incontinence to early spaying in bitches. *Journal of Reproduction and Fertility. Supplement*, **57**, 233–236.
- Stornelli, M., Reyna, J., Stornelli, M., Favre, R.N., Savignone, C.A., Tittarelli, C.M. et al. (2009) Seasonal changes in testicular cell morphology in domestic male cats (*Felis catus*). *Reproduction in Domestic Animals*, **44**, 287–290.
- Strauss, A.C. & Dean, M.J. (1975) Neoplasms of the canine urinary bladder. *Journal of the American Veterinary Medical Association*, **166**, 1161–1163.
- Strakova, A. & Murchison, E.P. (2014) The changing global distribution and prevalence of canine transmissible venereal tumour. *BMC Veterinary Research*, **10**, 168.
- Strakova, A. & Murchison, E.P. (2015) The cancer which survived: insights from the genome of an 11000 year-old cancer. *Current Opinion in Genetics & Development*, **30**, 49–55.
- Stubbs, W.P., Bloomberg, M.S., Scruggs, S.L., Shille, V.M. & Lane, T.J. (1996) Effects of prepubertal gonadectomy on physical and behavioral development in cats. *Journal of the American Veterinary Medical Association*, **209**, 1864–1871.
- Su, L., Townsend, K.L., Au, J. & Wittum, T.E. (2015) Comparison of tibial plateau angles in small and large breed dogs. *The Canadian Veterinary Journal*, **56**, 610–614.
- Sumner, S.M., Grimes, J.A., Wallace, M.L. & Schmiedt, C.W. (2018) Os clitoris in dogs: 17 cases (2009–2017). *The Canadian Veterinary Journal*, **59**, 606–610.
- Sundburg, C.R., Belanger, J.M., Bannasch, D.L., Famula, T.R. & Oberbauer, A.M. (2016) Gonadectomy effects on the risk of immune disorders in the dog: a retrospective study. *BMC Veterinary Research*, **12**, 278.
- Sung, M., Armour, A. & Wright, P. (2006) The influence of exogenous progestin on the occurrence of proestrous or estrous signs, plasma concentrations of luteinizing hormone and estradiol in deslorelin (GnRH agonist) treated anestrous bitches. *Theriogenology*, **66**, 1513–1517.
- Swaffield, M.J., Molloy, S.L. & Lipscomb, V.J. (2019) Prospective comparison of perioperative wound and pain score parameters in cats undergoing flank vs midline ovariectomy. *Journal of Feline Medicine and Surgery*, **22**, 168–177.
- Switonski, M. (2014) Dog as a model in studies on human hereditary diseases and their gene therapy. *Reproductive Biology*, **14**, 44–50.
- Szczerbal, I., Nizanski, W., Dzimira, S., Nowacka-Woszek, J., Stachecka, J., Biezynski, J. et al. (2021) Chromosome abnormalities in dogs with disorders of sex development (DSD). *Animal Reproduction Science*, **230**, 106771.
- Tal, S. & Grinberg, N. (2013) Pyometra in a bitch following placement of a deslorelin implant. *Israel Journal of Veterinary Medicine*, **68**, 128–131.
- Tarvin, G., Patnaik, A. & Greene, R. (1978) Primary urethral tumors in dogs. *Journal of the American Veterinary Medical Association*, **172**, 931–933.
- Tavares, I.T., Barreno, R.R., Sales-Luis, J.P., Vaudano, C.G. & Jaber, J.R. (2021) Laparoscopic castration using bipolar forceps vs. orchiectomy in dogs: a comparison of two techniques. *Animals*, **11**, 3041.
- Taylor, G.N., Shabestari, L., Williams, J., Mays, C.W., Angus, W. & McFarland, S. (1976) Mammary neoplasia in a closed beagle colony. *Cancer Research*, **36**, 2740–2743.
- Teale, M. (1972) Pyometritis in spayed cats. *The Veterinary Record*, **91**, 129.
- Teske, E., Naan, E.C., Van Dijk, E., Van Garderen, E. & Schalken, J.A. (2002) Canine prostate carcinoma: epidemiological evidence of an increased risk in castrated dogs. *Molecular and Cellular Endocrinology*, **197**, 251–255.
- Thacher, C. & Bradley, R.L. (1983) Vulvar and vaginal tumors in the dog: a retrospective study. *Journal of the American Veterinary Medical Association*, **183**, 690–692.
- Theise, B. (2016) Cystic endometrial hyperplasia and leiomyoma following perennal treatment of a bitch with deslorelin implant. *Kleintierpraxis*, **61**, 614–621.
- Thompson, A.L., Scott-Moncrieff, J.C. & Anderson, J.D. (2007) Comparison of classic hypoadrenocorticism with glucocorticoid-deficient hypoadrenocorticism in dogs: 46 cases (1985–2005). *Journal of the American Veterinary Medical Association*, **230**, 1190–1194.
- Thornton, D. & Kear, M. (1967) Uterine cystic hyperplasia in a Siamese cat following treatment with medroxyprogesterone. *The Veterinary Record*, **80**, 380–381.
- Thrusfield, M.V., Holt, P.E. & Muirhead, R.H. (1998) Acquired urinary incontinence in bitches: its incidence and relationship to neutering practices. *Journal of Small Animal Practice*, **39**, 559–566.
- Thulke, H. & Eisinger, D. (2008) The strength of 70%: revision of a standard threshold of rabies control. *Developments in Biologicals*, **131**, 291–298.

- Timmermans-Sprang, E.P.M., Gracanic, A. & Mol, J.A. (2017) Molecular signaling of progesterone, growth hormone, Wnt, and HER in mammary glands of dogs, rodents, and humans: new treatment target identification. *Frontiers in Veterinary Science*, **4**, 53.
- Torres de la Riva, G., Hart, B.L., Farver, T.B., Oberbauer, A.M., McV Messam, L.L., Willits, N. et al. (2013) Neutering dogs: effects on joint disorders and cancers in Golden retrievers. *PLoS One*, **8**, e55937.
- Toydemir, T., Kılıçarslan, M. & Olgaç, V. (2012) Effects of the GnRH analogue deslorelin implants on reproduction in female domestic cats. *Theriogenology*, **77**, 662–674.
- Travis, B.M., Hayes, G.M., Vissio, K., Harvey, H.J., Flanders, J.A. & Sumner, J.P. (2018) A quilting subcutaneous suture pattern to reduce seroma formation and pain 24 hours after midline celiotomy in dogs: a randomized controlled trial. *Veterinary Surgery*, **47**, 204–211.
- Trejevo, R., Yang, M. & Lund, E.M. (2011) Epidemiology of surgical castration of dogs and cats in the United States. *Journal of the American Veterinary Medical Association*, **238**, 898–904.
- Trigg, T., Wright, P., Armour, A., Williamson, P.E., Junaidi, A., Martin, G.B. et al. (2001) Use of a GnRH analogue implant to produce reversible long-term suppression of reproductive function in male and female domestic dogs. *Journal of Reproduction and Fertility. Supplement*, **57**, 255–261.
- Trigg, T.E., Doyle, A.G., Walsh, J.D. & Swangchan-uthai, T. (2006) A review of advances in the use of the GnRH agonist deslorelin in control of reproduction. *Theriogenology*, **66**, 1507–1512.
- Troisi, A., Orlandi, R., Vallesi, E., Pastore, S., Sforza, M., Quartuccio, M. et al. (2023) Clinical and ultrasonographic findings of ovarian tumours in bitches: a retrospective study. *Theriogenology*, **210**, 227–233.
- Tsutsui, T., Onodera, F., Oba, H., Mizutani, T. & Hori, T. (2009) Plasma hormone levels and semen quality in male cats during non-breeding and breeding seasons. *Reproduction in Domestic Animals*, **44**, 291–293.
- Tucker, A.R. & Smith, J.R. (2008) Prostatic squamous metaplasia in a cat with interstitial cell neoplasia in a retained testis. *Veterinary Pathology*, **45**, 905–909.
- Tuxhorn, J.A., Ayala, G.E., Smith, M.J., Smith, V.C., Dang, T.D. & Rowley, D.R. (2002) Reactive stroma in human prostate cancer: induction of myofibroblast phenotype and extracellular matrix remodeling. *Clinical Cancer Research: An Official Journal of the American Association for Cancer Research*, **8**, 2912–2923.
- Uçmak, M., Yılmaz, Ö.T., Gündüz, M.C., Uçmak, Z.G., Duzgun, O., Eskiurt, N. et al. (2015) Osteoporotic risk and physeal closure in prepubertal ovariohysterectomized cats. *Animal Reproduction Science*, **161**, 146–151.
- Urfer, S.R. & Kaerberlein, M. (2019) Desexing dogs: a review of the current literature. *Animals*, **9**, 1086.
- Urfer, S.R., Wang, M., Yang, M., Lund, E.M. & Lefebvre, S.L. (2019) Risk factors associated with lifespan in pet dogs evaluated in primary care veterinary hospitals. *Journal of the American Animal Hospital Association*, **55**, 130–137.
- Valdez, V. (2022) High volume spay and neuter. Philadelphia, PA: Elsevier, p. 140.
- Valiente, C., Corrada, Y., De La Sota, P.E., Blanco, P.G., Arias, D. & Gobello, C. (2009a) Comparison of two doses of the GnRH antagonist, acylene, for pregnancy termination in bitches. *Reproduction in Domestic Animals*, **44**, 156–159.
- Valiente, C., Diaz, J., Rosa, D., Mattioli, G., Romero, G.G. & Gobello, C. (2009b) Effect of a GnRH antagonist on GnRH agonist-implanted anestrous bitches. *Theriogenology*, **72**, 926–929.
- Van den Broek, A. & O'Farrell, V. (1994) Suppression of adrenocortical function in dogs receiving therapeutic doses of megestrol acetate. *Journal of Small Animal Practice*, **35**, 285–288.
- Van Goethem, B.E., Rosenfeldt, K.W. & Kirpensteijn, J. (2003) Monopolar versus bipolar electrocoagulation in canine laparoscopic ovariectomy: a nonrandomized, prospective, clinical trial. *Veterinary Surgery*, **32**, 464–470.
- Van Goethem, B., Schaefer-Okkens, A.C. & Kirpensteijn, J. (2006) Making a rational choice between ovariectomy and ovariohysterectomy in the dog: a discussion of the benefits of either technique. *Veterinary Surgery*, **35**, 136–143.
- Vanderstichel, R., Forzán, M., Pérez, G., Serpell, J.A. & Garde, E. (2015) Changes in blood testosterone concentrations after surgical and chemical sterilization of male free-roaming dogs in southern Chile. *Theriogenology*, **83**, 1021–1027.
- Vannucchi, C.I., Angrimani, D.R., Eyherabide, A.R., Mazzei, C.P., Lucio, C.F., Maiorka, P.C. et al. (2015) Effects of intratesticular administration of zinc gluconate and dimethyl sulfoxide on clinical, endocrinological, and reproductive parameters in dogs. *Theriogenology*, **84**, 1103–1110.
- Vansandt, L., Kutzler, M., Fischer, A., Morris, K.N. & Swanson, W.F. (2017) Safety and effectiveness of a single and repeat intramuscular injection of a GnRH vaccine (GonaCon™) in adult female domestic cats. *Reproduction in Domestic Animals*, **52**, 348–353.
- Vansandt, L.M., Meinsohn, M.-C., Godin, P., Nagyker, N., Sicher, N., Kano, M. et al. (2023) Durable contraception in the female domestic cat using viral-vectored delivery of a feline anti-Müllerian hormone transgene. *Nature Communications*, **14**, 3140.
- Vargas-Pino, F., Gutiérrez-Cedillo, V., Canales-Vargas, E.J., Gress-Ortega, L.R., Miller, L.A., Rupprecht, C.E. et al. (2013) Concomitant administration of GonaCon™ and rabies vaccine in female dogs (*Canis familiaris*) in Mexico. *Vaccine*, **31**, 4442–4447.
- Varney, D., O'Neill, D., O'Neill, M., Church, D., Stell, A., Beck, S. et al. (2023) Epidemiology of mammary tumours in bitches under veterinary care in the UK in 2016. *The Veterinary Record*, **193**, e3054.
- Vasseur, P.B., Levy, J., Dowd, E. & Eliot, J. (1988) Surgical wound infection rates in dogs and cats. Data from a teaching hospital. *Veterinary Surgery*, **17**, 60–64.
- Vaughan, E.D., Jr. & Gillenwater, J.Y. (1971) Recovery following complete chronic unilateral ureteral occlusion: functional, radiographic and pathologic alterations. *Journal of Urology*, **106**, 27–35.
- Vaughan, E.D., Jr., Sweet, R.E. & Gillenwater, J.Y. (1973) Unilateral ureteral occlusion: pattern of nephron repair and compensatory response. *Journal of Urology*, **109**, 979–982.
- Veiga, A.P.M., Price, C.A., de Oliveira, S.T., Dos Santos, A.P., Campos, R., Barbosa, P.R. et al. (2008) Association of canine obesity with reduced serum levels of C-reactive protein. *Journal of Veterinary Diagnostic Investigation: Official Publication of the American Association of Veterinary Laboratory Diagnosticians, Inc.*, **20**, 224–228.
- Veronesi, M.C., Riccardi, E., Rota, A. & Grieco, V. (2009) Characteristics of cryptic/ectopic and contralateral scrotal testes in dogs between 1 and 2 years of age. *Theriogenology*, **72**, 969–977.
- Verrinder, J. (2011) Report on the availability of early age desexing in Gold Coast City in 2010. Available from: <https://www.g2z.org.au/pdf/WhatproportionofvetclinicsofferearlyagedesexingResearchinonlargecity.pdf> [Accessed 22nd July 2023].
- Vet Record. (2023) Neutering is no longer the hallmark of responsible pet ownership. *Veterinary Record*, **193**, 3–4.
- Vickery, B.H. (1985) Comparisons of the potential utility of LHRH agonists and antagonists for fertility control. *Journal of Steroid Biochemistry*, **23**, 779–791.
- Villamil, J.A., Henry, C.J., Hahn, A.W., Bryan, J.N., Tyler, J.W. & Caldwell, C.W. (2009) Hormonal and sex impact on the epidemiology of canine lymphoma. *Journal of Cancer Epidemiology*, **2009**, 1–7.
- Villamil, J.A., Henry, C.J., Bryan, J.N., Ellersieck, M., Schultz, L., Tyler, J.W. et al. (2011) Identification of the most common cutaneous neoplasms in dogs and evaluation of breed and age distributions for selected neoplasms. *Journal of the American Veterinary Medical Association*, **239**, 960–965.
- Voith, V.L. & Borchelt, P.L. (1982) Diagnosis and treatment of dominance aggression in dogs. *Veterinary Clinics of North America: Small Animal Practice*, **12**, 655–663.
- Volpe, P., Izzo, B., Russo, M. & Iannetti, L. (2001) Intrauterine device for contraception in dogs. *The Veterinary Record*, **149**, 77–79.
- Walker, D. (1968) Mammary adenomas in a male dog – probable oestrogenic neoplasms. *Journal of Small Animal Practice*, **9**, 15–20.
- Walker, C. (1975) Oral progestagens in cats. *The Veterinary Record*, **96**, 458.
- Wallace, M.S. (1991) The ovarian remnant syndrome in the bitch and queen. *Veterinary Clinics of North America, Small Animal Practice*, **21**, 501–507.
- Wang, M. (2002) Neutersol: intratesticular injection induces sterility in dogs. *International Symposium on non-surgical methods for pet population control*. pp. 62–65.
- Ware, W.A. & Hopper, D.L. (1999) Cardiac tumors in dogs: 1982–1995. *Journal of Veterinary Internal Medicine*, **13**, 95–103.
- Warland, J., Constantino-Casas, F. & Dobson, J. (2011) Hyperoestrogenism and mammary adenosis associated with a metastatic Sertoli cell tumour in a male Pekingese dog. *Veterinary Quarterly*, **31**, 211–214.
- Waters, D.J., Hayden, D.W. & Walter, P.A. (1989) Intracranial lesions in dogs with hemangiosarcoma. *Journal of Veterinary Internal Medicine*, **3**, 222–230.
- Waters, D.J., Kengeri, S.S., Clever, B., Booth, J.A., Maras, A.H., Schlittler, D.L. et al. (2009) Exploring mechanisms of sex differences in longevity: lifetime ovary exposure and exceptional longevity in dogs. *Aging Cell*, **8**, 752–755.
- Waters, D.J., Kengeri, S.S., Maras, A.H., Suckow, C.L. & Chiang, E.C. (2017) Life course analysis of the impact of mammary cancer and pyometra on age-anchored life expectancy in female Rottweilers: implications for envisioning ovary conservation as a strategy to promote healthy longevity in pet dogs. *Veterinary Journal (London, England: 1997)*, **224**, 25–37.
- Watson, A., Church, D., Emslie, D. & Middleton, D.J. (1989) Comparative effects of proligestone and megestrol acetate on basal plasma glucose concentrations and cortisol responses to exogenous adrenocorticotrophic hormone in cats. *Research in Veterinary Science*, **47**, 374–376.



- Watts, J. (2018) The uses of bipolar electrosurgical forceps for haemostasis in open surgical ovarioectomy of bitches and queens and castration of dogs. *Journal of Small Animal Practice*, **59**, 465–473.
- Wayne, K. (2017) Does preventing reproduction make for bad care? In: Overall, C. (Ed.) *Pets and people: the ethics of our relationships with companion animals*. Oxford: Oxford Scholarship One, pp. 127–142.
- Weaver, A.D. (1981) Fifteen cases of prostatic carcinoma in the dog. *Veterinary Record*, **109**, 71–75.
- Wehrend, A., Hospes, R. & Gruber, A.D. (2001) Treatment of feline mammary fibroadenomatous hyperplasia with a progesterone-antagonist. *Veterinary Record*, **148**, 346–347.
- Weikel, J.H. & Nelson, L.W. (1977) Problems in evaluating chronic toxicity of contraceptive steroids in dogs. *Journal of Toxicology and Environmental Health*, **3**, 167–177.
- Weikel, J., Nelson, L. & Reno, F. (1975) A four-year evaluation of the chronic toxicity of megestrol acetate in dogs. *Toxicology and Applied Pharmacology*, **33**, 414–426.
- Weinkle, T.K., Center, S.A., Randolph, J.F., Warner, K.L., Barr, S.C. & Erb, H.N. (2005) Evaluation of prognostic factors, survival rates, and treatment protocols for immune-mediated hemolytic anemia in dogs: 151 cases (1993–2002). *Journal of the American Veterinary Medical Association*, **226**, 1869–1880.
- Weiss, E., Patronek, G., Slater, M., Garrison, L. & Medicus, K. (2013) Community partnering as a tool for improving live release rate in animal shelters in the United States. *Journal of Applied Animal Welfare Science*, **16**, 221–238.
- Weissman, A., Jiménez, D., Torres, B., Cornell, K. & Holmes, S.P. (2013) Canine vaginal leiomyoma diagnosed by CT vaginourethrography. *Journal of the American Animal Hospital Association*, **49**, 394–397.
- Wejdmark, A.-K., Bonnett, B., Hedhammar, A. & Fall, T. (2011) Lifestyle risk factors for progesterone-related diabetes mellitus in elkhounds – a case-control study. *Journal of Small Animal Practice*, **52**, 240–245.
- Welborn, L.V., Devries, J.B., Ford, R., Franklin, R.T., Hurley, K.F., McClure, K.D. et al. (2011) The 2011 AAHA canine vaccination guidelines. *Journal of the American Animal Hospital Association*, **47**, 1–42.
- Weller, R.E., Wold, A.M. & Dyjido, A. (1979) Transitional cell carcinoma of the bladder associated with cyclophosphamide therapy in a dog. *Journal of the American Veterinary Medical Association*, **5**, 733–736.
- Wenzlow, N., Tivers, M.S., Selmic, L.E., Scurrall, E.J., Baines, S.J. & Smith, K.C. (2009) Haemangiosarcoma in the uterine remnant of a spayed female dog. *Journal of Small Animal Practice*, **50**, 488–491.
- Werhahn Beining, F., Urhausen, C., Wolf, K., Schmicke, M., Rohn, K., Schuler, G. et al. (2020) Rhodesian ridgebacks have an increased risk to develop benign prostatic hyperplasia. *Reproduction in Domestic Animals*, **55**, 283–292.
- Werner, R.E., Straughan, A.J. & Vezin, D. (1992) Nylon cable band reactions in ovariohysterectomized bitches. *Journal of the American Veterinary Medical Association*, **200**, 64–66.
- Wernham, B.G.J. & Jerram, R.M. (2006) Male pseudohermaphroditism in a Labrador retriever, and a review of mammalian sexual differentiation. *New Zealand Veterinary Journal*, **54**, 248–252.
- White, C.R., Hohenhaus, A.E., Kelsey, J. & Procter-Gray, E. (2011) Cutaneous MCTs: associations with spay/neuter status, breed, body size, and phylogenetic cluster. *Journal of the American Animal Hospital Association*, **47**, 210–216.
- Whitehair, J., Vasseur, P. & Willits, N. (1993) Epidemiology of cranial cruciate ligament rupture in dogs. *Journal of the American Veterinary Medical Association*, **203**, 1016–1019.
- Wiebe, V.J. & Howard, J.P. (2009) Pharmacologic advances in canine and feline reproduction. *Topics in Companion Animal Medicine*, **24**, 71–99.
- Wildt, D.E., Kinney, G.M. & Seager, S.W.J. (1977) Reproduction control in the dog and cat: an examination and evaluation of current and proposed methods [contraception]. *Journal of the American Animal Hospital Association*, **13**, 223–231.
- Wildt, D., Chan, S., Seager, S. & Chakraborty, P.K. (1981) Ovarian activity, circulating hormones, and sexual behavior in the cat. I. Relationships during the coitus-induced luteal phase and the estrous period without mating. *Biology of Reproduction*, **25**, 15–28.
- Wilkins, D. (1972) Pyometritis in a spayed cat. *The Veterinary Record*, **91**, 24.
- Willeberg, P. & Priester, W.A. (1976) Feline urological syndrome: associations with some time, space, and individual patient factors. *American Journal of Veterinary Research*, **37**, 975–978.
- Williams, K., Parker, S. & MacDonald-Dickinson, V. (2023) Risk factors for appendicular osteosarcoma occurrence in large and giant breed dogs in western Canada. *The Canadian Veterinary Journal*, **64**, 167–173.
- Williams, L.E., Gliatto, J.M., Dodge, R.K., Johnson, J.L., Gamblin, R.M., Thamm, D.H. et al. (2003) Carcinoma of the apocrine glands of the anal sac in dogs: 113 cases (1985–1995). *Journal of the American Veterinary Medical Association*, **223**, 825–831.
- Wilson, C.R. (2013) Feline gangrenous mastitis. *The Canadian Veterinary Journal*, **54**, 292–294.
- Wilson, G.P. & Hayes, H.M., Jr. (1979) Castration for treatment of perianal gland neoplasms in the dog. *Journal of the American Veterinary Medical Association*, **174**, 1301–1303.
- Witsberger, T.H., Villamil, J.A., Schultz, L.G., Hahn, A.W. & Cook, J.L. (2008) Prevalence of and risk factors for hip dysplasia and cranial cruciate ligament deficiency in dogs. *Journal of the American Veterinary Medical Association*, **232**, 1818–1824.
- Wolf, K., Kayacelebi, H., Urhausen, C., Piechotta, M., Mischke, R., Kramer, S. et al. (2012) Testicular steroids, prolactin, relaxin and prostate gland markers in peripheral blood and seminal plasma of normal dogs and dogs with prostatic hyperplasia. *Reproduction in Domestic Animals*, **47**(Supplement 6), 243–246.
- Wolf, P.J., Rand, J., Swarbrick, H., Spehar, D.D. & Norris, J. (2019) Reply to Crawford et al.: why trap-neuter-return (TNR) is an ethical solution for stray cat management. *Animals*, **9**, 689.
- Woodruff, K., Rigdon-Brestle, K., Bushby, P.A. & Wills, R. (2015) Scrotal castration versus prescrotal castration in dogs. *Veterinary Medicine and Science*, **110**, 131–135.
- Wright, C. & Nesselrode, M.S. (1987) Classification of behavior problems in dogs: Distributions of age, breed, sex and reproductive status. *Applied Animal Behaviour Science*, **19**, 169–178.
- Wright, J.C. (1991) Canine aggression toward people: bite scenarios and prevention. *Veterinary Clinics of North America: Small Animal Practice*, **21**, 299–314.
- Wright, P., Verstegen, J., Onclin, K., Jöchle, W., Armour, A.F., Martin, G.B. et al. (2001) Suppression of the oestrous responses of bitches to the GnRH analogue deslorelin by progesterin. *Journal of Reproduction and Fertility. Supplement*, **57**, 263–268.
- Yadunath, R. (2021) Saving Animal lives with data. Towards Data Science. Available from: <https://towardsdatascience.com/saving-animal-lives-with-data-d815c6e854eb> [Accessed 12th June 2023].
- Yam, P.S., Butowski, C.F., Chitty, J.L., Naughton, G., Wiseman-Orr, M.L., Parkin, T. et al. (2016) Impact of canine overweight and obesity on health-related quality of life. *Preventive Veterinary Medicine*, **127**, 64–69.
- Yordy, J., Kraus, C., Hayward, J.J., White, M.E., Shannon, L.M., Creevy, K.E. et al. (2020) Body size, inbreeding, and lifespan in domestic dogs. *Conservation Genetics*, **21**, 137–148.
- Zambelli, D., Bini, C., Küster, D.G., Molari, V. & Cunto, M. (2015) First deliveries after estrus induction using deslorelin and endoscopic transcervical insemination in the queen. *Theriogenology*, **84**, 773–778.
- Zanowski, G.N. (2012) A fresh look at spay/neuter legislation: the journey to a middle ground. *Journal of Public Health Management and Practice*, **18**, E24–E33.
- Zatloukal, J., Lorenzová, J., Tichý, F., Nečas, A., Kecová, H. & Kohout, P. (2005) Breed and age as risk factors for canine mammary tumours. *Acta Veterinaria Brno*, **74**, 103–109.
- Zink, M.C., Farhoo, P., Elser, S.E., Ruffini, L.D., Gibbons, T.A. & Rieger, R.H. (2014) Evaluation of the risk and age of onset of cancer and behavioral disorders in gonadectomized Vizslas. *Journal of the American Veterinary Medical Association*, **244**, 309–319.
- Zink, C., Delgado, M.M. & Stella, J.L. (2023) Vasectomy and ovary-sparing spay in dogs: comparison of health and behavior outcomes with gonadectomized and sexually intact dogs. *Journal of the American Veterinary Medical Association*, **1**, 1–9.
- Zlotnick, M., Corrigan, V., Griffin, E., Alayon, M. & Hungerford, L. (2019) Incidence of health and behavior problems in service dog candidates neutered at various ages. *Frontiers in Veterinary Science*, **6**, 334.
- Zwida, K.H. & Kutzler, M.A. (2019) Luteinizing hormone receptor is immunoexpressed within the canine thyroid. *Clinical Theriogenology*, **11**, 23–29.
- Zwida, K.H. & Kutzler, M.A. (2022) Canine splenic hemangiosarcoma cells express and activate luteinizing hormone receptors in vitro. *American Journal of Veterinary Research*, **83**, 1–5.